Settings

1 2 3 4 5 6 7 8 9 10 11 12 13 14 15 16 17 18 19 20 21 22 23 24 25 26 27 28

Item 1 of 38
Question Id: 1375

Mark | Previous | Next | Full Screen | Tutorial | Lab Values | Notes | Calculator | Reverse Color | Text Zoom | Settings

A 23-year-old woman participates in a research study evaluating the effect of monoclonal antibodies on viral infection. The patient has no past medical history and takes no medications. She has not been ill recently. During the study, a peripheral blood specimen is obtained. CD19 positive cells are isolated, purified, and exposed to monoclonal antibodies against cell surface complement receptor CD21. The cells are subsequently incubated along with several viruses being studied. Initial exposure to monoclonal antibodies against CD21 is most likely to prevent cell infection with which of the following viruses?

A. Adenovirus

B. Cytomegalovirus

C. Epstein-Barr virus

D. Human immunodeficiency virus

E. Parvovirus B19

Submit

Block Time Remaining: 00:00:11
TUTOR

4 | Feedback | Suspend | End Block

A 23-year-old woman participates in a research study evaluating the effect of monoclonal antibodies on viral infection. The patient has no past medical history and takes no medications. She has not been ill recently. During the study, a peripheral blood specimen is obtained. CD19 positive cells are isolated, purified, and exposed to monoclonal antibodies against cell surface complement receptor CD21. The cells are subsequently incubated along with several viruses being studied. Initial exposure to monoclonal antibodies against CD21 is most likely to prevent cell infection with which of the following viruses?

- A. Adenovirus (1%)
- B. Cytomegalovirus (4%)
- ✓ C. Epstein-Barr virus (84%)
- D. Human immunodeficiency virus (5%)
- E. Parvovirus B19 (4%)

Omitted
Correct answer
C

84%
Answered correctly

13 secs
Time Spent

05/20/2020
Last Updated

Explanation

The initial attachment of the virion envelope or capsid surface proteins to the complementary host cell surface receptors is essential to viral tropism for specific tissues and invasion of cells. Many viruses bind to normal host cell plasma membrane receptors to enter host cells.

Epstein-Barr virus (EBV) is a herpesvirus responsible for acute infectious mononucleosis, nasopharyngeal carcinoma, and certain lymphomas (eg, Burkitt lymphoma). More than 90% of the normal adult population is seropositive for EBV, which is primarily transmitted through contact with

The initial attachment of the virion envelope or capsid surface proteins to the complementary host cell surface receptors is essential to viral tropism for specific tissues and invasion of cells. Many viruses bind to normal host cell plasma membrane receptors to enter host cells.

Epstein-Barr virus (EBV) is a herpesvirus responsible for acute infectious mononucleosis, nasopharyngeal carcinoma, and certain lymphomas (eg, Burkitt lymphoma). More than 90% of the normal adult population is seropositive for EBV, which is primarily transmitted through contact with oropharyngeal secretions. The EBV envelope glycoprotein gp350 binds to **CD21** (also known as CR2), the cellular receptor for the C3d complement component. CD21 is normally present on the surface of **B cells** (CD19-positive cells) and nasopharyngeal epithelial cells. Therefore, exposure to a monoclonal anti-CD21 antibody could interfere with EBV attachment to B cells.

(Choice A) Adenovirus has hexon and penton capsomeres on its surface. Rodlike structures ("fibers") that project from the penton base capsomeres are responsible for mediating adsorption to host cells. The cell receptor for most adenovirus fibers is a transmembrane protein member of the immunoglobulin superfamily.

(Choice B) Like other herpesviruses, cytomegalovirus requires initial contact with glycosaminoglycan chains on host cell surface proteoglycans for entry into the host cell. It does not require contact with CD21.

(Choice D) HIV viruses attach to their major target host cells ($CD4^+$ T cells) primarily via the binding of viral envelope glycoprotein gp120 to the cellular CD4 transmembrane glycoprotein and the coreceptor (CCR5 or CXCR4). The HIV envelope then undergoes a conformational change that activates gp41 and initiates membrane fusion.

(Choice E) Parvovirus B19 is thought to attach to human erythroid cells via the blood group P antigen (globoside), which is expressed by mature erythrocytes, erythroid progenitors, megakaryocytes, placenta, and the fetal liver and heart. Immature cells of the erythroid family (eg, adult bone marrow, fetal liver) are most vulnerable to parvovirus B19 infection.

Educational objective:
The initial attachment of the virion envelope or capsid surface proteins to the complementary host cell surface receptors is essential to viral tropism for specific tissues and invasion of cells. Many viruses bind to normal host cell plasma membrane receptors to enter host cells. Known host cell receptor and virion/virion protein binding specificities include: CD4 with HIV gp120, CD21 with Epstein-Barr virus gp350, and erythrocyte P antigen with parvovirus B19.

oropharyngeal secretions. The EBV envelope glycoprotein gp350 binds to **CD21** (also known as CR2), the cellular receptor for the C3d complement component. CD21 is normally present on the surface of **B cells** (CD19-positive cells) and nasopharyngeal epithelial cells. Therefore, exposure to a monoclonal anti-CD21 antibody could interfere with EBV attachment to B cells.

(Choice A) Adenovirus has hexon and penton capsomeres on its surface. Rodlike structures ("fibers") that project from the penton base capsomeres are responsible for mediating adsorption to host cells. The cell receptor for most adenovirus fibers is a transmembrane protein member of the immunoglobulin superfamily.

(Choice B) Like other herpesviruses, cytomegalovirus requires initial contact with glycosaminoglycan chains on host cell surface proteoglycans for entry into the host cell. It does not require contact with CD21.

(Choice D) HIV viruses attach to their major target host cells ($CD4^+$ T cells) primarily via the binding of viral envelope glycoprotein gp120 to the cellular CD4 transmembrane glycoprotein and the coreceptor (CCR5 or CXCR4). The HIV envelope then undergoes a conformational change that activates gp41 and initiates membrane fusion.

(Choice E) Parvovirus B19 is thought to attach to human erythroid cells via the blood group P antigen (globoside), which is expressed by mature erythrocytes, erythroid progenitors, megakaryocytes, placenta, and the fetal liver and heart. Immature cells of the erythroid family (eg, adult bone marrow, fetal liver) are most vulnerable to parvovirus B19 infection.

Educational objective:
The initial attachment of the virion envelope or capsid surface proteins to the complementary host cell surface receptors is essential to viral tropism for specific tissues and invasion of cells. Many viruses bind to normal host cell plasma membrane receptors to enter host cells. Known host cell receptor and virion/virion protein binding specificities include: CD4 with HIV gp120, CD21 with Epstein-Barr virus gp350, and erythrocyte P antigen with parvovirus B19.

Microbiology	Hematology & Oncology	Epstein barr virus
Subject	System	Topic

Copyright © UWorld. All rights reserved.

Settings

1
2
3
4
5
6
7
8
9
10
11
12
13
14
15
16
17
18
19
20
21
22
23
24
25
26
27
28
29
30

Item 2 of 38
Question Id: 1373

Mark | Previous | Next | Full Screen | Tutorial | Lab Values | Notes | Calculator | Reverse Color | Text Zoom | Settings

A 23-year-old man has 2 days of fever, cough, sore throat, and runny nose. His temperature is 38 C (100.4 F). Lung sounds are clear to auscultation. A nasopharyngeal swab is obtained. Naked viral particles are seen, and purified RNA molecules are extracted from these particles. Once introduced into human cells, the purified RNA molecules induce viral protein synthesis and viral genome replication. Which of the following is the most likely cause of this patient's symptoms?

A. HIV

B. Influenza virus type A

C. Respiratory syncytial virus

D. Rhinovirus

E. Rotavirus

Submit

Block Time Remaining: 00:00:13
TUTOR

Feedback | Suspend | End Block

A 23-year-old man has 2 days of fever, cough, sore throat, and runny nose. His temperature is 38 C (100.4 F). Lung sounds are clear to auscultation. A nasopharyngeal swab is obtained. Naked viral particles are seen, and purified RNA molecules are extracted from these particles. Once introduced into human cells, the purified RNA molecules induce viral protein synthesis and viral genome replication. Which of the following is the most likely cause of this patient's symptoms?

A. HIV (5%)

B. Influenza virus type A (16%)

C. Respiratory syncytial virus (6%)

✓ D. Rhinovirus (68%)

E. Rotavirus (3%)

Omitted
Correct answer
D

68%
Answered correctly

02 secs
Time Spent

04/18/2020
Last Updated

Explanation

For an RNA molecule **purified** from a virus (ie, without viral capsid or envelope) to be infectious (ie, able to induce viral protein synthesis and genome replication in the host cell) on its own, it must act as mRNA capable of using the host's intracellular machinery for translation. In other words, the purified RNA molecule must be **single-stranded** (SS) and **positive (+) sense**, or SS(+). The question describes a naked (ie, nonenveloped) virus with SS(+) RNA. Of the viruses listed, only rhinovirus (a picornavirus) has these features. Generally, only RNA molecules purified from SS(+) viruses are infectious; purified SS negative (–) sense RNA molecules and double-stranded (ds) RNA molecules are not as they require additional enzymes.

Explanation

For an RNA molecule **purified** from a virus (ie, without viral capsid or envelope) to be infectious (ie, able to induce viral protein synthesis and genome replication in the host cell) on its own, it must act as mRNA capable of using the host's intracellular machinery for translation. In other words, the purified RNA molecule must be **single-stranded** (SS) and **positive (+) sense**, or SS(+). The question describes a naked (ie, nonenveloped) virus with SS(+) RNA. Of the viruses listed, only rhinovirus (a picornavirus) has these features. Generally, only RNA molecules purified from SS(+) viruses are infectious; purified SS negative (–) sense RNA molecules and double-stranded (ds) RNA molecules are not as they require additional enzymes.

(Choice A) HIV is a retrovirus that contains SS(+) RNA. However, viral infectivity requires the action of reverse transcriptase for integration into the host genome; purified RNA by itself cannot cause infection. In addition, HIV is enveloped, unlike the particles isolated from this patient.

(Choices B and C) Influenza A is an orthomyxovirus that contains SS(–) RNA; similarly, respiratory syncytial virus is a paramyxovirus that contains SS(–) RNA. For these viruses to replicate in a host cell, an RNA-dependent RNA polymerase must also gain entry into the host cell.

(Choice E) Rotavirus is a reovirus containing dsRNA. Its purified RNA is therefore incapable of inducing viral protein synthesis in a host cell on its own (ie, it is non-infectious). For this virus to replicate in a host cell, a specific viral RNA polymerase present in the intact virion must also gain entry into the host cell.

Educational objective:
For a purified RNA molecule to induce viral protein synthesis in a host cell, it must be able to act directly as mRNA using the host's intracellular machinery for translation. Therefore, in general, purified single-stranded positive-sense RNA can be infectious; single-stranded negative sense or double-stranded RNA is not.

Microbiology	Ear, Nose & Throat (ENT)	Upper respiratory tract infections
Subject	System	Topic

Copyright © UWorld. All rights reserved.

A 26-year-old man is being screened as a potential kidney donor for his mother, who has end-stage renal disease. The patient has no history of diabetes, hypertension, or kidney disease and is up to date with all recommended vaccinations. Physical examination is unremarkable. Blood type and crossmatch testing demonstrate biological compatibility. As part of the evaluation, screening for transmissible diseases is performed and is notable for the following results:

HIV-1 antibody	negative
Hepatitis B core antibody, IgM	negative
Hepatitis B core antibody, IgG	negative
Hepatitis B surface antigen	negative
Hepatitis B surface antibody	positive
Hepatitis C virus antibody	negative
Cytomegalovirus antibody, IgM	negative
Cytomegalovirus antibody, IgG	positive

Based on these data, the patient most likely has had which of the following conditions in the past?

A. Esophageal ulcer
B. Hepatitis
C. Mononucleosis-like illness
D. Retinitis
E. Vesicular skin rash

HIV-1 antibody	negative
Hepatitis B core antibody, IgM	negative
Hepatitis B core antibody, IgG	negative
Hepatitis B surface antigen	negative
Hepatitis B surface antibody	positive
Hepatitis C virus antibody	negative
Cytomegalovirus antibody, IgM	negative
Cytomegalovirus antibody, IgG	positive

Based on these data, the patient most likely has had which of the following conditions in the past?

- A. Esophageal ulcer
- B. Hepatitis
- C. Mononucleosis-like illness
- D. Retinitis
- E. Vesicular skin rash
- F. Viral pneumonia

Submit

1 2 3 4 5 6 7 8 9 10 11 12 13 14 15 16 17 18 19 20 21 22 23 24 25 26 27 28 29 30

HIV-1 antibody	negative
Hepatitis B core antibody, IgM	negative
Hepatitis B core antibody, IgG	negative
Hepatitis B surface antigen	negative
Hepatitis B surface antibody	positive
Hepatitis C virus antibody	negative
Cytomegalovirus antibody, IgM	negative
Cytomegalovirus antibody, IgG	positive

Based on these data, the patient most likely has had which of the following conditions in the past?

- A. Esophageal ulcer (1%)
- B. Hepatitis (6%)
- ✓ C. Mononucleosis-like illness (81%)
- D. Retinitis (7%)
- E. Vesicular skin rash (1%)
- F. Viral pneumonia (2%)

Omitted
Correct answer

81%
Answered correctly

07 secs
Time Spent

04/28/2020
Last Updated

Explanation

This patient, who is HIV negative, has a positive titer for **cytomegalovirus** (CMV) IgG, suggesting prior CMV infection. CMV is a rare cause of disease in the immunocompetent, with the virus more typically responsible for subclinical infection. When primary CMV infection does result in clinically evident illness, affected individuals appear to have a systemic **mononucleosis-like syndrome** characterized by fever, malaise, myalgia, atypical lymphocytosis, and elevated liver transaminases. In contrast to Epstein-Barr virus mononucleosis (most common), heterophile antibodies are not usually present in patients with CMV mononucleosis (negative Monospot test).

(Choices A and D) Odynophagia (painful swallowing) associated with linear esophageal ulcers due to CMV infection is seen in patients with HIV. Retinitis is one of the most common manifestations of CMV infection in patients with HIV.

(Choice B) Disseminated CMV can cause diarrhea and hepatitis in the immunocompromised. In this patient, the combination of a positive hepatitis B surface antibody with a negative hepatitis B surface antigen and a negative hepatitis B core antibody reflects immunization against hepatitis B, not prior hepatitis B infection.

(Choice E) A vesicular skin rash is seen in association with herpes simplex or herpes zoster virus infection.

(Choice F) CMV pneumonitis typically occurs after organ transplantation.

Educational objective:
Cytomegalovirus (CMV) is typically associated with subclinical infection in the immunocompetent, with the occasional individual developing a mononucleosis-like syndrome that is heterophile antibody (Monospot) negative. In the immunocompromised, primary or reactivated CMV infection can result in severe retinitis, pneumonia, esophagitis, colitis, or hepatitis.

Microbiology	General Principles	Cytomegalovirus
Subject	System	Topic

Copyright © UWorld. All rights reserved.

A 42-year-old homeless man comes to the emergency department due to painful muscle spasms. The patient has had frequent involuntary contractions of the jaw, neck, and trunk muscles, which are triggered by sensory stimuli. He has a history of injection drug use and has had several injection site infections. Physical examination shows neck stiffness and decreased opening of the jaw. Which of the following is the most likely path taken by the agent responsible for this patient's condition?

A. Bite wound → peripheral nerves → CNS neurons

B. Contaminated food → systemic circulation → presynaptic nerve terminals

C. Infected wound → systemic circulation → brain parenchyma

D. Nasopharyngeal exudate → systemic circulation → neurons

E. Oral mucosa → trigeminal nerve → temporal lobe

F. Puncture wound → motor neurons → spinal cord interneurons

Submit

A 42-year-old homeless man comes to the emergency department due to painful muscle spasms. The patient has had frequent involuntary contractions of the jaw, neck, and trunk muscles, which are triggered by sensory stimuli. He has a history of injection drug use and has had several injection site infections. Physical examination shows neck stiffness and decreased opening of the jaw. Which of the following is the most likely path taken by the agent responsible for this patient's condition?

A. Bite wound → peripheral nerves → CNS neurons (8%)

B. Contaminated food → systemic circulation → presynaptic nerve terminals (4%)

C. Infected wound → systemic circulation → brain parenchyma (8%)

D. Nasopharyngeal exudate → systemic circulation → neurons (1%)

E. Oral mucosa → trigeminal nerve → temporal lobe (1%)

✓ F. Puncture wound → motor neurons → spinal cord interneurons (75%)

Omitted
Correct answer
F

75%
Answered correctly

01 sec
Time Spent

02/07/2020
Last Updated

Explanation

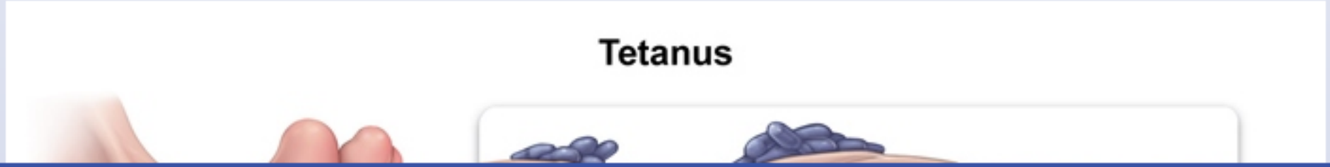

Tetanus

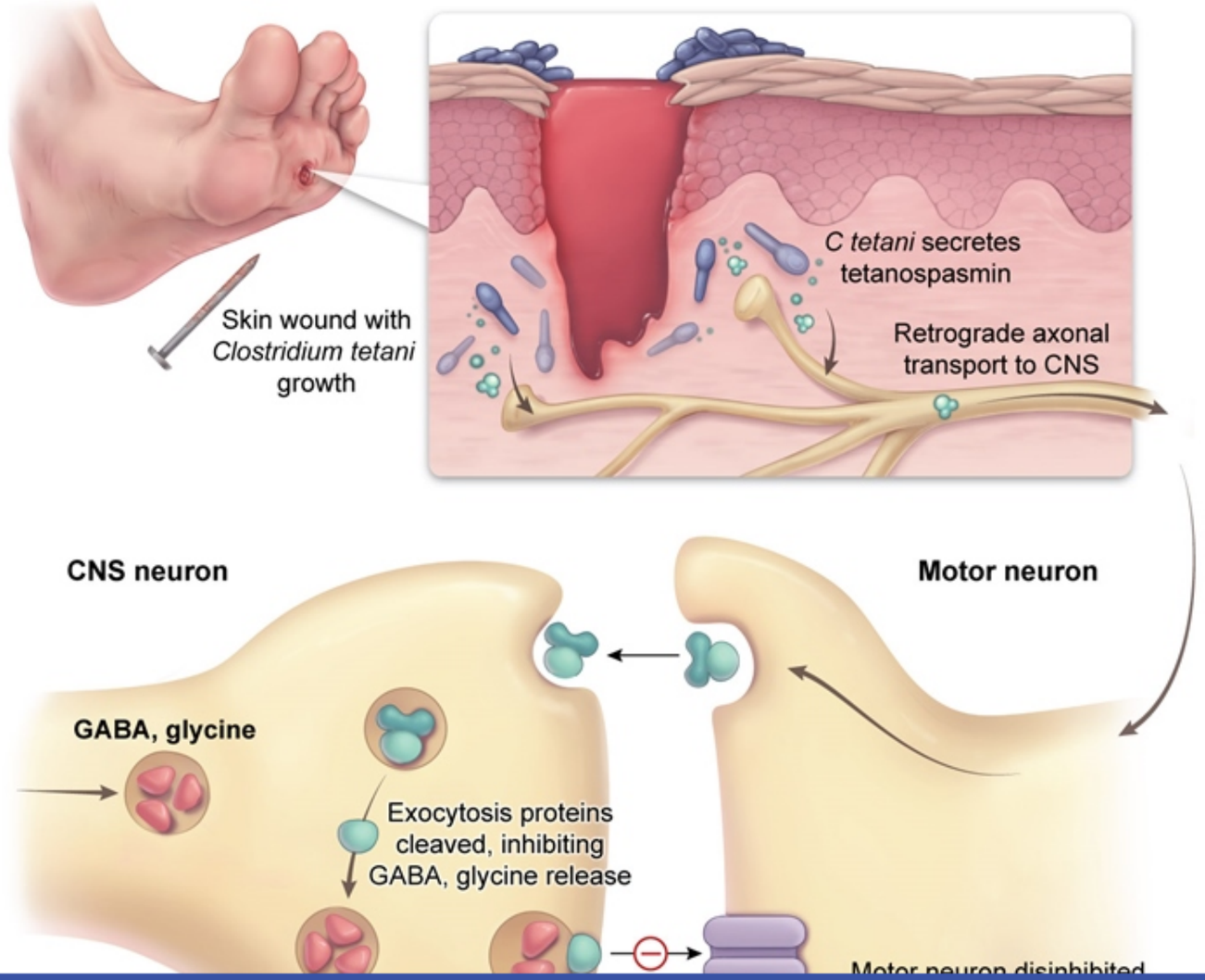
Skin wound with
Clostridium tetani
growth
C tetani secretes
tetanospasmin
Retrograde axonal
transport to CNS
CNS neuron
Motor neuron
GABA, glycine
Exocytosis proteins
cleaved, inhibiting
GABA, glycine release
Motor neuron disinhibited

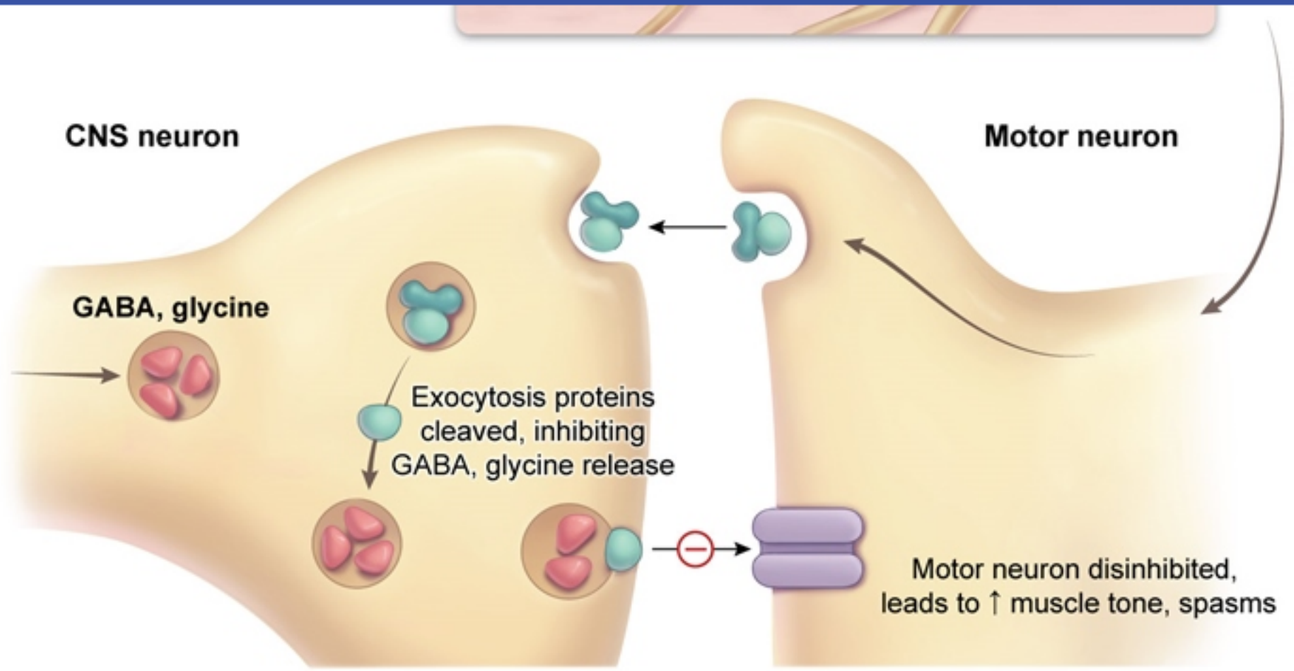

CNS = central nervous system.

©UWorld

This patient with painful muscle spasms and neck/jaw contraction likely has **tetanus**, which is caused by the spore-forming anaerobic bacterium *Clostridium tetani*. *C tetani* spores are found in soil worldwide and are typically transmitted to humans during a **puncture injury** (eg, dirty needle use, splinter). The low oxygen tension of a puncture wound allows spores to germinate into vegetative rod-shaped bacteria that proliferate locally and produce tetanospasmin (**tetanus toxin**).

Although the pathogen is noninvasive (it stays localized to the wound site), the toxin enters the presynaptic terminals of the lower **motor neurons** and travels by retrograde axonal transport to the CNS. In the spinal cord, at the level of the anterior horn cells, the toxin **blocks inhibitory interneurons**, leading to spasmodic muscle contraction. Classic findings include jaw stiffness due to masseter muscle spasm (trismus/lockjaw) and sustained contraction of the facial muscles, producing a bizarre "smiling" appearance (risus sardonicus). Spasmodic contraction of the back and neck can cause opisthotonos, and respiratory muscle involvement that can lead to respiratory failure.

This patient with painful muscle spasms and neck/jaw contraction likely has **tetanus**, which is caused by the spore-forming anaerobic bacterium *Clostridium tetani*. *C tetani* spores are found in soil worldwide and are typically transmitted to humans during a **puncture injury** (eg, dirty needle use, splinter). The low oxygen tension of a puncture wound allows spores to germinate into vegetative rod-shaped bacteria that proliferate locally and produce tetanospasmin (**tetanus toxin**).

Although the pathogen is noninvasive (it stays localized to the wound site), the toxin enters the presynaptic terminals of the lower **motor neurons** and travels by retrograde axonal transport to the CNS. In the spinal cord, at the level of the anterior horn cells, the toxin **blocks inhibitory interneurons**, leading to spasmodic muscle contraction. Classic findings include jaw stiffness due to masseter muscle spasm (trismus/lockjaw) and sustained contraction of the facial muscles, producing a bizarre "smiling" appearance (risus sardonicus). Spasmodic contraction of the back and neck can cause opisthotonos, and respiratory muscle involvement that can lead to respiratory failure.

(Choice A) Rabies virus is transmitted via the saliva of an infected animal during a bite wound. The virus spreads by retrograde axonal transport through peripheral nerves and enters the spinal cord/CNS. Patients with rabies usually develop painful pharyngeal spasms, hydrophobia, fever, and hyperactivity. However, this patient has no history of an animal bite; he likely developed tetanus due to a puncture wound with a contaminated needle.

(Choice B) Food-borne botulism is marked by the ingestion of preformed botulism toxin with subsequent spread through the systemic circulation. The toxin blocks cholinergic presynaptic nerve terminals, which results in symmetric, descending weakness.

(Choice C) Bacteria (eg, *Staphylococcus aureus*) from a wound can spread through the bloodstream to the brain leading to brain abscess. Symptoms vary but the most common manifestation is unilateral headache.

(Choice D) Diphtheria is associated with the formation of a pseudomembranous pharyngeal exudate and the elaboration of diphtheria toxin into the systemic circulation. The toxin causes cardiac (myocarditis) and neurologic toxicity.

(Choice E) Herpes simplex virus type 1 causes orolabial lesions and is the most frequent cause of sporadic encephalitis, which occurs when the virus spreads via the olfactory tract to the temporal lobe (olfactory cortex). Patients usually present with confusion, fever, focal neurologic deficits, and seizures.

Educational objective:

Tetanus is caused by infection with toxigenic strains of the anaerobic bacterium *Clostridium tetani*. Transmission typically occurs when spores are

and neck can cause opisthotonos, and respiratory muscle involvement that can lead to respiratory failure.

(Choice A) Rabies virus is transmitted via the saliva of an infected animal during a bite wound. The virus spreads by retrograde axonal transport through peripheral nerves and enters the spinal cord/CNS. Patients with rabies usually develop painful pharyngeal spasms, hydrophobia, fever, and hyperactivity. However, this patient has no history of an animal bite; he likely developed tetanus due to a puncture wound with a contaminated needle.

(Choice B) Food-borne botulism is marked by the ingestion of preformed botulism toxin with subsequent spread through the systemic circulation. The toxin blocks cholinergic presynaptic nerve terminals, which results in symmetric, descending weakness.

(Choice C) Bacteria (eg, *Staphylococcus aureus*) from a wound can spread through the bloodstream to the brain leading to brain abscess. Symptoms vary but the most common manifestation is unilateral headache.

(Choice D) Diphtheria is associated with the formation of a pseudomembranous pharyngeal exudate and the elaboration of diphtheria toxin into the systemic circulation. The toxin causes cardiac (myocarditis) and neurologic toxicity.

(Choice E) Herpes simplex virus type 1 causes orolabial lesions and is the most frequent cause of sporadic encephalitis, which occurs when the virus spreads via the olfactory tract to the temporal lobe (olfactory cortex). Patients usually present with confusion, fever, focal neurologic deficits, and seizures.

Educational objective:
Tetanus is caused by infection with toxigenic strains of the anaerobic bacterium *Clostridium tetani*. Transmission typically occurs when spores are inoculated into the skin via a puncture wound. The bacteria germinate, replicate locally, and elaborate tetanospasmin (tetanus toxoid). The toxin spreads in a retrograde fashion through the lower motor neurons to the spinal cord, where it blocks inhibitory interneurons and causes spasmodic muscle contraction (eg, trismus, risus sardonicus).

Microbiology	Nervous System	Tetanus
Subject	System	Topic

Copyright © UWorld. All rights reserved.

A 3-year-old boy is brought to the office due to a 1-day history of fever and irritability. The mother states that the boy has been tugging at his right ear. The patient has had 2 previous episodes of acute otitis media. Temperature is 38.1 C (100.6 F). Otoscopic examination shows a perforated right tympanic membrane with erythema and purulent exudate. Cultures from the exudate yield small, oxidase-positive, gram-negative coccobacilli that grow on factor X– and factor V–supplemented media, consistent with *Haemophilus influenzae*. The patient's immunizations are up to date. Which of the following best explains this patient's susceptibility to the pathogen causing his current infection?

- A. No vaccine is effective against *H influenzae*
- B. The patient has defective cell-mediated immunity
- C. The patient has defective neutrophil function
- D. The strain responsible for this patient's disease does not produce a capsule
- E. The strain responsible for this patient's disease produces exotoxin

Submit

A 3-year-old boy is brought to the office due to a 1-day history of fever and irritability. The mother states that the boy has been tugging at his right ear. The patient has had 2 previous episodes of acute otitis media. Temperature is 38.1 C (100.6 F). Otoscopic examination shows a perforated right tympanic membrane with erythema and purulent exudate. Cultures from the exudate yield small, oxidase-positive, gram-negative coccobacilli that grow on factor X– and factor V–supplemented media, consistent with *Haemophilus influenzae*. The patient's immunizations are up to date. Which of the following best explains this patient's susceptibility to the pathogen causing his current infection?

- A. No vaccine is effective against *H influenzae* (2%)
- B. The patient has defective cell-mediated immunity (16%)
- C. The patient has defective neutrophil function (11%)
- ✓ D. The strain responsible for this patient's disease does not produce a capsule (65%)
- E. The strain responsible for this patient's disease produces exotoxin (4%)

Omitted
Correct answer
D

65%
Answered correctly

02 secs
Time Spent

01/19/2020
Last Updated

Explanation

This patient with fever and an inflamed, perforated tympanic membrane with purulent otorrhea has **acute otitis media**. Middle ear infections occur most commonly in young children (age 6 months to 2 years) and are typically due to *Streptococcus pneumoniae* or ***Haemophilus influenzae***.

H influenzae is a small, oxidase-positive, gram-negative coccobacillus classified by the antigens in its polysaccharide **capsule**. Strains of *H*

Explanation

This patient with fever and an inflamed, perforated tympanic membrane with purulent otorrhea has **acute otitis media**. Middle ear infections occur most commonly in young children (age 6 months to 2 years) and are typically due to *Streptococcus pneumoniae* or ***Haemophilus influenzae***.

H influenzae is a small, oxidase-positive, gram-negative coccobacillus classified by the antigens in its polysaccharide **capsule**. Strains of *H influenzae* that do not produce a capsule are referred to as **nontypeable**. These nontypeable strains are part of the normal upper respiratory tract flora but can also cause acute otitis media, sinusitis, and bronchitis. Most *H influenzae* strains isolated from middle ear aspirates of children with acute otitis media are nontypeable.

Vaccination against *H influenzae* is with the protein-conjugated **Hib vaccine**, which confers immunity only to the more invasive **type b** strain **(Choice A)**. The vaccine is recommended in all children beginning at age 2 months to prevent Hib-associated bacteremia, pneumonia, epiglottitis, and meningitis.

(Choice B) The Hib vaccine contains capsular polysaccharide components to induce anticapsular antibodies (humoral immune response). Because the antibody response is weak in children, the vaccine is also conjugated with toxoid protein, which stimulates a helper T-cell response to help activate B-cell antibody formation. A cell-mediated cytotoxic T-cell response is not induced.

(Choice C) Poor neutrophil function or a low neutrophil count predisposes to bacterial disease. However, neutrophil dysfunction (eg, chronic granulomatous disease, Chédiak-Higashi syndrome) typically presents with recurrent, severe bacterial infections such as pneumonia and abscesses. Ear infections due to *H influenzae* infection despite immunization with the Hib vaccine are more likely due to infection with a nontypeable strain than defective neutrophils.

(Choice E) Exotoxins are secreted by certain bacteria (eg, *Clostridium botulinum*, *Corynebacterium diphtheriae*) to promote cell death but are not generally produced by any strain of *H influenzae*. The Hib vaccine is directed against capsular polysaccharide, not toxin.

Educational objective:
Nontypeable strains of *Haemophilus influenzae* are part of the normal upper respiratory tract flora and are a common cause of acute otitis media, sinusitis, and bronchitis. Because nontypeable strains do not form a polysaccharide capsule, immunity is not conferred by vaccination with the *H influenzae* type b vaccine.

(Choice A). The vaccine is recommended in all children beginning at age 2 months to prevent Hib-associated bacteremia, pneumonia, epiglottitis, and meningitis.

(Choice B) The Hib vaccine contains capsular polysaccharide components to induce anticapsular antibodies (humoral immune response). Because the antibody response is weak in children, the vaccine is also conjugated with toxoid protein, which stimulates a helper T-cell response to help activate B-cell antibody formation. A cell-mediated cytotoxic T-cell response is not induced.

(Choice C) Poor neutrophil function or a low neutrophil count predisposes to bacterial disease. However, neutrophil dysfunction (eg, chronic granulomatous disease, Chédiak-Higashi syndrome) typically presents with recurrent, severe bacterial infections such as pneumonia and abscesses. Ear infections due to *H influenzae* infection despite immunization with the Hib vaccine are more likely due to infection with a nontypeable strain than defective neutrophils.

(Choice E) Exotoxins are secreted by certain bacteria (eg, *Clostridium botulinum*, *Corynebacterium diphtheriae*) to promote cell death but are not generally produced by any strain of *H influenzae*. The Hib vaccine is directed against capsular polysaccharide, not toxin.

Educational objective:
Nontypeable strains of *Haemophilus influenzae* are part of the normal upper respiratory tract flora and are a common cause of acute otitis media, sinusitis, and bronchitis. Because nontypeable strains do not form a polysaccharide capsule, immunity is not conferred by vaccination with the *H influenzae* type b vaccine.

References

- Etiology of acute otitis media and serotype distribution of Streptococcus pneumoniae and Haemophilus influenzae in Chilean children <5 years of age.
- Non-capsulated and capsulated Haemophilus influenzae in children with acute otitis media in Venezuela: a prospective epidemiological study.

Microbiology	Ear, Nose & Throat (ENT)	Otitis media
Subject	System	Topic

Copyright © UWorld. All rights reserved.

Settings

1
2
3
4
5
6
7
8
9
10
11
12
13
14
15
16
17
18
19
20
21
22
23
24
25
26
27
28
29
30

Item 5 of 38
Question Id: 1102

Mark | Previous | Next | Full Screen | Tutorial | Lab Values | Notes | Calculator | Reverse Color | Text Zoom | Settings

Exhibit Display



Zoom In | Zoom Out | Reset | Add To New Card | Existing Card

granulomatous disease, Chédiak-Higashi syndrome) typically presents with recurrent, severe bacterial infections such as pneumonia and

Block Time Remaining: 00:00:25
TUTOR

4 | Feedback | Suspend | End Block

Exhibit Display

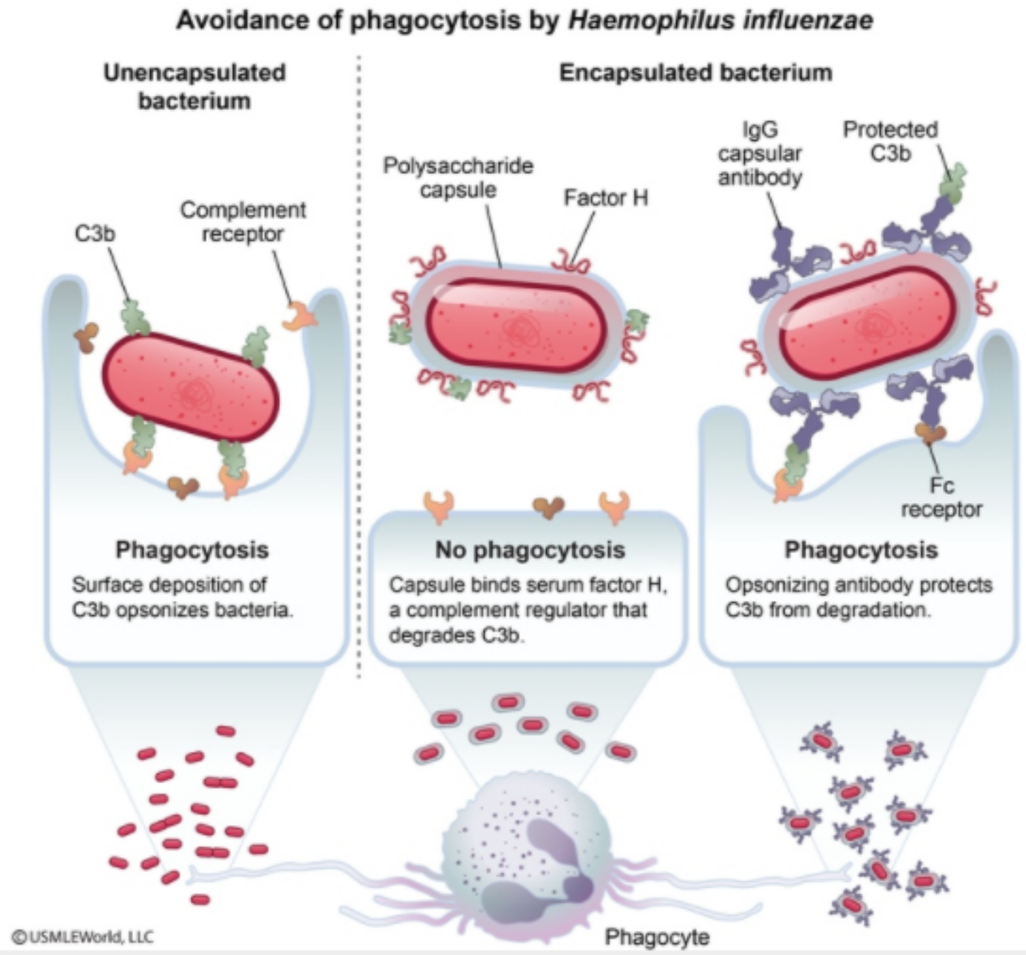

Zoom In Zoom Out Reset Add To New Card | Existing Card

granulomatous disease, Chédiak-Higashi syndrome) typically presents with recurrent, severe bacterial infections such as pneumonia and

A 40-year-old woman is evaluated for neck pain that has gradually worsened over the past several months. The patient reports a pulling sensation in her neck that causes difficulty in keeping her head straight. She has had no trauma and has no other medical conditions. Physical examination shows a spastic and thickened sternocleidomastoid muscle causing head tilt. The patient is diagnosed with idiopathic torticollis. She is treated with injections of a bacterial product into the affected muscle, with significant relief of her symptoms. The substance administered to this patient is derived from bacteria that most likely demonstrate which of the following characteristics?

- A. Antigenically hypervariable pili
- B. Antiphagocytic capsule
- C. IgG-binding outer membrane protein
- D. Intracellular polyphosphate granules
- E. Subterminal spore formation
- F. Type III secretion system

Submit

A 40-year-old woman is evaluated for neck pain that has gradually worsened over the past several months. The patient reports a pulling sensation in her neck that causes difficulty in keeping her head straight. She has had no trauma and has no other medical conditions. Physical examination shows a spastic and thickened sternocleidomastoid muscle causing head tilt. The patient is diagnosed with idiopathic torticollis. She is treated with injections of a bacterial product into the affected muscle, with significant relief of her symptoms. The substance administered to this patient is derived from bacteria that most likely demonstrate which of the following characteristics?

- A. Antigenically hypervariable pili (1%)
- B. Antiphagocytic capsule (4%)
- C. IgG-binding outer membrane protein (4%)
- D. Intracellular polyphosphate granules (4%)
- ✓ E. Subterminal spore formation (80%)
- F. Type III secretion system (5%)

Omitted
Correct answer
E

80%
Answered correctly

02 secs
Time Spent

05/04/2020
Last Updated

Explanation

Botulism

Botulism

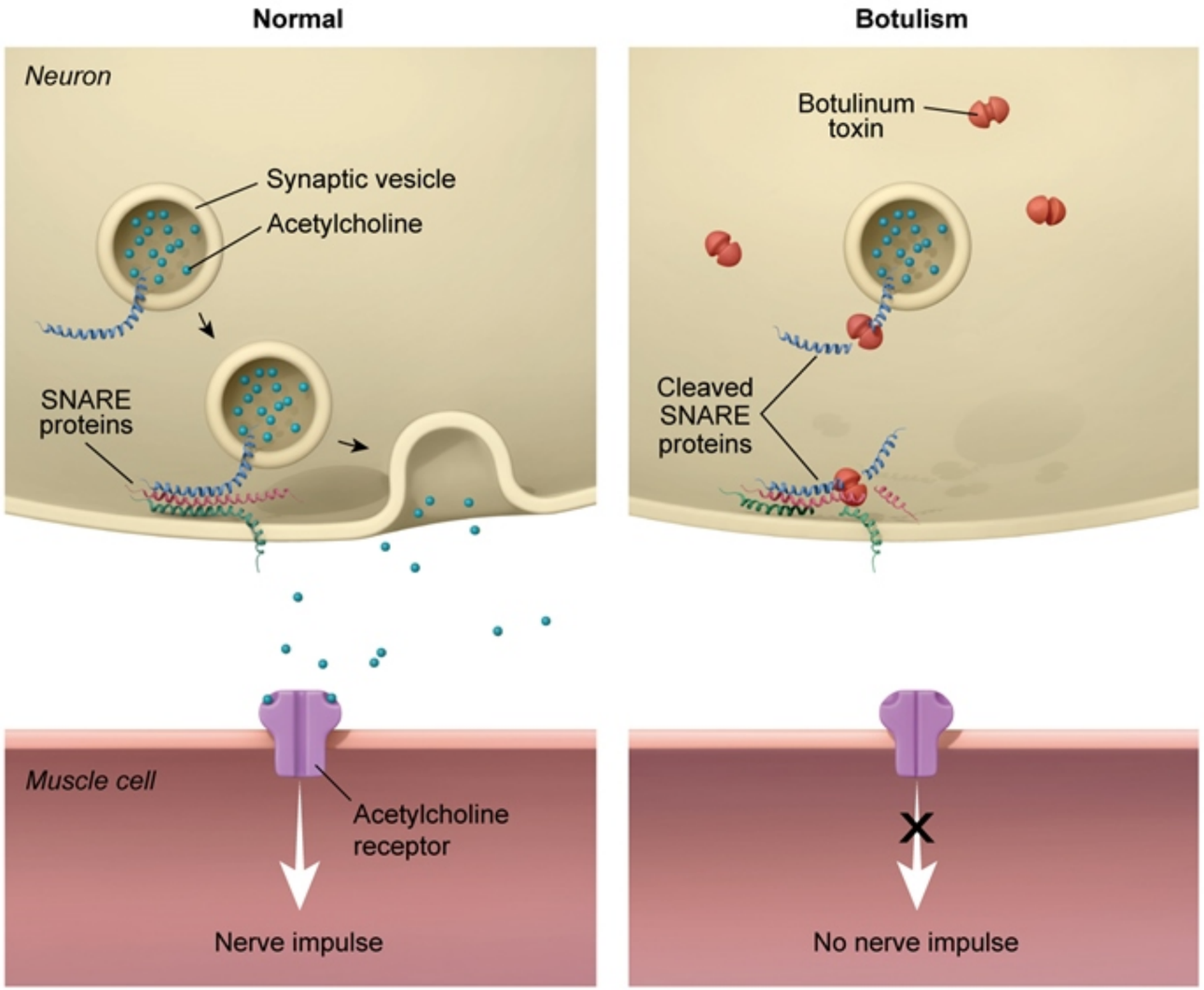
Normal
Botulism
Neuron
Synaptic vesicle
Acetylcholine
SNARE proteins
Botulinum toxin
Cleaved SNARE proteins
Muscle cell
Acetylcholine receptor
Nerve impulse
No nerve impulse

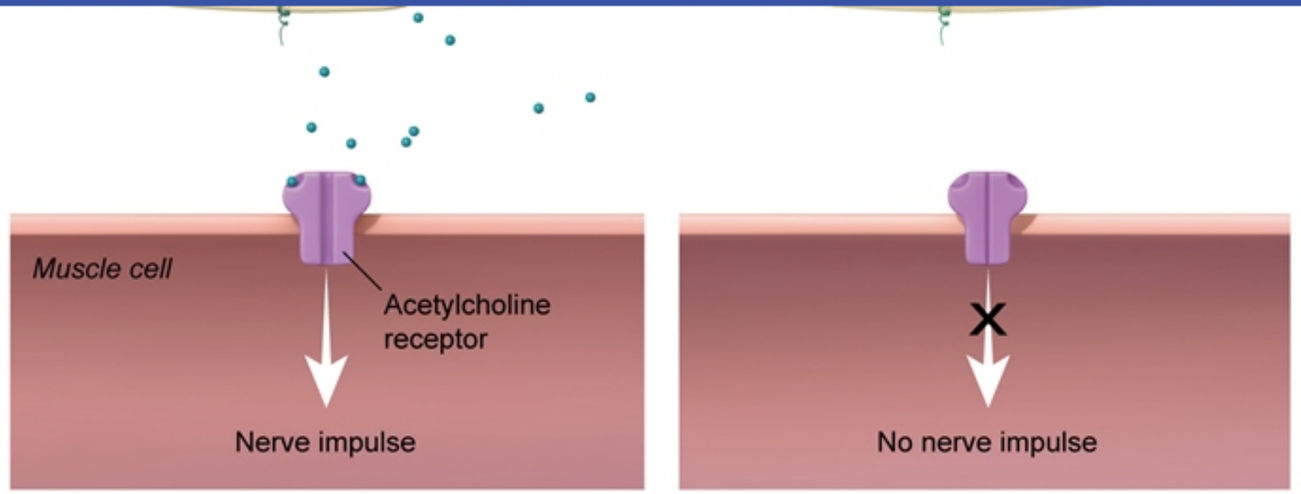

©UWorld

Clostridium botulinum is a gram-positive, anaerobic bacillus that synthesizes botulinum toxin intracellularly and releases it by autolysis. **Botulinum toxin** prevents the presynaptic release of acetylcholine from the nerve terminal at the neuromuscular junction. This prevents both nicotinic and muscarinic activation, leading to **skeletal muscle weakness** and reduced glandular secretions, respectively. Botulism is a result of toxin ingestion and is characterized by cranial nerve deficits and descending symmetric paralysis. **Spore formation**, which occurs in the **subterminal location** (between the terminal end and center of the bacteria), allows the bacteria to survive adverse conditions (eg, heat, high-oxygen environment).

Focal dystonia is a localized, uncontrollable muscle contraction that can lead to pain and physical deformity. **Torticollis** is a common manifestation of dystonia and is due to involvement of the sternocleidomastoid muscle. Injection of botulinum toxin type B into the dystonic muscle results in muscular relaxation and **relief of symptoms**. Botulinum toxin can also be used to treat the muscle spasms of multiple sclerosis and Parkinson disease, to relax the lower esophageal sphincter in achalasia, and to reduce the appearance of facial wrinkles. The localized anticholinergic effect also makes it useful in the treatment of hyperhydrosis. The effects are temporary (approximately 3 months), due to the regeneration of the nerve terminal with time.

(Choice A) Hypervariable pili are characteristic of *Neisseria meningitidis* and *Neisseria gonorrhoeae*; antigenic heterogeneity aids in immune evasion and allows for repeat infections.

oxygen environment).

Focal dystonia is a localized, uncontrollable muscle contraction that can lead to pain and physical deformity. **Torticollis** is a common manifestation of dystonia and is due to involvement of the sternocleidomastoid muscle. Injection of botulinum toxin type B into the dystonic muscle results in muscular relaxation and **relief of symptoms**. Botulinum toxin can also be used to treat the muscle spasms of multiple sclerosis and Parkinson disease, to relax the lower esophageal sphincter in achalasia, and to reduce the appearance of facial wrinkles. The localized anticholinergic effect also makes it useful in the treatment of hyperhydrosis. The effects are temporary (approximately 3 months), due to the regeneration of the nerve terminal with time.

(Choice A) Hypervariable pili are characteristic of *Neisseria meningitidis* and *Neisseria gonorrhoeae*; antigenic heterogeneity aids in immune evasion and allows for repeat infections.

(Choice B) The antiphagocytic capsule is a primary virulence factor for *Streptococcus pneumoniae*, *Haemophilus influenzae*, *Klebsiella pneumonia*, and *Neisseria meningitidis*.

(Choice C) *Staphylococcus aureus* has an IgG-binding outer membrane protein—the protein A virulence factor—which binds the Fc portions of IgG, thereby preventing opsonization, phagocytosis, and complement fixation.

(Choice D) Intracellular polyphosphate granules are seen on methylene blue staining and are an identifying characteristic of *Corynebacterium diphtheriae*.

(Choice F) Type III secretion systems allow bacteria to inject proteins directly into host cells to avoid invoking an immune response. They are seen in many gram-negative bacteria, including *Shigella*, *Salmonella*, *Pseudomonas*, *Yersinia*, and enteropathogenic *Escherichia coli*.

Educational objective:
Clostridium botulinum is a spore-forming, gram-positive, anaerobic bacillus that synthesizes botulinum toxin, which prevents the presynaptic release of acetylcholine from the nerve terminal at the neuromuscular junction. Botulinum toxin can be used to treat focal dystonia and other disorders of abnormal muscle contraction.

Microbiology	Nervous System	Botulism
Subject	System	Topic

manifestation of dystonia and is due to involvement of the sternocleidomastoid muscle. Injection of botulinum toxin type B into the dystonic muscle results in muscular relaxation and **relief of symptoms**. Botulinum toxin can also be used to treat the muscle spasms of multiple sclerosis and Parkinson disease, to relax the lower esophageal sphincter in achalasia, and to reduce the appearance of facial wrinkles. The localized anticholinergic effect also makes it useful in the treatment of hyperhydrosis. The effects are temporary (approximately 3 months), due to the regeneration of the nerve terminal with time.

(Choice A) Hypervariable pili are characteristic of *Neisseria meningitidis* and *Neisseria gonorrhoeae*; antigenic heterogeneity aids in immune evasion and allows for repeat infections.

(Choice B) The antiphagocytic capsule is a primary virulence factor for *Streptococcus pneumoniae*, *Haemophilus influenzae*, *Klebsiella pneumonia*, and *Neisseria meningitidis*.

(Choice C) *Staphylococcus aureus* has an IgG-binding outer membrane protein—the protein A virulence factor—which binds the Fc portions of IgG, thereby preventing opsonization, phagocytosis, and complement fixation.

(Choice D) Intracellular polyphosphate granules are seen on methylene blue staining and are an identifying characteristic of *Corynebacterium diphtheriae*.

(Choice F) Type III secretion systems allow bacteria to inject proteins directly into host cells to avoid invoking an immune response. They are seen in many gram-negative bacteria, including *Shigella*, *Salmonella*, *Pseudomonas*, *Yersinia*, and enteropathogenic *Escherichia coli*.

Educational objective:
Clostridium botulinum is a spore-forming, gram-positive, anaerobic bacillus that synthesizes botulinum toxin, which prevents the presynaptic release of acetylcholine from the nerve terminal at the neuromuscular junction. Botulinum toxin can be used to treat focal dystonia and other disorders of abnormal muscle contraction.

Microbiology	Nervous System	Botulism
Subject	System	Topic

Copyright © UWorld. All rights reserved.

Settings

1 2 3 4 5 6 7 8 9 10 11 12 13 14 15 16 17 18 19 20 21 22 23 24 25 26 27 28 29 30

Item 7 of 38
Question Id: 118

Mark | Previous | Next | Full Screen | Tutorial | Lab Values | Notes | Calculator | Reverse Color | Text Zoom | Settings

A 54-year-old man is brought to the emergency department due to a week of progressive headaches and confusion. He was treated for viral esophagitis 6 months ago and *Pneumocystis* pneumonia 2 months ago. Temperature is 38 C (100.4 F), blood pressure is 142/86 mm Hg, and pulse is 64/min. The patient is lethargic and oriented to person and place only. CT scan of the head shows a mildly increased ventricle size but no other abnormalities. Lumbar puncture reveals an elevated opening pressure, and cerebrospinal fluid analysis shows moderately increased protein concentration and pleocytosis. The latex agglutination test is positive for soluble polysaccharide antigen. Light microscopy of this patient's cerebrospinal fluid is most likely to reveal which of the following?

A. Budding yeast

B. Germ tubes

C. Nonseptate hyphae

D. Spherules with endospore

E. Sporangium

Submit

Block Time Remaining: 00:00:27
TUTOR

7 | Feedback | Suspend | End Block

A 54-year-old man is brought to the emergency department due to a week of progressive headaches and confusion. He was treated for viral esophagitis 6 months ago and *Pneumocystis* pneumonia 2 months ago. Temperature is 38 C (100.4 F), blood pressure is 142/86 mm Hg, and pulse is 64/min. The patient is lethargic and oriented to person and place only. CT scan of the head shows a mildly increased ventricle size but no other abnormalities. Lumbar puncture reveals an elevated opening pressure, and cerebrospinal fluid analysis shows moderately increased protein concentration and pleocytosis. The latex agglutination test is positive for soluble polysaccharide antigen. Light microscopy of this patient's cerebrospinal fluid is most likely to reveal which of the following?

- ✓ A. Budding yeast (42%)
- B. Germ tubes (7%)
- C. Nonseptate hyphae (10%)
- D. Spherules with endospore (25%)
- E. Sporangium (14%)

Omitted
Correct answer
A

42%
Answered correctly

03 secs
Time Spent

03/05/2020
Last Updated

Explanation

Cryptococcus neoformans	
Morphology	• **Yeast** with a **polysaccharide capsule**

Cryptococcus neoformans	
Morphology	• **Yeast** with a **polysaccharide capsule** • Round/oval cells with narrow-based buds
Epidemiology	• Soil and pigeon droppings • Respiratory transmission • Opportunistic infection in patients with **AIDS** (CD4 <100/mm^3)
Infection	• **Meningoencephalitis:** Progressive headache, fever, confusion • Possible disseminated disease
Diagnosis	• **India ink** stain of cerebrospinal fluid • Latex agglutination of cerebrospinal fluid • Culture using Sabouraud agar
Treatment	• **Amphotericin B** and flucytosine (induction) • Fluconazole (maintenance)

This patient's opportunistic infections (viral esophagitis, *Pneumocystosis* pneumonia) raise suspicion for **untreated AIDS**. He now has headache, fever, confusion, and polysaccharide antigens in the cerebrospinal fluid (CSF) indicating likely **cryptococcal meningitis**. This opportunistic infection is caused by *Cryptococcus neoformans*, a yeast with a thick **polysaccharide capsule**. Diagnosis is often made by identifying polysaccharide (cryptococcal) antigens in the CSF using latex agglutination. Round or oval **budding yeast** can also be visualized with India ink stain. Most patients have **elevated opening pressures** on lumbar puncture due to increased vascular permeability secondary to inflammation and/or yeasts obstructing CSF outflow from the arachnoid villi.

(Choice B) *Candida albicans* forms germ tubes (true hyphae) if incubated in 37 C (98.6 F) serum for 3 hours. This test helps differentiate *C albicans* from other *Candida* species. *C albicans* meningitis is extremely rare (even in patients with HIV) and would not be associated with a positive polysaccharide antigen.

	• Fluconazole (maintenance)

This patient's opportunistic infections (viral esophagitis, *Pneumocystosis* pneumonia) raise suspicion for **untreated AIDS**. He now has headache, fever, confusion, and polysaccharide antigens in the cerebrospinal fluid (CSF) indicating likely **cryptococcal meningitis**. This opportunistic infection is caused by *Cryptococcus neoformans*, a yeast with a thick **polysaccharide capsule**. Diagnosis is often made by identifying polysaccharide (cryptococcal) antigens in the CSF using latex agglutination. Round or oval **budding yeast** can also be visualized with India ink stain. Most patients have **elevated opening pressures** on lumbar puncture due to increased vascular permeability secondary to inflammation and/or yeasts obstructing CSF outflow from the arachnoid villi.

(Choice B) *Candida albicans* forms germ tubes (true hyphae) if incubated in 37 C (98.6 F) serum for 3 hours. This test helps differentiate *C albicans* from other *Candida* species. *C albicans* meningitis is extremely rare (even in patients with HIV) and would not be associated with a positive polysaccharide antigen.

(Choice C) *Mucor* and *Rhizopus* species are characterized by nonseptate hyphae that branch at wide angles. These fungi cause severe infections of the paranasal sinuses (mucormycosis) in patients who are immunosuppressed (eg, diabetes mellitus).

(Choice D) *Coccidioides immitis* is associated with the formation of spherules, which then rupture to release endospores. This fungus primarily causes community-acquired pneumonia in endemic areas (eg, Arizona desert); central nervous system infection is quite rare and would not be associated with a positive polysaccharide antigen.

(Choice E) Mold fungi (eg, *Rhizopus*) form sporangia, which produce and contain spores. *Cryptococcus* is a yeast and does not reproduce with sporangia.

Educational objective:
Cryptococcus neoformans causes meningoencephalitis in patients with untreated AIDS. Diagnosis can be made by detecting the polysaccharide capsule in cerebrospinal fluid using the latex agglutination test. India ink staining of cerebrospinal fluid is also used for diagnosis and can demonstrate round or oval budding yeast.

Microbiology	Nervous System	Meningitis
Subject	System	Topic

fever, confusion, and polysaccharide antigens in the cerebrospinal fluid (CSF) indicating likely **cryptococcal meningitis**. This opportunistic infection is caused by *Cryptococcus neoformans*, a yeast with a thick **polysaccharide capsule**. Diagnosis is often made by identifying polysaccharide (cryptococcal) antigens in the CSF using latex agglutination. Round or oval **budding yeast** can also be visualized with India ink stain. Most patients have **elevated opening pressures** on lumbar puncture due to increased vascular permeability secondary to inflammation and/or yeasts obstructing CSF outflow from the arachnoid villi.

(Choice B) *Candida albicans* forms germ tubes (true hyphae) if incubated in 37 C (98.6 F) serum for 3 hours. This test helps differentiate *C albicans* from other *Candida* species. *C albicans* meningitis is extremely rare (even in patients with HIV) and would not be associated with a positive polysaccharide antigen.

(Choice C) *Mucor* and *Rhizopus* species are characterized by nonseptate hyphae that branch at wide angles. These fungi cause severe infections of the paranasal sinuses (mucormycosis) in patients who are immunosuppressed (eg, diabetes mellitus).

(Choice D) *Coccidioides immitis* is associated with the formation of spherules, which then rupture to release endospores. This fungus primarily causes community-acquired pneumonia in endemic areas (eg, Arizona desert); central nervous system infection is quite rare and would not be associated with a positive polysaccharide antigen.

(Choice E) Mold fungi (eg, *Rhizopus*) form sporangia, which produce and contain spores. *Cryptococcus* is a yeast and does not reproduce with sporangia.

Educational objective:
Cryptococcus neoformans causes meningoencephalitis in patients with untreated AIDS. Diagnosis can be made by detecting the polysaccharide capsule in cerebrospinal fluid using the latex agglutination test. India ink staining of cerebrospinal fluid is also used for diagnosis and can demonstrate round or oval budding yeast.

Microbiology	Nervous System	Meningitis
Subject	System	Topic

Copyright © UWorld. All rights reserved.

Treatment	• **Amphotericin B** and flucytosine (induction) • Fluconazole (maintenance)

This patient's opportunistic infections (viral esophagitis, *Pneumocystosis* pneumonia fever, confusion, and polysaccharide antigens in the cerebrospinal fluid (CSF) indica infection is caused by *Cryptococcus neoformans*, a yeast with a thick **polysacchari** polysaccharide (cryptococcal) antigens in the CSF using latex agglutination. Round stain. Most patients have **elevated opening pressures** on lumbar puncture due to and/or yeasts obstructing CSF outflow from the arachnoid villi.

(Choice B) *Candida albicans* forms germ tubes (true hyphae) if incubated in 37 C (*albicans* from other *Candida* species. *C albicans* meningitis is extremely rare (even positive polysaccharide antigen.

(Choice C) *Mucor* and *Rhizopus* species are characterized by nonseptate hyphae t infections of the paranasal sinuses (mucormycosis) in patients w

Highlight

(Choice D) *Coccidioides immitis* is associated with the formation of spherules, whic causes community-acquired pneumonia in endemic areas (eg, Arizona desert); cent associated with a positive polysaccharide antigen.

(Choice E) Mold fungi (eg, *Rhizopus*) form sporangia, which produce and contain s sporangia.

Educational objective:
Cryptococcus neoformans causes meningoencephalitis in patients with untreated Al capsule in cerebrospinal fluid using the latex agglutination test. India ink staining of demonstrate round or oval budding yeast.

Microbiology Nervous System Meningitis

Exhibit Display

Abdominal mucormycosis

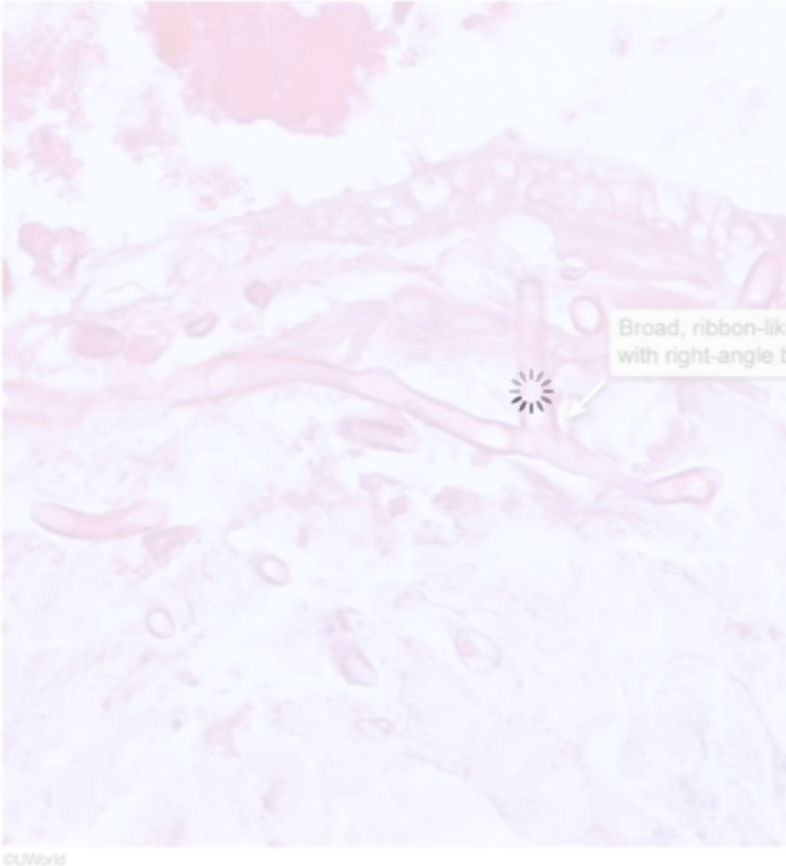

Zoom In | Zoom Out | Reset | Add To New

1 2 3 4 5 6 7 8 9 10 11 12 13 14 15 16 17 18 19 20 21 22 23 24 25 26 27 28 29 30

Treatment	• **Amphotericin B** and flucytosine (induction) • Fluconazole (maintenance)

This patient
fever, confu
infection is
polysaccha
stain. Most
and/or yeas

(Choice B)
albicans fro
positive pol

(Choice C)
infections o

(Choice D)
causes com
associated

(Choice E)
sporangia.

Educationa
Cryptococc
capsule in c
demonstrat

Microbiolog

Exhibit Display

Abdominal mucormycosis

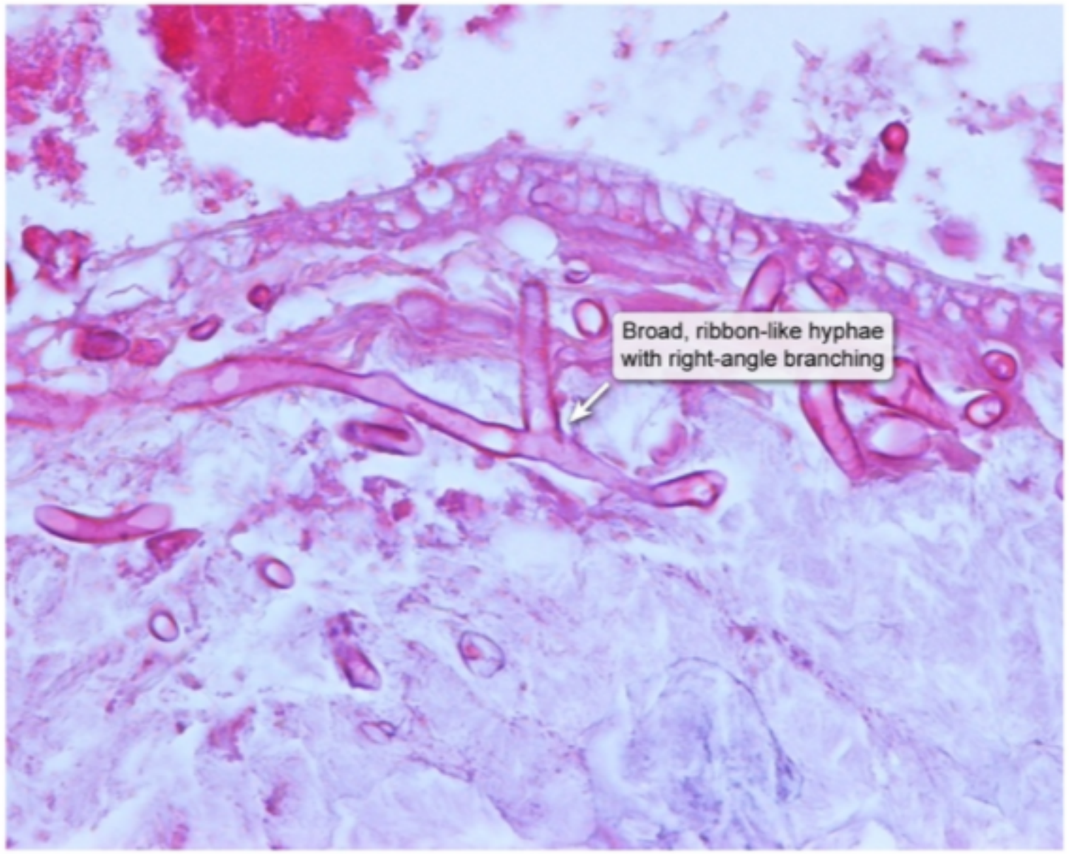

©UWorld

Zoom In | Zoom Out | Reset | Add To New Card | Existing Card

1
2
3
4
5
6
7
8
9
10
11
12
13
14
15
16
17
18
19
20
21
22
23
24
25
26
27
28
29
30

- **Amphotericin B** and flucytosine (induction)

Exhibit Display

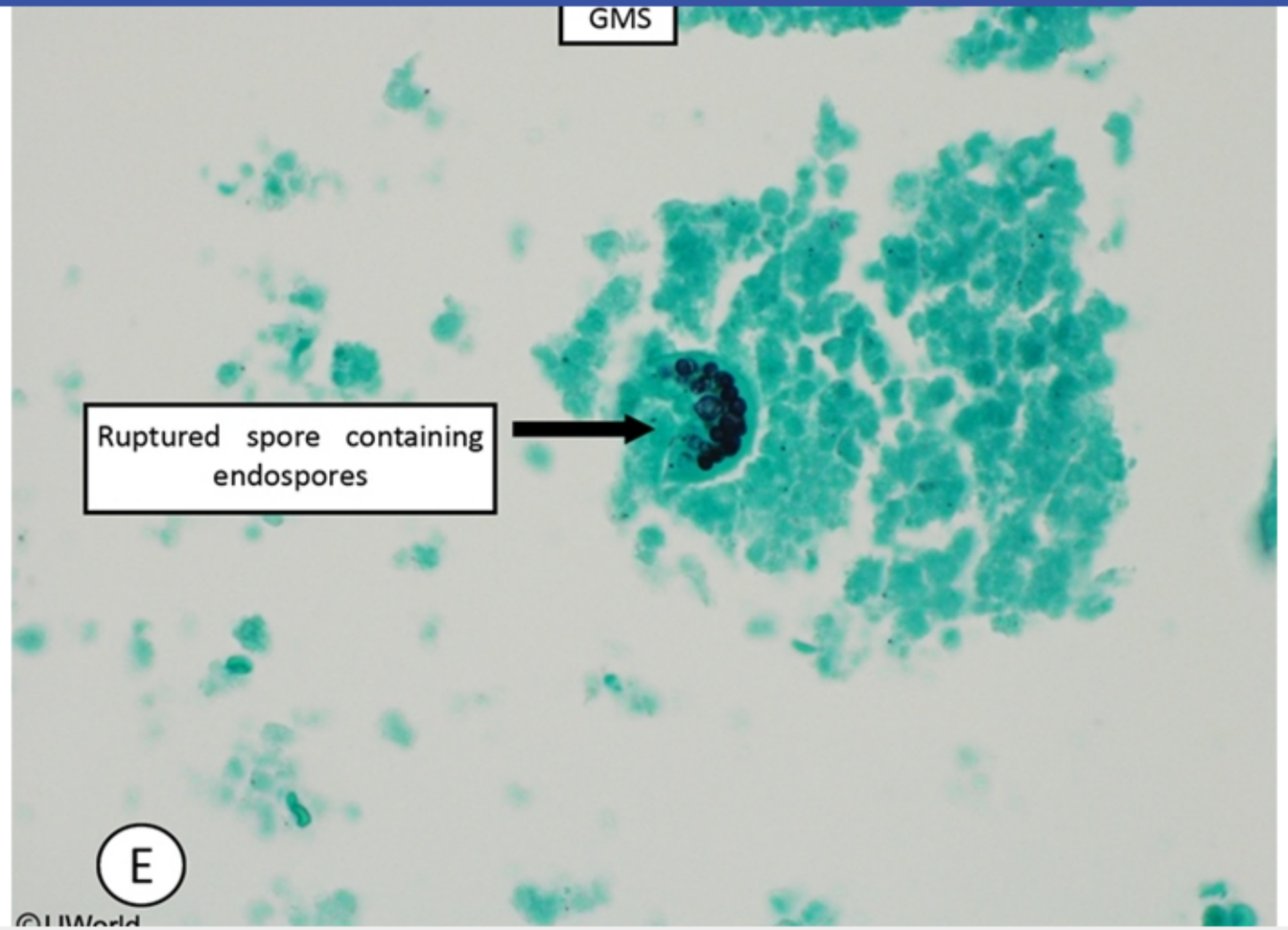

Zoom In | Zoom Out | Reset | Add To New Card | Existing Card

Microbiology | Nervous System | Meningitis

Settings

1 2 3 4 5 6 7 8 9 10 11 12 13 14 15 16 17 18 19 20 21 22 23 24 25 26 27 28 29 30

Item 7 of 38
Question Id: 118

Mark | Previous | Next | Full Screen | Tutorial | Lab Values | Notes | Calculator | Reverse Color | Text Zoom | Settings

- **Amphotericin B** and flucytosine (induction)

Exhibit Display

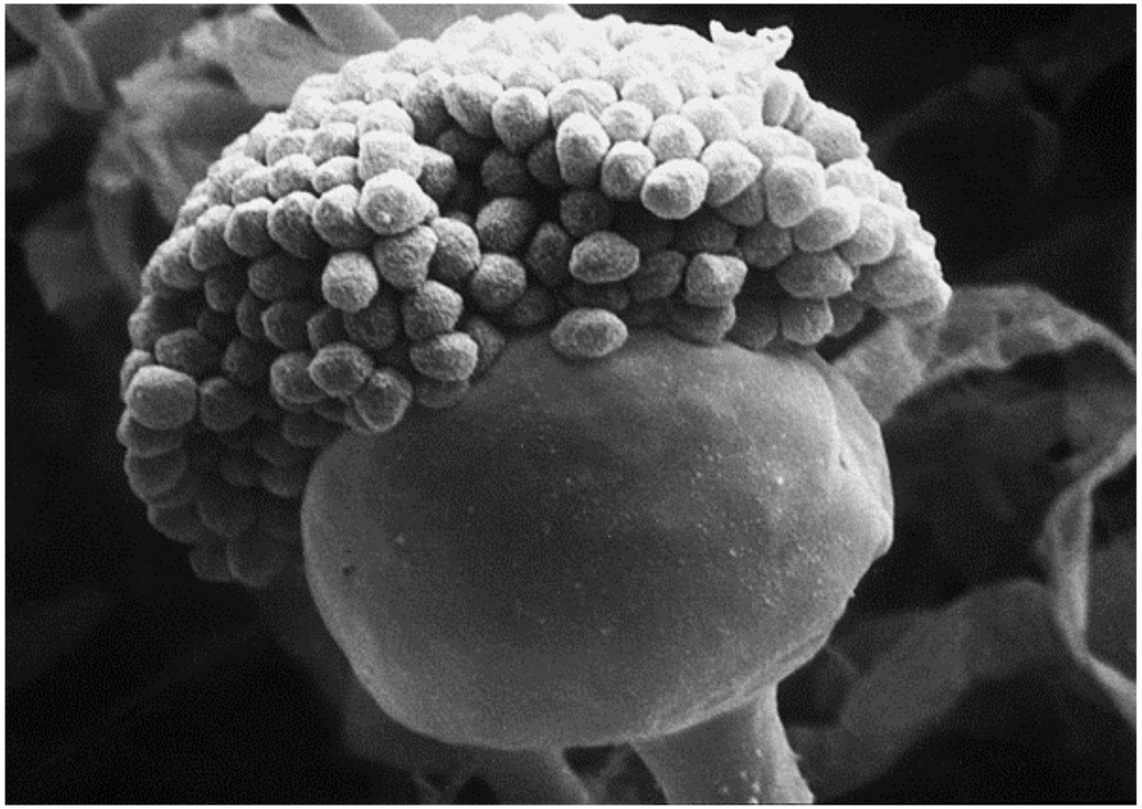

Zoom In | Zoom Out | Reset | Add To New Card | Existing Card

Microbiology | Nervous System | Meningitis

Block Time Remaining: 00:00:30
TUTOR

7 | Feedback | Suspend | End Block

Settings

1 2 3 4 5 6 7 8 9 10 11 12 13 14 15 16 17 18 19 20 21 22 23 24 25 26 27 28 29 30

Item 8 of 38
Question Id: 8324

Mark | Previous | Next | Full Screen | Tutorial | Lab Values | Notes | Calculator | Reverse Color | Text Zoom | Settings

A 32-year-old man is brought to the emergency department due to fever, agitation, and disorientation. According to his family, the patient has been acting strangely and seeing and hearing things that do not exist. He also drools excessively and has severe, painful throat spasms when he attempts to eat or drink. The patient returned 4 weeks ago from a camping trip in New Mexico. Physical examination shows a confused and combative patient with mydriasis and neck rigidity. Which of the following acts as an entry receptor for the causative agent of this patient's condition?

A. B-lymphocyte CD21

B. Muscle acetylcholine receptors

C. Nasopharyngeal intracellular adhesion molecule-1

D. Respiratory epithelial sialic acids

E. Vascular endothelial integrins

Submit

Block Time Remaining: 00:00:30
TUTOR

4 | Feedback | Suspend | End Block

A 32-year-old man is brought to the emergency department due to fever, agitation, and disorientation. According to his family, the patient has been acting strangely and seeing and hearing things that do not exist. He also drools excessively and has severe, painful throat spasms when he attempts to eat or drink. The patient returned 4 weeks ago from a camping trip in New Mexico. Physical examination shows a confused and combative patient with mydriasis and neck rigidity. Which of the following acts as an entry receptor for the causative agent of this patient's condition?

- A. B-lymphocyte CD21 (3%)
- ✓ B. Muscle acetylcholine receptors (61%)
- C. Nasopharyngeal intracellular adhesion molecule-1 (16%)
- D. Respiratory epithelial sialic acids (9%)
- E. Vascular endothelial integrins (10%)

Omitted
Correct answer
B

61%
Answered correctly

02 secs
Time Spent

03/15/2020
Last Updated

Explanation

Virion	Cellular receptor
Cytomegalovirus	Cellular integrins
Epstein-Barr virus	CR2 (CD21)

Virion	Cellular receptor
Cytomegalovirus	Cellular integrins
Epstein-Barr virus	CR2 (CD21)
HIV	CD4 and CXCR4/CCR5
Rabies virus	Nicotinic acetylcholine receptor
Rhinovirus	ICAM1 (CD54)

ICAM1 = intracellular adhesion molecule-1.

This patient's progressive agitation, disorientation, and pharyngospasm raises strong suspicion for **rabies**, a fatal infection caused by a neurotrophic virus from the **Rhabdoviridae** family. Exposure usually occurs when patients come into contact with **contaminated saliva** from an infected animal (eg, dog, bat), which likely occurred during this patient's camping trip in New Mexico. The virus contains a bullet-shaped envelope with knob-like glycoproteins that allow it to attach to the **nicotinic acetylcholine receptor** at the neuromuscular junction. The virus replicates locally within the muscle tissue of the bite wound for several days or weeks and then travels in a retrograde fashion through peripheral nerve axons to the dorsal root ganglia. From there, it rapidly ascends the spinal cord and infects the diencephalon, hippocampus, and brain stem.

Patients initially develop a nonspecific flu-like prodrome (fever, malaise, myalgias); paresthesias radiating proximally from a known wound site can be an important clue. When the virus enters the CNS, the infection typically evolves into rabies encephalitis, which is characterized by painful **pharyngeal spasms** leading to avoidance of water (**hydrophobia**), mental status changes, muscular rigidity, and autonomic dysfunction (pupil dilation, **hypersalivation**). Once symptoms of rabies encephalitis appear, postexposure prophylaxis is no longer effective and nearly all patients die.

(Choice A) Epstein-Barr virus binds to CD21 on inactive B-lymphocytes and results in infectious mononucleosis, which is usually characterized by sore throat, swollen lymph nodes, malaise, and atypical lymphocytosis. Because this virus is a member of the Herpesviridae family, initial infection is followed by a long-standing (usually asymptomatic) latent infection.

(Choice C) Rhinovirus binds intracellular adhesion molecule-1, which is found on nasopharyngeal and adenoid epithelial cells. It is associated

This patient's progressive agitation, disorientation, and pharyngospasm raises strong suspicion for **rabies**, a fatal infection caused by a neurotrophic virus from the **Rhabdoviridae** family. Exposure usually occurs when patients come into contact with **contaminated saliva** from an infected animal (eg, dog, bat), which likely occurred during this patient's camping trip in New Mexico. The virus contains a bullet-shaped envelope with knob-like glycoproteins that allow it to attach to the **nicotinic acetylcholine receptor** at the neuromuscular junction. The virus replicates locally within the muscle tissue of the bite wound for several days or weeks and then travels in a retrograde fashion through peripheral nerve axons to the dorsal root ganglia. From there, it rapidly ascends the spinal cord and infects the diencephalon, hippocampus, and brain stem.

Patients initially develop a nonspecific flu-like prodrome (fever, malaise, myalgias); paresthesias radiating proximally from a known wound site can be an important clue. When the virus enters the CNS, the infection typically evolves into rabies encephalitis, which is characterized by painful **pharyngeal spasms** leading to avoidance of water (**hydrophobia**), mental status changes, muscular rigidity, and autonomic dysfunction (pupil dilation, **hypersalivation**). Once symptoms of rabies encephalitis appear, postexposure prophylaxis is no longer effective and nearly all patients die.

(Choice A) Epstein-Barr virus binds to CD21 on inactive B-lymphocytes and results in infectious mononucleosis, which is usually characterized by sore throat, swollen lymph nodes, malaise, and atypical lymphocytosis. Because this virus is a member of the Herpesviridae family, initial infection is followed by a long-standing (usually asymptomatic) latent infection.

(Choice C) Rhinovirus binds intracellular adhesion molecule-1, which is found on nasopharyngeal and adenoid epithelial cells. It is associated with the common cold, not agitation, pharyngeal spasm, and hallucinations.

(Choice D) The influenza virus has hemagglutinin glycoproteins that allow it to attach to sialic acids on the surface of the respiratory epithelium. Influenza is usually characterized by fever, myalgias, cough, headache, and respiratory symptoms; agitation and pharyngeal spasm are not typical features.

(Choice E) Cytomegalovirus binds to vascular endothelial integrins, leading to replication within endothelial cells. Initial cytomegalovirus infections are often asymptomatic, but patients can develop a mononucleosis-type syndrome (eg, lethargy, fever, atypical lymphocytosis). Psychosis and disorientation would be atypical.

Educational objective:
Rabies virus has a bullet-shaped envelope with knob-like glycoproteins that bind to nicotinic acetylcholine receptors. Once transmission occurs

(Choice A) Epstein-Barr virus binds to CD21 on inactive B-lymphocytes and results in infectious mononucleosis, which is usually characterized by sore throat, swollen lymph nodes, malaise, and atypical lymphocytosis. Because this virus is a member of the Herpesviridae family, initial infection is followed by a long-standing (usually asymptomatic) latent infection.

(Choice C) Rhinovirus binds intracellular adhesion molecule-1, which is found on nasopharyngeal and adenoid epithelial cells. It is associated with the common cold, not agitation, pharyngeal spasm, and hallucinations.

(Choice D) The influenza virus has hemagglutinin glycoproteins that allow it to attach to sialic acids on the surface of the respiratory epithelium. Influenza is usually characterized by fever, myalgias, cough, headache, and respiratory symptoms; agitation and pharyngeal spasm are not typical features.

(Choice E) Cytomegalovirus binds to vascular endothelial integrins, leading to replication within endothelial cells. Initial cytomegalovirus infections are often asymptomatic, but patients can develop a mononucleosis-type syndrome (eg, lethargy, fever, atypical lymphocytosis). Psychosis and disorientation would be atypical.

Educational objective:
Rabies virus has a bullet-shaped envelope with knob-like glycoproteins that bind to nicotinic acetylcholine receptors. Once transmission occurs (usually due to a bite wound from an infected animal), the virus replicates locally in muscle tissue for several days or weeks before spreading in a retrograde fashion through the peripheral nerve axons to the central nervous system.

References

- The acetylcholine receptor as a cellular receptor for rabies virus.
- Rabies virus binding to the nicotinic acetylcholine receptor alpha subunit demonstrated by virus overlay protein binding assay.

Microbiology	Nervous System	Rabies
Subject	System	Topic

Copyright © UWorld. All rights reserved.

A 22-year-old woman is brought to the emergency department due to a day of fever, headaches, nausea, vomiting, and myalgias that began suddenly last night. This morning, the patient was lethargic, difficult to arouse, and confused. She is an exchange student who came to the United States 3 months ago, and her medical history is unknown. Temperature is 39.4 C (102.9 F), blood pressure is 100/60 mm Hg, pulse is 112/min, and respirations are 18/min. Physical examination shows nuchal rigidity. Skin examination findings are shown in the image.

Leukocyte count is elevated, and lumbar puncture with cerebrospinal fluid Gram stain establishes the diagnosis. Which of the following is the primary component of the vaccine that could have prevented this patient's current condition?

- A. Capsular polysaccharide
- B. Inactivated (killed) organisms

Leukocyte count is elevated, and lumbar puncture with cerebrospinal fluid Gram stain establishes the diagnosis. Which of the following is the primary component of the vaccine that could have prevented this patient's current condition?

- A. Capsular polysaccharide
- B. Inactivated (killed) organisms
- C. Inactivated toxic compounds
- D. Live attenuated organisms
- E. Virus-like particles

Submit

1 2 3 4 5 6 7 8 9 10 11 12 13 14 15 16 17 18 19 20 21 22 23 24 25 26 27 28 29 30

Leukocyte count is elevated, and lumbar puncture with cerebrospinal fluid Gram stain establishes the diagnosis. Which of the following is the primary component of the vaccine that could have prevented this patient's current condition?

- ✓ A. Capsular polysaccharide (85%)
- B. Inactivated (killed) organisms (5%)
- C. Inactivated toxic compounds (2%)
- D. Live attenuated organisms (5%)
- E. Virus-like particles (0%)

Omitted
Correct answer

85%
Answered correctly

07 secs
Time Spent

04/10/2020
Last Updated

Explanation

Vaccine types		
Live-attenuated vaccines	**Non-live (toxoid, subunit, conjugate, inactivated) vaccines**	
• Polio (oral)*	• Influenza (intramuscular)	• Human papillomavirus
• Measles/mumps/rubella	• Pneumococcus	• Meningococcus
• Rotavirus	• Diphtheria/tetanus/pertussis	
• Influenza (intranasal)	• Polio (inactivated)	
• Yellow fever	• Hepatitis A	
• Varicella, zoster	• Hepatitis B	
	• *Haemophilus influenzae* type b	

*Not available in the United States; advised only for developing countries.

This patient's rapid-onset headache, fever, altered mental status, nuchal rigidity, and purpuric rash raise strong suspicion for **meningococcal meningitis**. *Neisseria meningitidis* is a gram-negative diplococcus transmitted via aerosolized respiratory droplets. Close living conditions (eg, college **dormitories**, prisons, military barracks) promote its spread. *N meningitidis* has several virulence factors, including a polysaccharide capsule (impairs phagocytosis of the bacteria), lipo-oligosaccharide (induces cytokine production, leading to circulatory collapse), pili (permit bacterial attachment to the respiratory mucosa), and IgA protease (cleaves secretory IgA that would otherwise inactivate the pili). Antibodies against the **polysaccharide capsule** confer immunity to *N meningitidis*.

The meningococcal **vaccines** available in the United States are as follows:

- **Quadrivalent conjugate vaccine: Capsular polysaccharide antigens** (serogroups A, C, Y, and W) are fused to a diphtheroid toxin carrier, which allows the polysaccharides to be displayed on the major histocompatibility complex of antigen-presenting cells. This results in the stimulation of T-cells and provides a stronger, more lasting immunologic response.
- **Serogroup B vaccine:** Capsular polysaccharides from serogroup B are very similar to human neural cell adhesion molecules. This

*Not available in the United States; advised only for developing countries.

This patient's rapid-onset headache, fever, altered mental status, nuchal rigidity, and purpuric rash raise strong suspicion for **meningococcal meningitis**. *Neisseria meningitidis* is a gram-negative diplococcus transmitted via aerosolized respiratory droplets. Close living conditions (eg, college **dormitories**, prisons, military barracks) promote its spread. *N meningitidis* has several virulence factors, including a polysaccharide capsule (impairs phagocytosis of the bacteria), lipo-oligosaccharide (induces cytokine production, leading to circulatory collapse), pili (permit bacterial attachment to the respiratory mucosa), and IgA protease (cleaves secretory IgA that would otherwise inactivate the pili). Antibodies against the **polysaccharide capsule** confer immunity to *N meningitidis*.

The meningococcal **vaccines** available in the United States are as follows:

- **Quadrivalent conjugate vaccine: Capsular polysaccharide antigens** (serogroups A, C, Y, and W) are fused to a diphtheroid toxin carrier, which allows the polysaccharides to be displayed on the major histocompatibility complex of antigen-presenting cells. This results in the stimulation of T-cells and provides a stronger, more lasting immunologic response.
- **Serogroup B vaccine:** Capsular polysaccharides from serogroup B are very similar to human neural cell adhesion molecules. This molecular mimicry prevented a polysaccharide vaccine due to difficulty in generating an immune response without increasing the risk of autoimmunity. A vaccine against this serogroup is now available that uses recombinant proteins instead of capsular polysaccharides.

In the United States, the quadrivalent vaccine is part of routine immunizations; the serogroup B vaccine is recommended for specific high-risk populations (eg, those with asplenia or complement deficiency).

(Choice B) The influenza vaccination typically contains three or four strains of inactivated virus. Although influenza is often associated with rapid-onset malaise, headache, myalgia, and fever, the presence of nuchal rigidity and purpuric skin rash make meningococcemia more likely.

(Choice C) The diphtheria toxoid is used as protein carrier in conjugate vaccines because it allows the polysaccharide antigen to be displayed on the major histocompatibility complex of antigen presenting cells. The toxoid is not the primary component of conjugate vaccines.

(Choice D) The measles-mumps-rubella vaccination contains live attenuated versions of these viruses. Measles is associated with the 3 C's (coryza, conjunctivitis, cough) and a maculopapular rash, mumps is associated with salivary gland swelling, and rubella is associated with a diffuse maculopapular rash. A purpuric rash and nuchal rigidity would be atypical.

autoimmunity. A vaccine against this serogroup is now available that uses recombinant proteins instead of capsular polysaccharides.

In the United States, the quadrivalent vaccine is part of routine immunizations; the serogroup B vaccine is recommended for specific high-risk populations (eg, those with asplenia or complement deficiency).

(Choice B) The influenza vaccination typically contains three or four strains of inactivated virus. Although influenza is often associated with rapid-onset malaise, headache, myalgia, and fever, the presence of nuchal rigidity and purpuric skin rash make meningococcemia more likely.

(Choice C) The diphtheria toxoid is used as protein carrier in conjugate vaccines because it allows the polysaccharide antigen to be displayed on the major histocompatibility complex of antigen presenting cells. The toxoid is not the primary component of conjugate vaccines.

(Choice D) The measles-mumps-rubella vaccination contains live attenuated versions of these viruses. Measles is associated with the 3 C's (coryza, conjunctivitis, cough) and a maculopapular rash, mumps is associated with salivary gland swelling, and rubella is associated with a diffuse maculopapular rash. A purpuric rash and nuchal rigidity would be atypical.

(Choice E) Virus-like particles are multiprotein structures that illicit a strong B- and T-cell response but contain no viral genetic material, so they are not infectious. Virus-like particles are used in the hepatitis B and human papillomavirus vaccines.

Educational objective:
Antibodies against the polysaccharide capsule of *Neisseria meningitidis* provide immunity against this pathogen. Quadrivalent meningococcal vaccines contain capsular polysaccharides from major serotypes (A, C, Y, and W) of *N meningitidis*. Serotype B vaccinations use recombinant proteins.

References

- Meningococcal vaccinations.

Microbiology	Nervous System	Meningitis
Subject	System	Topic

Copyright © UWorld. All rights reserved.

Settings

1
2
3
4
5
6
7
8
9
10
11
12
13
14
15
16
17
18
19
20
21
22
23
24
25
26
27
28
29
30

Item 9 of 38
Question Id: 1853

Mark | Previous | Next | Full Screen | Tutorial | Lab Values | Notes | Calculator | Reverse Color | Text Zoom | Settings

Exhibit Display

Zoom In | Zoom Out | Reset | Add To New Card | Existing Card

Block Time Remaining: 00:00:39
TUTOR

6 | Feedback | Suspend | End Block

Settings

1
2
3
4
5
6
7
8
9
10
11
12
13
14
15
16
17
18
19
20
21
22
23
24
25
26
27
28
29
30

Item 9 of 38
Question Id: 1853

Mark | Previous | Next | Full Screen | Tutorial | Lab Values | Notes | Calculator | Reverse Color | Text Zoom | Settings

Exhibit Display

Zoom In | Zoom Out | Reset | Add To New Card | Existing Card

Block Time Remaining: 00:00:39
TUTOR

6 | Feedback | Suspend | End Block

A 23-year-old woman is evaluated due to 10 days of nonproductive cough, low-grade fever, headache, and malaise. The patient has no other medical problems and takes no medications. Lung examination reveals scattered rales. Chest x-ray reveals bilateral patchy areas of consolidation. She has mild anemia and an elevated serum lactate dehydrogenase level. The patient is treated for presumed *Mycoplasma* pneumonia with azithromycin. Two months later, her symptoms and the anemia have resolved. Which of the following best explains the resolution of this patient's anemia?

A. Elimination of bacterial cell wall antigens

B. Elimination of intraerythrocytic microorganisms

C. Fading of immune response against the bacteria

D. Replenishment of body iron stores

E. Replenishment of intracellular enzyme stores

Submit

A 23-year-old woman is evaluated due to 10 days of nonproductive cough, low-grade fever, headache, and malaise. The patient has no other medical problems and takes no medications. Lung examination reveals scattered rales. Chest x-ray reveals bilateral patchy areas of consolidation. She has mild anemia and an elevated serum lactate dehydrogenase level. The patient is treated for presumed *Mycoplasma* pneumonia with azithromycin. Two months later, her symptoms and the anemia have resolved. Which of the following best explains the resolution of this patient's anemia?

- A. Elimination of bacterial cell wall antigens (8%)
- B. Elimination of intraerythrocytic microorganisms (12%)
- ✓ C. Fading of immune response against the bacteria (59%)
- D. Replenishment of body iron stores (14%)
- E. Replenishment of intracellular enzyme stores (5%)

Omitted
Correct answer
C

59%
Answered correctly

02 secs
Time Spent

03/08/2020
Last Updated

Explanation

Cold agglutinin disease		Warm agglutinin disease	
Infection (eg, *Mycoplasma pneumoniae*)	Hematologic malignancies	Medications	SLE, CLL

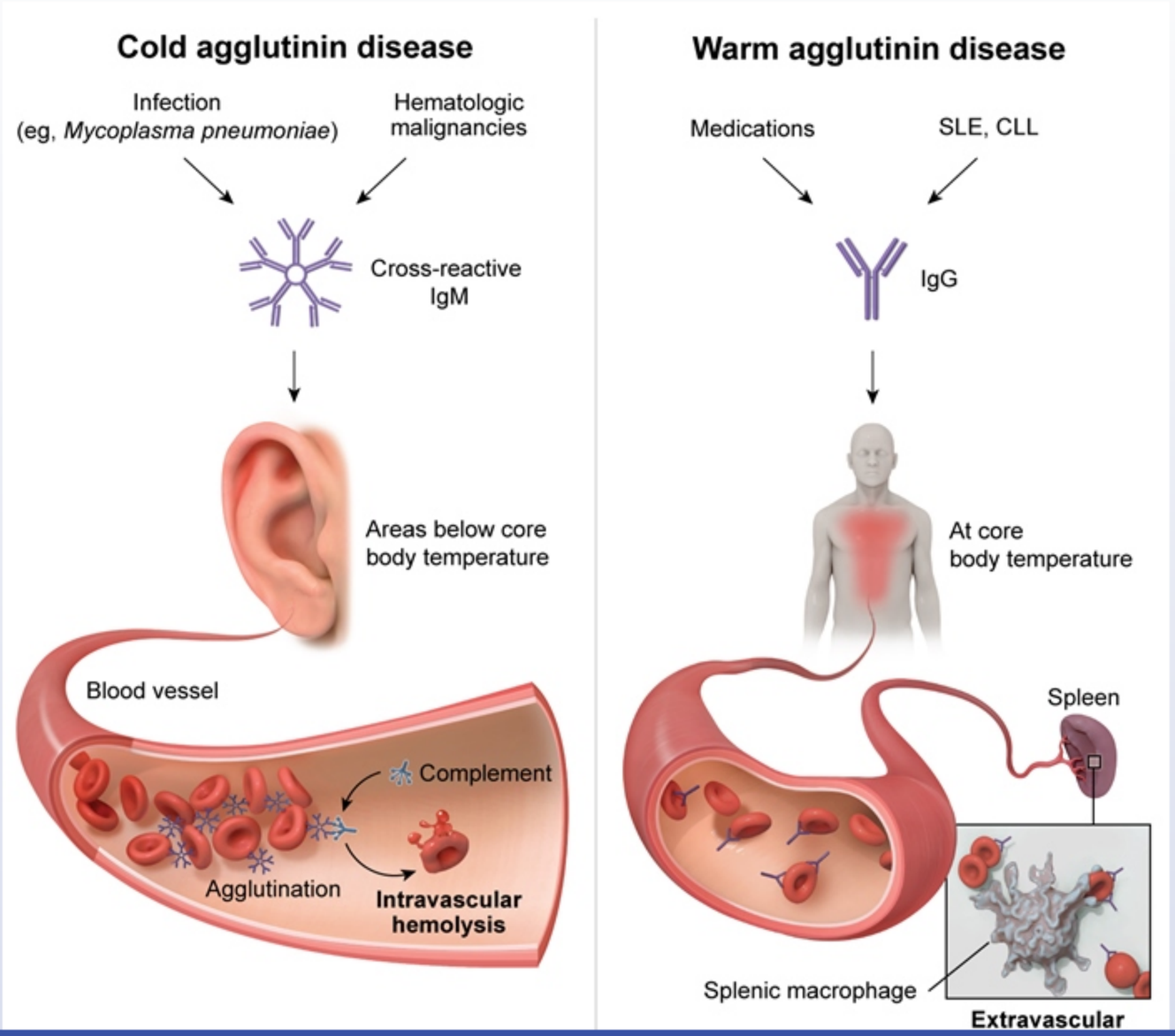
Cold agglutinin disease
Infection
(eg, Mycoplasma pneumoniae)
Hematologic malignancies
Cross-reactive IgM
Areas below core body temperature
Blood vessel
Complement
Agglutination
Intravascular hemolysis
Warm agglutinin disease
Medications
SLE, CLL
IgG
At core body temperature
Spleen
Splenic macrophage
Extravascular

Mycoplasma pneumoniae is a common cause of tracheobronchitis and walking pneumonia. It attacks the respiratory epithelium by binding to an oligosaccharide (**I-antigen**) that is also present on the surface of erythrocytes. This leads to the formation of **cross-reacting IgM antibodies** that attach to red blood cells, activate the complement system, and cause erythrocyte lysis.

The cross-reacting antibodies are called **cold agglutinins** because they bind to erythrocytes in areas where the blood temperature is below core body temperature (eg, distal extremities, nose). Most patients with cold agglutinins are asymptomatic, but some develop manifestations of intravascular **hemolytic anemia** such as elevated reticulocyte count and lactate dehydrogenase level. IgM titers usually begin to fall approximately 4 weeks after initial infection leading to a resolution of the hemolytic anemia (within 8 weeks).

Other extrapulmonary manifestations of *M pneumoniae* include Stevens-Johnson syndrome, joint pain, encephalitis, cardiac rhythm disturbances, and bullous myringitis.

(Choice A) *M pneumoniae* is an atypical bacterium; it has a plasma membrane composed of cholesterol (unlike most bacteria) and no cell wall. The lack of a cell wall makes this pathogen resistant to beta-lactam antibiotics.

(Choice B) Malaria and babesiosis are associated with intraerythrocytic organisms that can cause cell lysis and anemia. However, these pathogens usually cause high fever and more severe clinical syndromes. In addition, azithromycin monotherapy is not an effective cure for these infections.

(Choice D) Iron deficiency anemia, which is most commonly due to blood loss, can often be improved by replenishing body iron stores (eg, oral iron supplementation). Chronic infection or inflammatory conditions can be associated with anemia of chronic disease, which is due to impaired utilization of iron (not absolute iron deficiency).

(Choice E) Enzyme deficiencies that cause anemia include glucose-6-phosphate dehydrogenase (G6PD) deficiency and pyruvate kinase deficiency. Infection and medications that cause oxidative stress (eg, sulfonamides, antimalarial agents) can cause hemolysis in patients with G6PD; however, G6PD is an X-linked disorder (it is seen in men).

Educational objective:
Mycoplasma pneumoniae binds an oligosaccharide on the respiratory epithelium that is also present on erythrocytes, leading to the generation of cross-reacting IgM antibodies (cold agglutinins). Patients with *M pneumoniae* infections often develop mild, transient hemolytic anemia that

intravascular **hemolytic anemia** such as elevated reticulocyte count and lactate dehydrogenase level. IgM titers usually begin to fall approximately 4 weeks after initial infection leading to a resolution of the hemolytic anemia (within 8 weeks).

Other extrapulmonary manifestations of *M pneumoniae* include Stevens-Johnson syndrome, joint pain, encephalitis, cardiac rhythm disturbances, and bullous myringitis.

(Choice A) *M pneumoniae* is an atypical bacterium; it has a plasma membrane composed of cholesterol (unlike most bacteria) and no cell wall. The lack of a cell wall makes this pathogen resistant to beta-lactam antibiotics.

(Choice B) Malaria and babesiosis are associated with intraerythrocytic organisms that can cause cell lysis and anemia. However, these pathogens usually cause high fever and more severe clinical syndromes. In addition, azithromycin monotherapy is not an effective cure for these infections.

(Choice D) Iron deficiency anemia, which is most commonly due to blood loss, can often be improved by replenishing body iron stores (eg, oral iron supplementation). Chronic infection or inflammatory conditions can be associated with anemia of chronic disease, which is due to impaired utilization of iron (not absolute iron deficiency).

(Choice E) Enzyme deficiencies that cause anemia include glucose-6-phosphate dehydrogenase (G6PD) deficiency and pyruvate kinase deficiency. Infection and medications that cause oxidative stress (eg, sulfonamides, antimalarial agents) can cause hemolysis in patients with G6PD; however, G6PD is an X-linked disorder (it is seen in men).

Educational objective:
Mycoplasma pneumoniae binds an oligosaccharide on the respiratory epithelium that is also present on erythrocytes, leading to the generation of cross-reacting IgM antibodies (cold agglutinins). Patients with *M pneumoniae* infections often develop mild, transient hemolytic anemia that resolves as IgM antibody titers decline (6-8 weeks after infection begins).

Microbiology	Hematology & Oncology	Community acquired pneumonia
Subject	System	Topic

Copyright © UWorld. All rights reserved.

A 38-year-old man is brought to the emergency department after a generalized tonic-clonic seizure. He had several days of progressive headache, vomiting, and confusion prior to the episode. Temperature is 38 C (100.4 F). Physical examination shows a lethargic patient with bilateral papilledema and neck rigidity. His condition progressively worsens, and the patient dies in the hospital several days later. An autopsy is performed, and the brain histopathology is shown below.

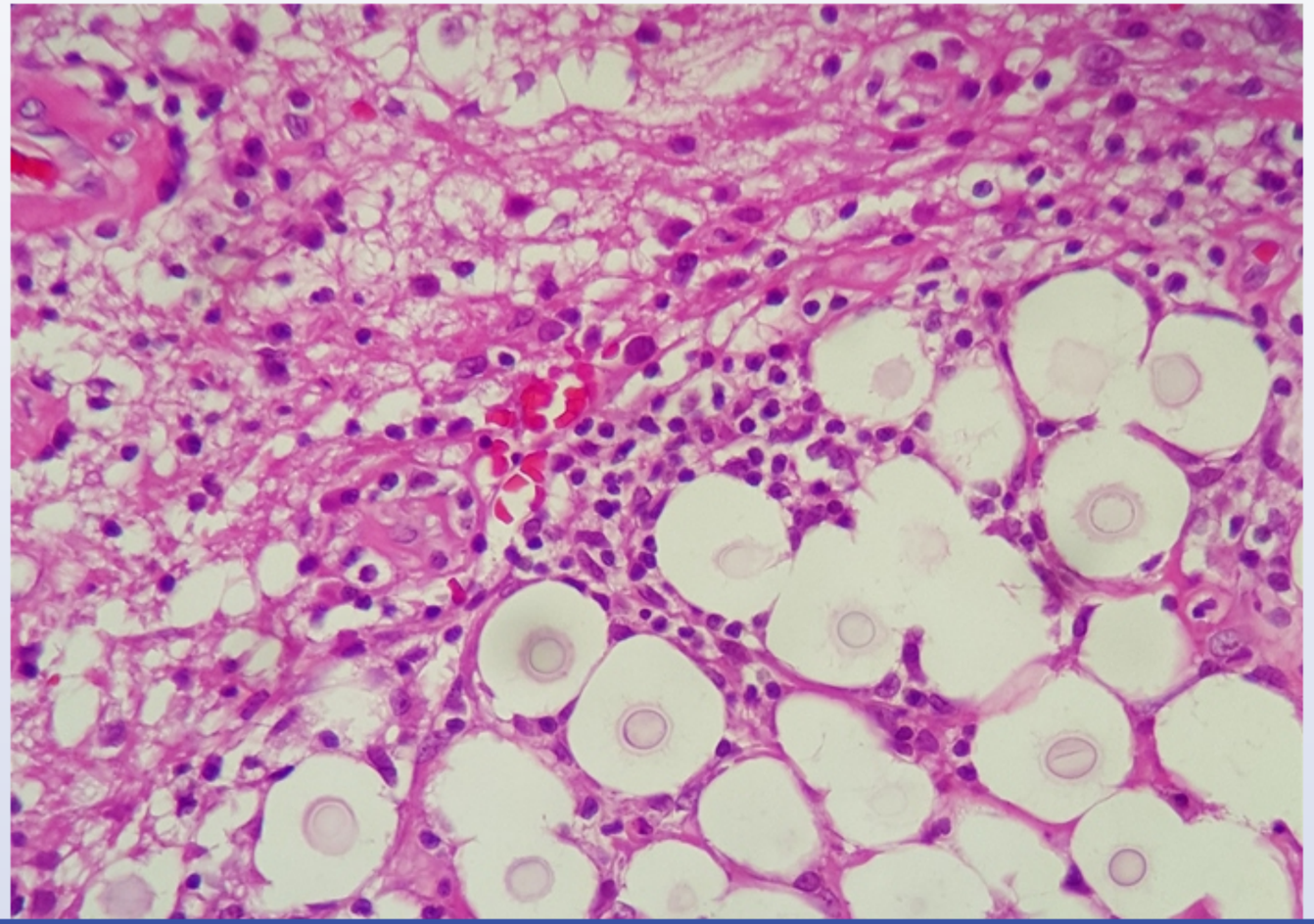

Settings

1
2
3
4
5
6
7
8
9
10
11
12
13
14
15
16
17
18
19
20
21
22
23
24
25
26
27
28
29
30

Item 11 of 38
Question Id: 15580

Mark | Previous | Next | Full Screen | Tutorial | Lab Values | Notes | Calculator | Reverse Color | Text Zoom | Settings

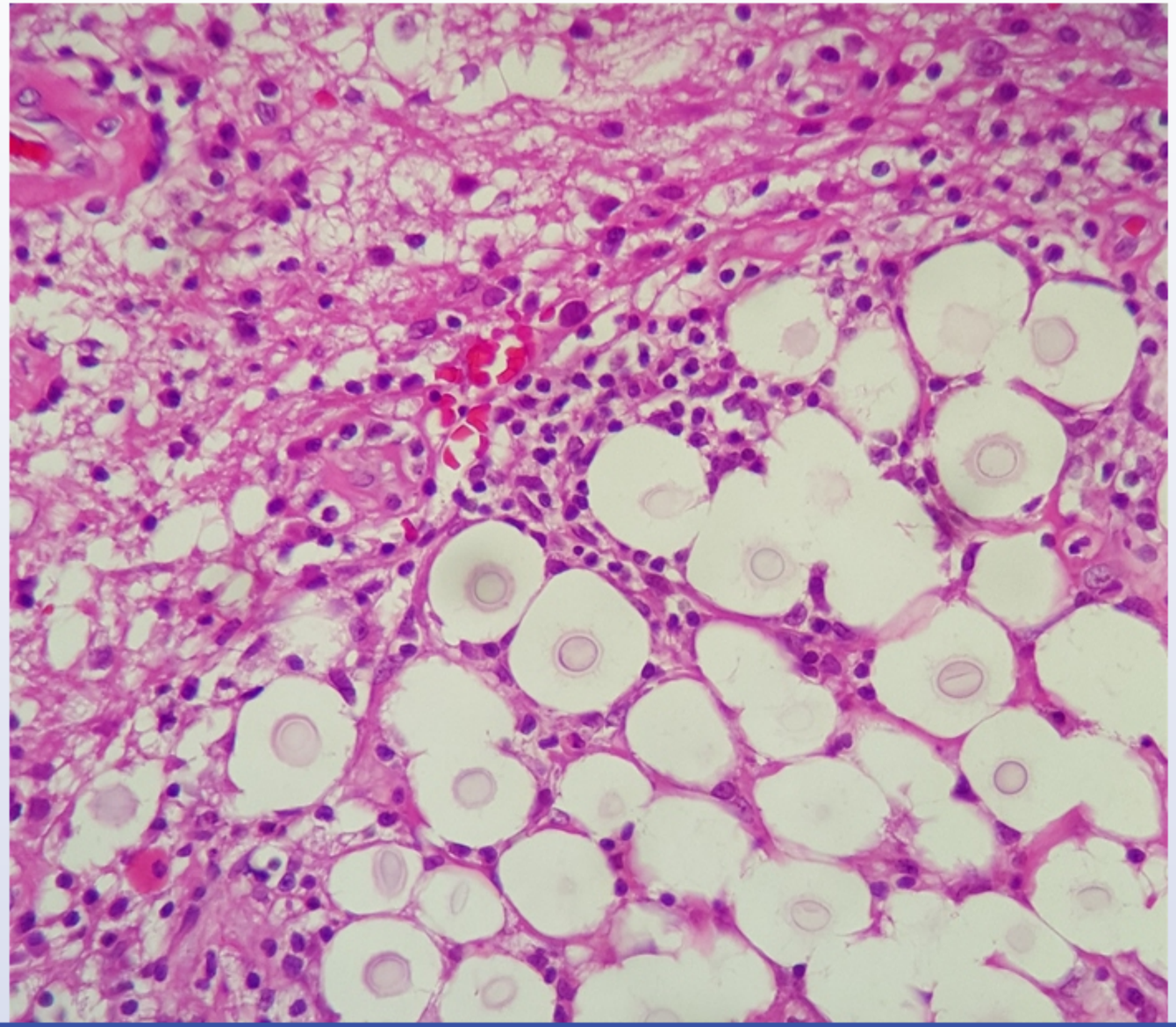

Block Time Remaining: 00:00:46
TUTOR

5 | Feedback | Suspend | End Block

1 2 3 4 5 6 7 8 9 10 11 12 13 14 15 16 17 18 19 20 21 22 23 24 25 26 27 28 29 30

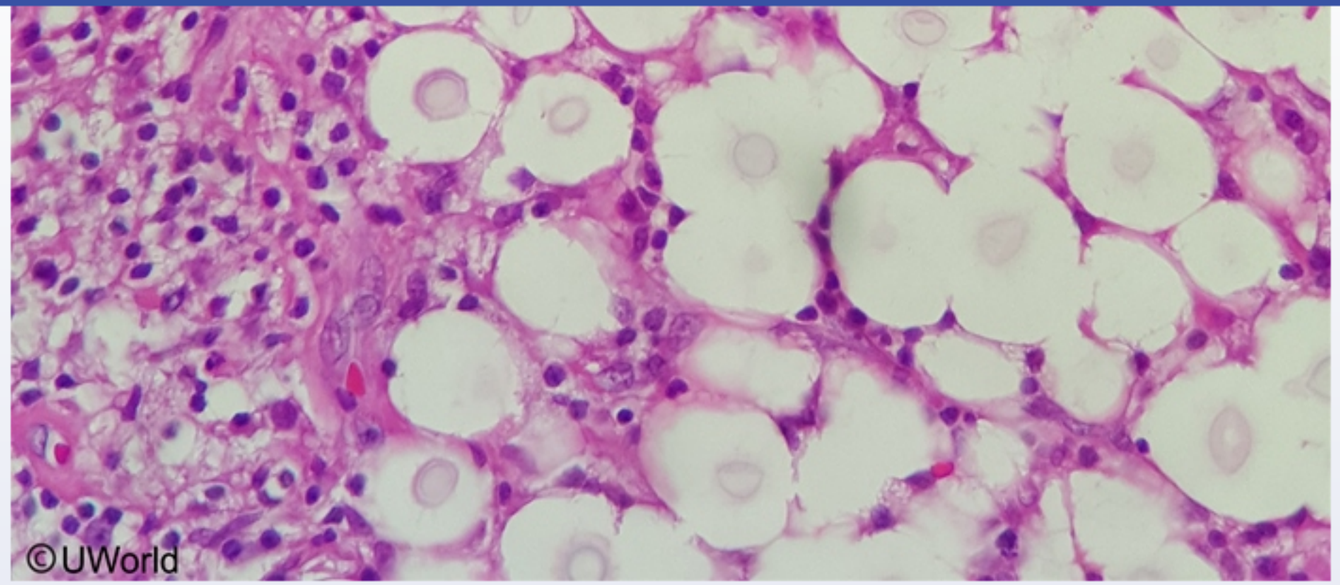

Which of the following pathogens is most likely responsible for these findings?

- A. Bacteria with mycolic acid in cell wall
- B. Infectious agent lacking nucleic acid
- C. Neurotrophic double-stranded DNA virus
- D. Obligate intracellular protozoan parasite
- E. Yeast with polysaccharide capsule

Submit

1 2 3 4 5 6 7 8 9 10 11 12 13 14 15 16 17 18 19 20 21 22 23 24 25 26 27 28 29 30

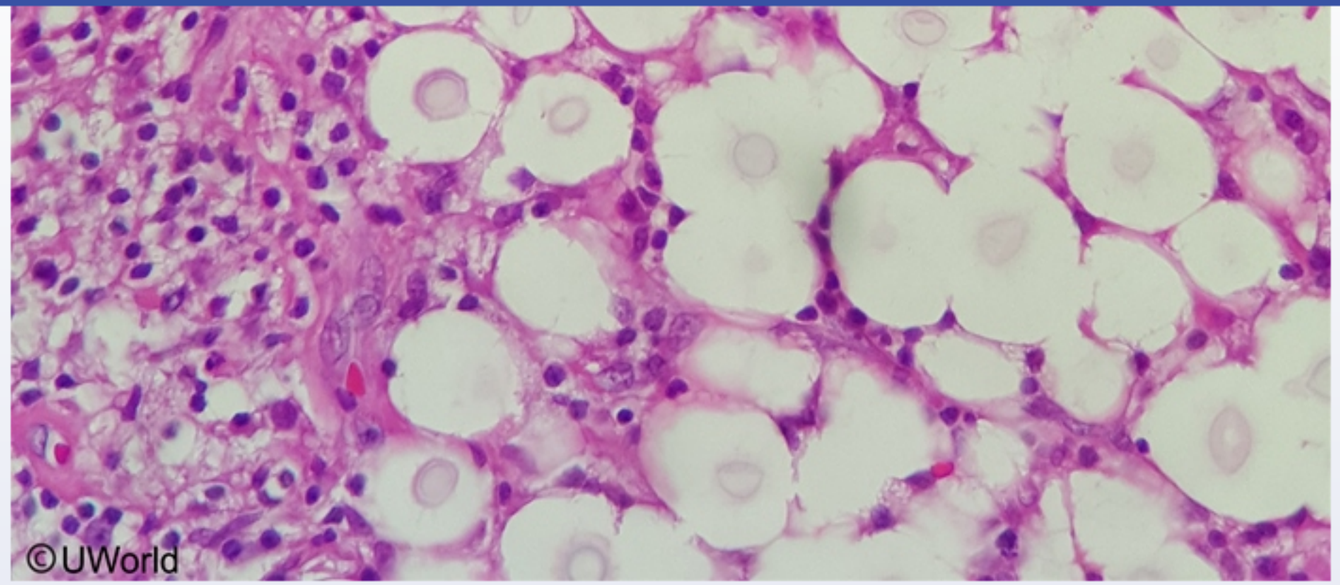

Which of the following pathogens is most likely responsible for these findings?

- A. Bacteria with mycolic acid in cell wall (3%)
- B. Infectious agent lacking nucleic acid (6%)
- C. Neurotrophic double-stranded DNA virus (7%)
- D. Obligate intracellular protozoan parasite (13%)
- ✓ E. Yeast with polysaccharide capsule (68%)

Omitted
Correct answer

68%
Answered correctly

11 secs
Time Spent

02/10/2020
Last Updated

1 2 3 4 5 6 7 8 9 10 11 12 13 14 15 16 17 18 19 20 21 22 23 24 25 26 27 28 29 30

Cryptococcal encephalitis

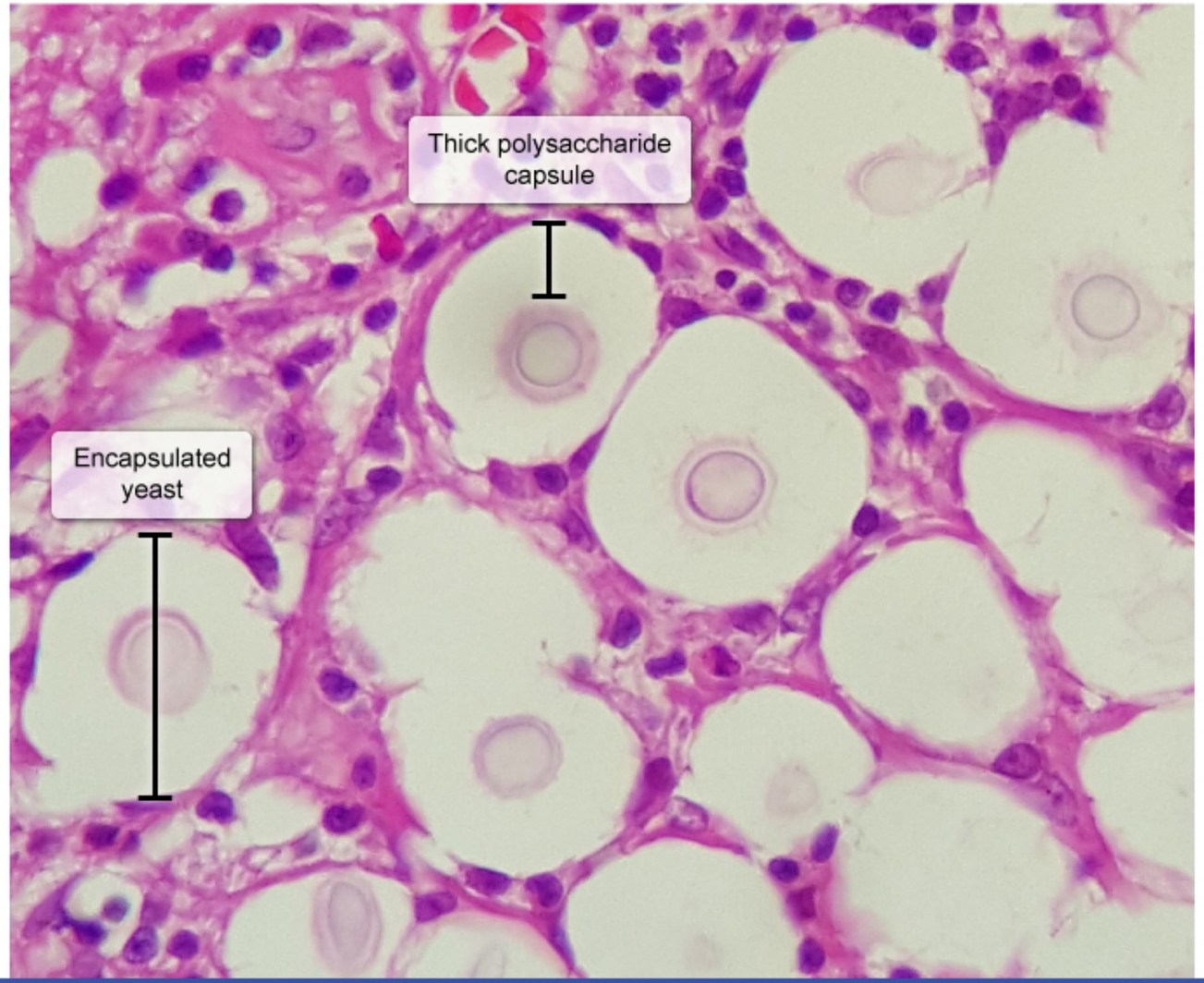

1 2 3 4 5 6 7 8 9 10 11 12 13 14 15 16 17 18 19 20 21 22 23 24 25 26 27 28 29 30

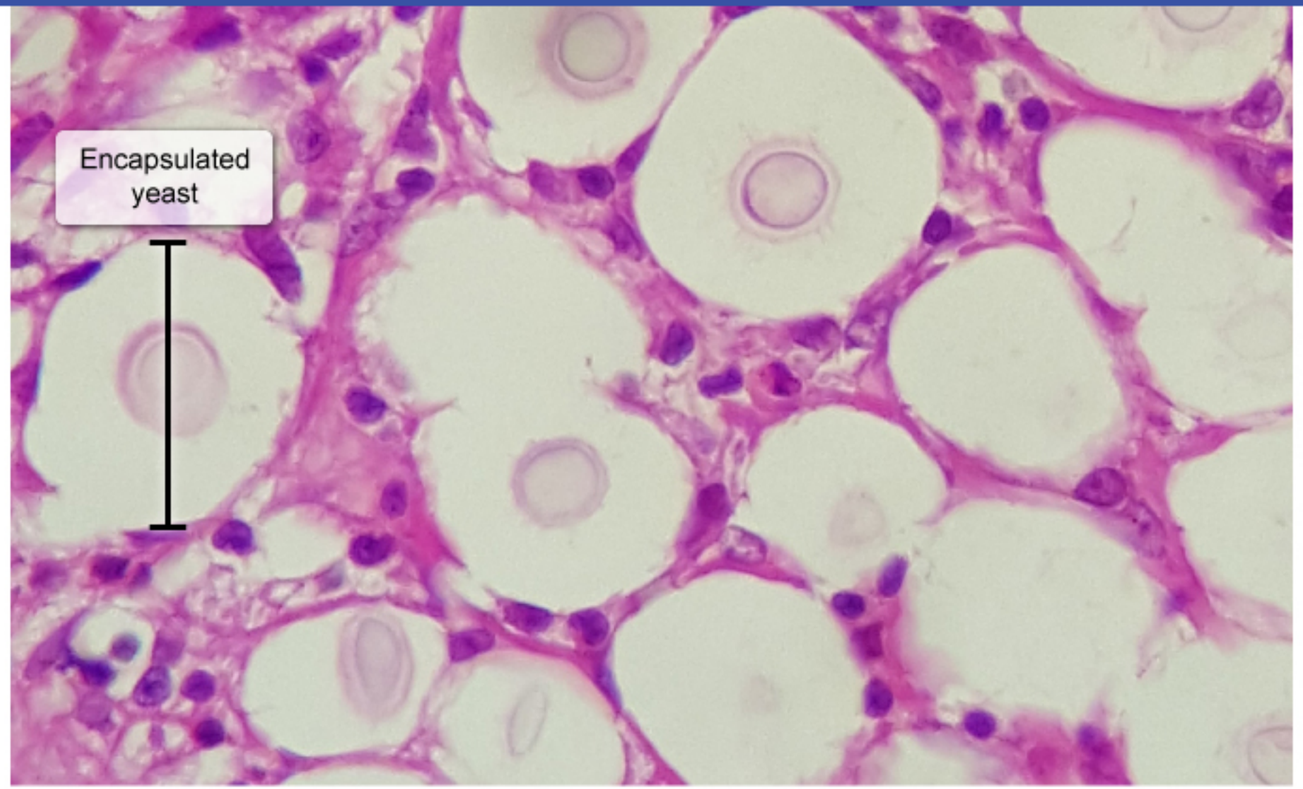

©UWorld

Cryptococcus neoformans, a round/oval yeast surrounded by a **thick polysaccharide capsule** (clear areas on H&E tissue stain shown above), is found primarily in soil contaminated by bird droppings and is transmitted to humans via inhalation. Healthy individuals control/eliminate the infection with the cell-mediated immune response and are rarely symptomatic. However, those with compromised immunity, particularly **advanced AIDS**, cannot contain the infection and often develop hematologic dissemination to the brain (**cryptococcal meningitis**).

Replication of *C neoformans* in the brain clogs the arachnoid villi with yeast antigens and capsular proteins, leading to obstructed cerebrospinal fluid outflow. This **elevates intracranial pressure** and causes slowly progressive headache, nausea and vomiting, confusion, neck rigidity, and papilledema. Seizures and brain herniation can subsequently occur.

©UWorld

Cryptococcus neoformans, a round/oval yeast surrounded by a **thick polysaccharide capsule** (clear areas on H&E tissue stain shown above), is found primarily in soil contaminated by bird droppings and is transmitted to humans via inhalation. Healthy individuals control/eliminate the infection with the cell-mediated immune response and are rarely symptomatic. However, those with compromised immunity, particularly **advanced AIDS**, cannot contain the infection and often develop hematologic dissemination to the brain (**cryptococcal meningitis**).

Replication of *C neoformans* in the brain clogs the arachnoid villi with yeast antigens and capsular proteins, leading to obstructed cerebrospinal fluid outflow. This **elevates intracranial pressure** and causes slowly progressive headache, nausea and vomiting, confusion, neck rigidity, and papilledema. Seizures and brain herniation can subsequently occur.

The diagnosis is typically confirmed by detection of **cryptococcal antigens** in cerebrospinal fluid (CSF) or visualization of encapsulated, budding yeasts in CSF using specialized stains (eg, India ink, methenamine silver); these special stains are needed as the yeasts are surrounded by clear CSF (unlike in tissue sections). Patients who develop cryptococcal meningitis often are unaware of underlying HIV infection (as is likely in this case); it is considered an AIDS-defining illness.

(Choice A) Mycolic acid is the primary component of the cell wall of *Mycobacterium tuberculosis*. Although pulmonary infection is most common, *M tuberculosis* can spread to the brain and cause subacute meningitis or a focal parenchymal infection called a tuberculoma. Histopathology would show granulomas with giant cells and acid-fast bacteria.

(Choice B) Prions, infectious proteins that lack nucleic acid, can cause Creutzfeldt-Jakob disease. Most cases are marked by rapidly progressive dementia and startle myoclonus. Histopathology typically reveals brain atrophy, spongiform vacuoles, and the accumulation of prions in neuronal tissue.

(Choice C) Herpes simplex virus is a neurotrophic, double-stranded DNA virus that can spread through the olfactory tract to the olfactory cortex in the temporal lobe of the brain. Patients usually develop acute fever, headache, confusion, and focal neurologic issues. Histopathology typically reveals hemorrhagic inflammation with an infiltration of mononuclear cells.

(Choice D) *Toxoplasma gondii* is a feline parasite that can cause encephalitis in patients with untreated AIDS. Manifestations include headache, confusion, fever, seizures, and focal neurologic deficits. However, histopathology would reveal *T gondii* cysts, not encapsulated yeasts.

The diagnosis is typically confirmed by detection of **cryptococcal antigens** in cerebrospinal fluid (CSF) or visualization of encapsulated, budding yeasts in CSF using specialized stains (eg, India ink, methenamine silver); these special stains are needed as the yeasts are surrounded by clear CSF (unlike in tissue sections). Patients who develop cryptococcal meningitis often are unaware of underlying HIV infection (as is likely in this case); it is considered an AIDS-defining illness.

(Choice A) Mycolic acid is the primary component of the cell wall of *Mycobacterium tuberculosis*. Although pulmonary infection is most common, *M tuberculosis* can spread to the brain and cause subacute meningitis or a focal parenchymal infection called a tuberculoma. Histopathology would show granulomas with giant cells and acid-fast bacteria.

(Choice B) Prions, infectious proteins that lack nucleic acid, can cause Creutzfeldt-Jakob disease. Most cases are marked by rapidly progressive dementia and startle myoclonus. Histopathology typically reveals brain atrophy, spongiform vacuoles, and the accumulation of prions in neuronal tissue.

(Choice C) Herpes simplex virus is a neurotrophic, double-stranded DNA virus that can spread through the olfactory tract to the olfactory cortex in the temporal lobe of the brain. Patients usually develop acute fever, headache, confusion, and focal neurologic issues. Histopathology typically reveals hemorrhagic inflammation with an infiltration of mononuclear cells.

(Choice D) *Toxoplasma gondii* is a feline parasite that can cause encephalitis in patients with untreated AIDS. Manifestations include headache, confusion, fever, seizures, and focal neurologic deficits. However, histopathology would reveal *T gondii* cysts, not encapsulated yeasts.

Educational objective:
Cryptococcus neoformans is a round/oval yeast with a thick polysaccharide capsule. It is a common cause of meningoencephalitis (eg, headache, vomiting, confusion, seizure) in patients with untreated AIDS. The yeast can frequently be visualized in the cerebrospinal fluid by India ink or silver stain.

Microbiology	Nervous System	Cryptococcal infections
Subject	System	Topic

Copyright © UWorld. All rights reserved.

Settings

1 2 3 4 5 6 7 8 9 10 11 12 13 14 15 16 17 18 19 20 21 22 23 24 25 26 27 28 29 30

Item 11 of 38
Question Id: 15580

Mark | Previous | Next | Full Screen | Tutorial | Lab Values | Notes | Calculator | Reverse Color | Text Zoom | Settings

The diagnosis is typically confirmed by detection of **cryptococcal antigens** in cerebrospinal fluid (CSF) or visualization of encapsulated, budding

Exhibit Display

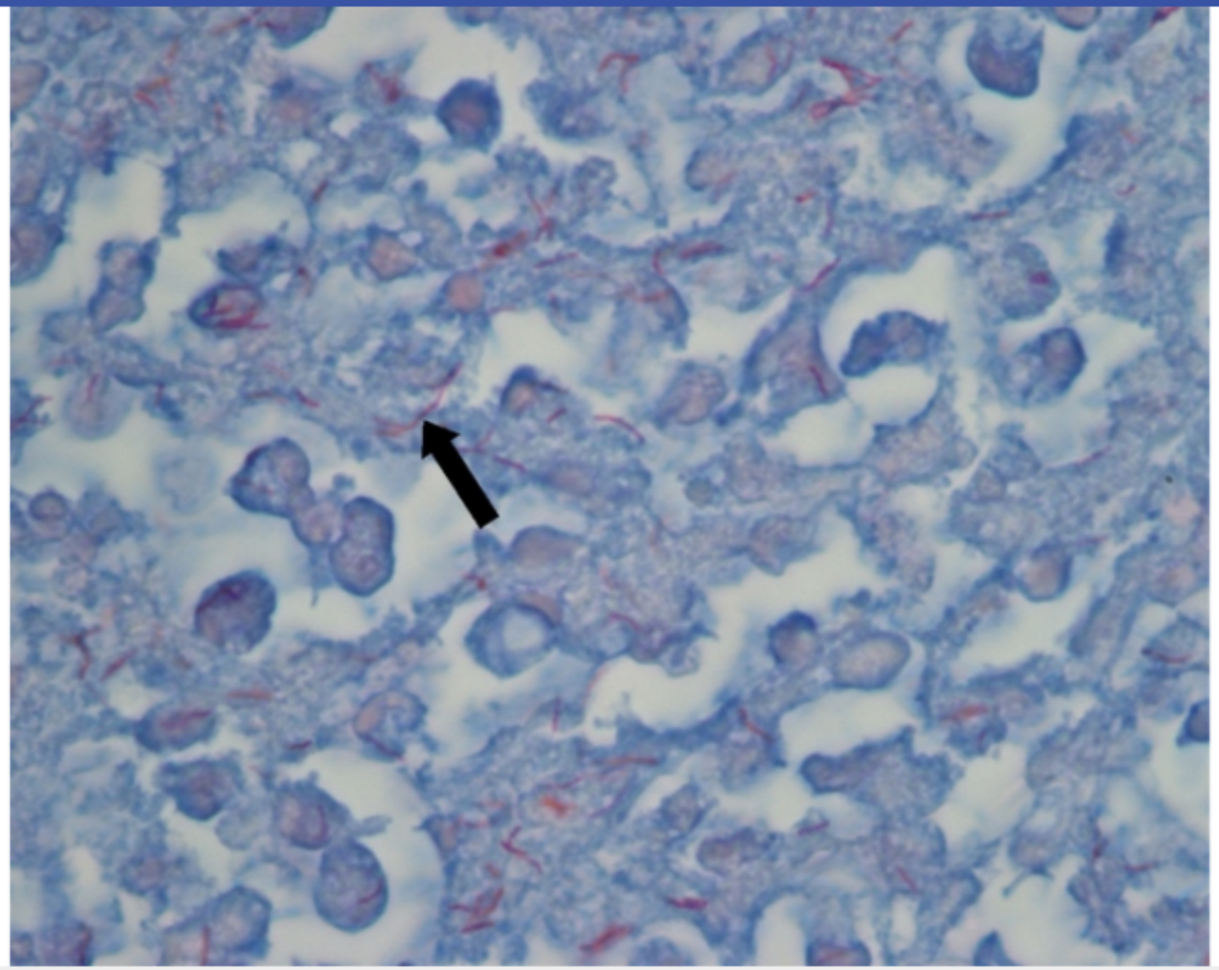

Zoom In | Zoom Out | Reset | Add To New Card | Existing Card

Block Time Remaining: 00:00:52
TUTOR

5 | Feedback | Suspend | End Block

The following vignette applies to the next **2** items. The items in the set must be answered in sequential order. Once you click **Proceed to Next Item**, you will not be able to add or change an answer.

A 29-year-old woman is brought to the emergency department with new-onset generalized tonic-clonic seizures. She has a history of HIV and has not been taking her medications consistently. According to her family, she has been sleepy and weak for the past 2 weeks. She has not had much of an appetite and has recently spent most of her time in bed. MRI of the head demonstrates 2 ring-enhancing focal lesions with surrounding edema in the right frontal lobe.

Item 1 of 2

Which of the following would be effective against the pathogen most likely responsible for this patient's symptoms?

A. Amphotericin B

B. Ampicillin

C. Ganciclovir

D. Isoniazid and rifampin

E. Pyrimethamine and sulfadiazine

Submit

The following vignette applies to the next **2** items. The items in the set must be answered in sequential order. Once you click **Proceed to Next Item**, you will not be able to add or change an answer.

A 29-year-old woman is brought to the emergency department with new-onset generalized tonic-clonic seizures. She has a history of HIV and has not been taking her medications consistently. According to her family, she has been sleepy and weak for the past 2 weeks. She has not had much of an appetite and has recently spent most of her time in bed. MRI of the head demonstrates 2 ring-enhancing focal lesions with surrounding edema in the right frontal lobe.

Item 1 of 2

Which of the following would be effective against the pathogen most likely responsible for this patient's symptoms?

A. Amphotericin B (24%)

B. Ampicillin (1%)

C. Ganciclovir (7%)

D. Isoniazid and rifampin (2%)

✓ E. Pyrimethamine and sulfadiazine (63%)

Omitted
Correct answer
E

63%
Answered correctly

02 secs
Time Spent

02/16/2020
Last Updated

Explanation

Explanation

Toxoplasma gondii is an obligate intracellular protozoan with a worldwide distribution. The cat is the definitive host of this protozoan, with humans infected following ingestion of food or water contaminated with cat feces (containing oocysts) or undercooked meat (containing pseudocysts). Immunocompromised individuals exposed to *T gondii* can develop encephalitis with multiple necrotizing brain lesions, resulting in fever, headache, altered mental status, and focal neurologic findings. In this patient with **HIV** who has **seizures** and **multiple ring-enhancing lesions** with mass effect, **cerebral toxoplasmosis** is a likely diagnosis. First-line treatment (which can be given empirically, particularly if test results are unrevealing) includes a combination of **pyrimethamine and sulfadiazine** (or pyrimethamine and clindamycin in case of sulfa drug hypersensitivity) along with leucovorin (folinic acid).

(Choice A) Amphotericin (with flucytosine) is used to treat cryptococcal meningitis, a well-known cause of meningitis in AIDS patients that typically manifests with nausea, vomiting, nuchal rigidity, and altered mental status. Ring-enhancing lesions are not commonly seen on imaging as cryptococcomas are rare. Amphotericin can treat invasive aspergillosis; however, central nervous system aspergillosis more classically presents as an abscess (eg, single ring-enhancing lesion), is often accompanied by pulmonary (eg, cough, dyspnea) and orbital manifestations in patients with HIV, and is primarily treated with voriconazole rather than amphotericin.

(Choice B) Ampicillin is typically used to treat *Listeria* infection. *L monocytogenes* can cause meningitis in immunosuppressed patients but does not typically form ring-enhancing lesions.

(Choice C) Ganciclovir is used in the treatment of cytomegalovirus (CMV) infection. CMV primarily causes symptomatic disease (eg, retinitis, esophagitis, pneumonia) in the immunosuppressed. Characteristic manifestations of central nervous system involvement include polyneuropathy, transverse myelitis, and encephalitis.

(Choice D) In developing countries, mycobacterial infection causes brain tuberculomas (nodular granulomatous lesions), but this would be less likely in the United States. Tuberculoma treatment typically includes 5 antitubercular drugs rather than only isoniazid and rifampin.

The differential diagnosis for this patient also includes primary central nervous system lymphoma (second most common after cerebral toxoplasmosis), primary brain tumors (eg, glioblastoma multiforme), metastatic carcinoma, and fungal or bacterial abscesses.

Educational objective:
In patients with HIV, the presence of multiple ring-enhancing lesions with mass effect is most often indicative of toxoplasmosis, followed by primary

(Choice A) Amphotericin (with flucytosine) is used to treat cryptococcal meningitis, a well-known cause of meningitis in AIDS patients that typically manifests with nausea, vomiting, nuchal rigidity, and altered mental status. Ring-enhancing lesions are not commonly seen on imaging as cryptococcomas are rare. Amphotericin can treat invasive aspergillosis; however, central nervous system aspergillosis more classically presents as an abscess (eg, single ring-enhancing lesion), is often accompanied by pulmonary (eg, cough, dyspnea) and orbital manifestations in patients with HIV, and is primarily treated with voriconazole rather than amphotericin.

(Choice B) Ampicillin is typically used to treat *Listeria* infection. *L monocytogenes* can cause meningitis in immunosuppressed patients but does not typically form ring-enhancing lesions.

(Choice C) Ganciclovir is used in the treatment of cytomegalovirus (CMV) infection. CMV primarily causes symptomatic disease (eg, retinitis, esophagitis, pneumonia) in the immunosuppressed. Characteristic manifestations of central nervous system involvement include polyneuropathy, transverse myelitis, and encephalitis.

(Choice D) In developing countries, mycobacterial infection causes brain tuberculomas (nodular granulomatous lesions), but this would be less likely in the United States. Tuberculoma treatment typically includes 5 antitubercular drugs rather than only isoniazid and rifampin.

The differential diagnosis for this patient also includes primary central nervous system lymphoma (second most common after cerebral toxoplasmosis), primary brain tumors (eg, glioblastoma multiforme), metastatic carcinoma, and fungal or bacterial abscesses.

Educational objective:
In patients with HIV, the presence of multiple ring-enhancing lesions with mass effect is most often indicative of toxoplasmosis, followed by primary central nervous system lymphoma.

References

- Use of CT and MR imaging to distinguish intracranial lesions and to define the need for biopsy in AIDS patients.

Microbiology	Nervous System	Toxoplasmosis
Subject	System	Topic

Copyright © UWorld. All rights reserved.

Item 2 of 2

After 10 days of empiric therapy, the patient's clinical situation has not improved significantly and the appearance of the brain lesions on MRI is unchanged. Results for *Toxoplasma* serology and polymerase chain reaction (PCR) testing are negative. Cerebrospinal fluid PCR analysis for Epstein-Barr virus is positive. Tissue biopsy from the frontal lobe lesions would likely predominantly show an abnormal population of which of the following cells?

- A. B-lymphocytes
- B. Eosinophils
- C. Macrophages
- D. Oligodendrocytes
- E. T-lymphocytes

Submit

Item 2 of 2

After 10 days of empiric therapy, the patient's clinical situation has not improved significantly and the appearance of the brain lesions on MRI is unchanged. Results for *Toxoplasma* serology and polymerase chain reaction (PCR) testing are negative. Cerebrospinal fluid PCR analysis for Epstein-Barr virus is positive. Tissue biopsy from the frontal lobe lesions would likely predominantly show an abnormal population of which of the following cells?

- ✓ A. B-lymphocytes (61%)
- B. Eosinophils (1%)
- C. Macrophages (4%)
- D. Oligodendrocytes (2%)
- E. T-lymphocytes (30%)

Omitted
Correct answer
A

61%
Answered correctly

02 secs
Time Spent

02/16/2020
Last Updated

Explanation

In a patient with HIV and multiple ring-enhancing lesions being treated empirically for toxoplasmosis, lack of a clinical or imaging response after 1-3 weeks of therapy should raise suspicion for other conditions requiring further evaluation, especially given negative *Toxoplasma* serologies. **Primary central nervous system lymphoma** (PCNSL) is the second most common cause of ring-enhancing lesions with mass effect in HIV. Classically, large, solitary lesions are more likely to suggest PCNSL rather than toxoplasmosis; however, multiple lesions (as seen in this patient)

In a patient with HIV and multiple ring-enhancing lesions being treated empirically for toxoplasmosis, lack of a clinical or imaging response after 1-3 weeks of therapy should raise suspicion for other conditions requiring further evaluation, especially given negative *Toxoplasma* serologies. **Primary central nervous system lymphoma** (PCNSL) is the second most common cause of ring-enhancing lesions with mass effect in HIV. Classically, large, solitary lesions are more likely to suggest PCNSL rather than toxoplasmosis; however, multiple lesions (as seen in this patient) are also common in PCNSL.

PCNSL is a diffuse, large-cell non-Hodgkin lymphoma of **B-cell origin** that usually occurs as a late complication of HIV infection. **Epstein-Barr virus** (EBV) is identified in almost all cases. Diagnosis of PCNSL can be made by positive EBV polymerase chain reaction analysis in the cerebrospinal fluid. Definitive diagnosis requires brain biopsy. Although EBV infections in general can be associated with abnormal T-lymphocytes (eg, atypical lymphocytes), T cell infiltration is not commonly seen on brain tissue biopsy of patients with HIV who have PCNSL. T-lymphocytes are the malignant cells in AIDS-associated T-cell lymphoma, not PCNSL **(Choice E)**.

(Choice B) Eosinophils do not give rise to solid tumors.

(Choice C) Macrophages are the primary cell population in histiocytomas. Patients with Langerhans cell histiocytosis may develop eosinophilic granulomas that preferentially affect the skull, but ring-enhancing lesions are not seen.

(Choice D) Oligodendrocytes can form oligodendrogliomas. Astrocytes are the precursor cells for glioblastoma multiforme, which can present with a ring-enhancing lesion.

Educational objective:
Primary central nervous system lymphoma is typically composed of B-lymphocytes.

References

- Epstein-Barr virus in AIDS-related primary central nervous system lymphoma.
- T-cell infiltration of primary CNS lymphoma.

Microbiology	Nervous System	Cns lymphoma
Subject	System	Topic

A 58-year-old man comes to the emergency department with a 1-day history of fever, headache, and vomiting. He underwent kidney transplantation last year. His temperature is 39.4 C (103 F), blood pressure is 130/80 mm Hg, pulse is 98/min, and respirations are 16/min. Neck stiffness is present on physical examination. Cerebrospinal fluid (CSF) results are as follows:

Glucose	40 mg/dL
Protein	80 mg/dL
Leukocytes	900/mm^3
Neutrophils	80%

Gram-positive rods with tumbling motility at room temperature are seen on CSF microscopy. How was this patient's infection most likely transmitted?

- A. Arthropod bite
- B. Contaminated food
- C. Needlestick
- D. Respiratory droplets
- E. Unprotected sex

Submit

A 58-year-old man comes to the emergency department with a 1-day history of fever, headache, and vomiting. He underwent kidney transplantation last year. His temperature is 39.4 C (103 F), blood pressure is 130/80 mm Hg, pulse is 98/min, and respirations are 16/min. Neck stiffness is present on physical examination. Cerebrospinal fluid (CSF) results are as follows:

Glucose	40 mg/dL
Protein	80 mg/dL
Leukocytes	900/mm^3
Neutrophils	80%

Gram-positive rods with tumbling motility at room temperature are seen on CSF microscopy. How was this patient's infection most likely transmitted?

- A. Arthropod bite (1%)
- ✓ B. Contaminated food (72%)
- C. Needlestick (1%)
- D. Respiratory droplets (21%)
- E. Unprotected sex (2%)

Omitted
Correct answer
B

72%
Answered correctly

02 secs
Time Spent

03/24/2020
Last Updated

This patient, who is almost certainly taking anti-rejection immunosuppressants given his kidney transplantation, has fever, headache, neck stiffness, and cerebrospinal fluid (CSF) findings suggestive of bacterial meningitis. There is CSF pleocytosis (elevated leukocyte count) with left shift, elevated protein, and low-normal glucose (low CSF glucose is seen in most though not all bacterial meningitis cases); and bacteria are seen on CSF microscopy.

The microbiologic findings are consistent with ***Listeria monocytogenes*** infection; this is a facultative intracellular (grows within macrophages), gram-positive rod, with distinctive flagellar-based **tumbling motility** (typically seen at room temperature but not at human body temperatures). *Listeria* can **multiply in cold temperatures** (4-10 C [39.2-50 F]), a unique feature that allows it to grow well in refrigerated foods. Listeriosis most often occurs in **immunocompromised** adults (eg, renal transplantation, hematologic malignancy). The bacteria can access the bloodstream following ingestion of contaminated food (eg, **unpasteurized milk** and milk products, undercooked meats, unwashed raw vegetables) and cause meningitis, meningoencephalitis, or bacteremia. *Listeria* can also be transmitted transplacentally or via vaginal contact during delivery, causing neonatal meningitis. Ampicillin is the antibiotic of choice.

(Choice A) Among the diseases transmitted by arthropod bites are: leishmaniasis (sandfly bite), *Plasmodium*/malaria (*Anopheles* mosquito bite), Chagas disease (reduviid bug bite), and *Borrelia burgdorferi*/Lyme disease (*Ixodes* tick bite).

(Choice C) Needlesticks can transmit HIV, hepatitis B and C, and other infections.

(Choice D) *Neisseria meningitidis, Haemophilus influenzae, Mycobacterium tuberculosis*, and many other organisms are transmitted via respiratory droplets. *Listeria* infections are not transmitted in this manner.

(Choice E) Unprotected sex is the mode of transmission of HIV, hepatitis B, gonorrhea, chlamydia, syphilis, human papillomavirus (a cause of cervical cancer), and others.

Educational objective:
Listeriosis is most commonly transmitted through food ingestions and can cause meningitis in immunocompromised adults. *Listeria* is a gram-positive rod with tumbling motility. It grows well in cold temperatures and can therefore contaminate refrigerated food.

References

- What is new in listeriosis?
- Listeria monocytogenes regulates flagellar motility gene expression through MogR, a transcriptional repressor required for virulence

1 2 3 4 5 6 7 8 9 10 11 12 13 14 15 16 17 18 19 20 21 22 23 24 25 26 27 28 29 30

gram positive rod, with distinctive flagellar based **tumbling motility** (typically seen at room temperature but not at human body temperatures).

Listeria can **multiply in cold temperatures** (4-10 C [39.2-50 F]), a unique feature that allows it to grow well in refrigerated foods. Listeriosis most often occurs in **immunocompromised** adults (eg, renal transplantation, hematologic malignancy). The bacteria can access the bloodstream following ingestion of contaminated food (eg, **unpasteurized milk** and milk products, undercooked meats, unwashed raw vegetables) and cause meningitis, meningoencephalitis, or bacteremia. *Listeria* can also be transmitted transplacentally or via vaginal contact during delivery, causing neonatal meningitis. Ampicillin is the antibiotic of choice.

(Choice A) Among the diseases transmitted by arthropod bites are: leishmaniasis (sandfly bite), *Plasmodium*/malaria (*Anopheles* mosquito bite), Chagas disease (reduviid bug bite), and *Borrelia burgdorferi*/Lyme disease (*Ixodes* tick bite).

(Choice C) Needlesticks can transmit HIV, hepatitis B and C, and other infections.

(Choice D) *Neisseria meningitidis, Haemophilus influenzae, Mycobacterium tuberculosis*, and many other organisms are transmitted via respiratory droplets. *Listeria* infections are not transmitted in this manner.

(Choice E) Unprotected sex is the mode of transmission of HIV, hepatitis B, gonorrhea, chlamydia, syphilis, human papillomavirus (a cause of cervical cancer), and others.

Educational objective:
Listeriosis is most commonly transmitted through food ingestions and can cause meningitis in immunocompromised adults. *Listeria* is a gram-positive rod with tumbling motility. It grows well in cold temperatures and can therefore contaminate refrigerated food.

References

- What is new in listeriosis?
- Listeria monocytogenes regulates flagellar motility gene expression through MogR, a transcriptional repressor required for virulence.

Microbiology	Nervous System	Meningitis
Subject	System	Topic

Copyright © UWorld. All rights reserved.

Glucose	65 mg/dL
Protein	85 mg/dL
Leukocytes	300/mm^3
Differential	
Neutrophils	15%
Lymphocytes	85%
Red blood cells	none

Which of the following infectious agents is most likely to have caused this patient's illness?

A. Coronavirus

B. *Cryptococcus neoformans*

C. Enterovirus

D. Mumps virus

E. *Neisseria meningitidis*

F. *Streptococcus agalactiae*

G. *Streptococcus pneumoniae*

Submit

A 6-year-old boy is brought to the emergency department by his parents with a 2-day history of fever and headaches. The parents report that he vomited once this afternoon. All of his vaccinations are up-to-date and he has no significant past medical history. His temperature is 38.7 C (102 F). Examination shows mild pharyngeal erythema in addition to neck stiffness. Cerebrospinal fluid analysis reveals the following:

Glucose	65 mg/dL
Protein	85 mg/dL
Leukocytes	300/mm^3
Differential	
Neutrophils	15%
Lymphocytes	85%
Red blood cells	none

Which of the following infectious agents is most likely to have caused this patient's illness?

A. Coronavirus
B. *Cryptococcus neoformans*
C. Enterovirus
D. Mumps virus
E. *Neisseria meningitidis*
F. *Streptococcus agalactiae*
G. *Streptococcus pneumoniae*

Glucose	65 mg/dL
Protein	85 mg/dL
Leukocytes	300/mm^3
Differential	
Neutrophils	15%
Lymphocytes	85%
Red blood cells	none

Which of the following infectious agents is most likely to have caused this patient's illness?

A. Coronavirus

B. *Cryptococcus neoformans*

C. Enterovirus

D. Mumps virus

E. *Neisseria meningitidis*

F. *Streptococcus agalactiae*

G. *Streptococcus pneumoniae*

Submit

1 2 3 4 5 6 7 8 9 10 11 12 13 14 15 16 17 18 19 20 21 22 23 24 25 26 27 28 29 30

Glucose	65 mg/dL
Protein	85 mg/dL
Leukocytes	300/mm^3
Differential	
Neutrophils	15%
Lymphocytes	85%
Red blood cells	none

Which of the following infectious agents is most likely to have caused this patient's illness?

- A. Coronavirus (13%)
- B. *Cryptococcus neoformans* (4%)
- ✓ C. Enterovirus (56%)
- D. Mumps virus (7%)
- E. *Neisseria meningitidis* (6%)
- F. *Streptococcus agalactiae* (1%)
- G. *Streptococcus pneumoniae* (8%)

Omitted
Correct answer

56%
Answered correctly

05 secs
Time Spent

03/31/2020
Last Updated

Differences between bacterial & viral meningitis

	Viral	Bacterial
Common microbes	• **Enteroviruses** (most common) • Arboviruses • Herpes simplex virus type 2	• **Adults**: *Streptococcus pneumoniae* & *Neisseria meningitidis* • **Neonates**: Group B *Streptococcus* & gram-negative bacilli
CSF cell differential	• WBC count often **<500** cells/mm^3 • Lymphocytic predominance	• WBC count often **>1000** cells/mm^3 • Neutrophilic predominance
CSF glucose & protein	• Glucose levels are **normal** or slightly reduced • Protein generally <150 mg/dL	• Glucose levels **<45 mg/dL** • Protein is often >250 mg/dL
CSF Gram stain & culture	• No organisms identified	• Often positive for a specific organism

CSF = cerebrospinal fluid; WBC = white blood cell.

This child has clinical evidence of meningitis (fever, headache, vomiting, stiff neck). Analysis of the cerebrospinal fluid (CSF) shows **normal** glucose, marginally elevated protein, and pleocytosis with a **lymphocytic** predominance. This pattern suggests **aseptic meningitis**, which is usually viral in etiology. **Enteroviruses** (eg, coxsackievirus, echovirus, poliovirus) are responsible for >90% of cases. Clinical symptoms are similar to meningitis caused by bacterial or fungal pathogens. However, aseptic meningitis is generally **less severe**, and focal neurologic signs, seizures, and alterations in mental status are absent. The presence of any of these should prompt consideration of other conditions, including bacterial meningitis, encephalitis, and intracranial hemorrhage. A negative Gram stain and **sterile culture** will further support the diagnosis of aseptic meningitis.

(Choice A) Coronavirus is a common cause of cold symptoms. It is not a common cause of viral meningitis.

(Choice B) *Cryptococcus neoformans* is a common cause of meningitis in immunocompromised patients (eg, AIDS patients). The diagnosis is made by testing for cryptococcal antigens or by identifying India ink-stained organisms in the CSF.

(Choice D) The mumps virus can cause aseptic meningitis, but this would be extremely unlikely in this fully immunized child. Meningitis caused by mumps is accompanied by parotitis in 50% of cases.

(Choices E, F, and G) *Streptococcus pneumoniae* and *Neisseria meningitidis* are the most common causes of bacterial meningitis in adults; *S agalactiae* (group B *Streptococcus*) is the most common cause of meningitis in neonates. Bacterial and viral meningitis both cause fever, nuchal rigidity, and headache. However, this patient's CSF analysis is more suggestive of aseptic meningitis.

Educational objective:
Fever; meningeal signs (eg, headache, neck stiffness); and cerebrospinal fluid that shows lymphocytic pleocytosis, a modestly elevated protein level, and normal glucose are suggestive of aseptic meningitis. Enteroviruses are the most common cause of aseptic meningitis.

References

- Viral meningitis.
- Meningitis.
- Viral diseases of the central nervous system.

A 61-year-old man comes to the office due to a painful rash on his face for the past 3 days. The patient has no other medical conditions and takes no medications. He is a retired schoolteacher and lives with his wife. Skin examination findings are shown in the exhibit. The remainder of the physical examination shows no abnormalities. Which of the following events most likely immediately preceded the appearance of skin rash in this patient?

A. Alteration in the patient's normal skin flora

B. Close physical contact with an infected person

C. Inhalation of pathogen-containing aerosols

D. Reactivation of latent organism in sensory ganglia

E. Waning of organism-specific antibodies

Submit

A 61-year-old man comes to the office due to a painful rash on his face for the past 3 days. The patient has no other medical conditions and takes no medications. He is a retired schoolteacher and lives with his wife. Skin examination findings are shown in the exhibit. The remainder of the physical examination shows no abnormalities. Which of the following events most likely immediately preceded the appearance of skin rash in this patient?

- A. Alteration in the patient's normal skin flora (3%)
- B. Close physical contact with an infected person (3%)
- C. Inhalation of pathogen-containing aerosols (8%)
- ✓ D. Reactivation of latent organism in sensory ganglia (82%)
- E. Waning of organism-specific antibodies (1%)

Omitted
Correct answer
D

82%
Answered correctly

02 secs
Time Spent

03/23/2020
Last Updated

Explanation

Varicella-zoster virus (VZV) infection

Latency (dormant VZV) —Years later→ **Reactivation** of VZV by aging, immunosuppression

1 2 3 4 5 6 7 8 9 10 11 12 13 14 15 16 17 18 19 20 21 22 23 24 25 26 27 28 29 30

Varicella-zoster virus (VZV) infection

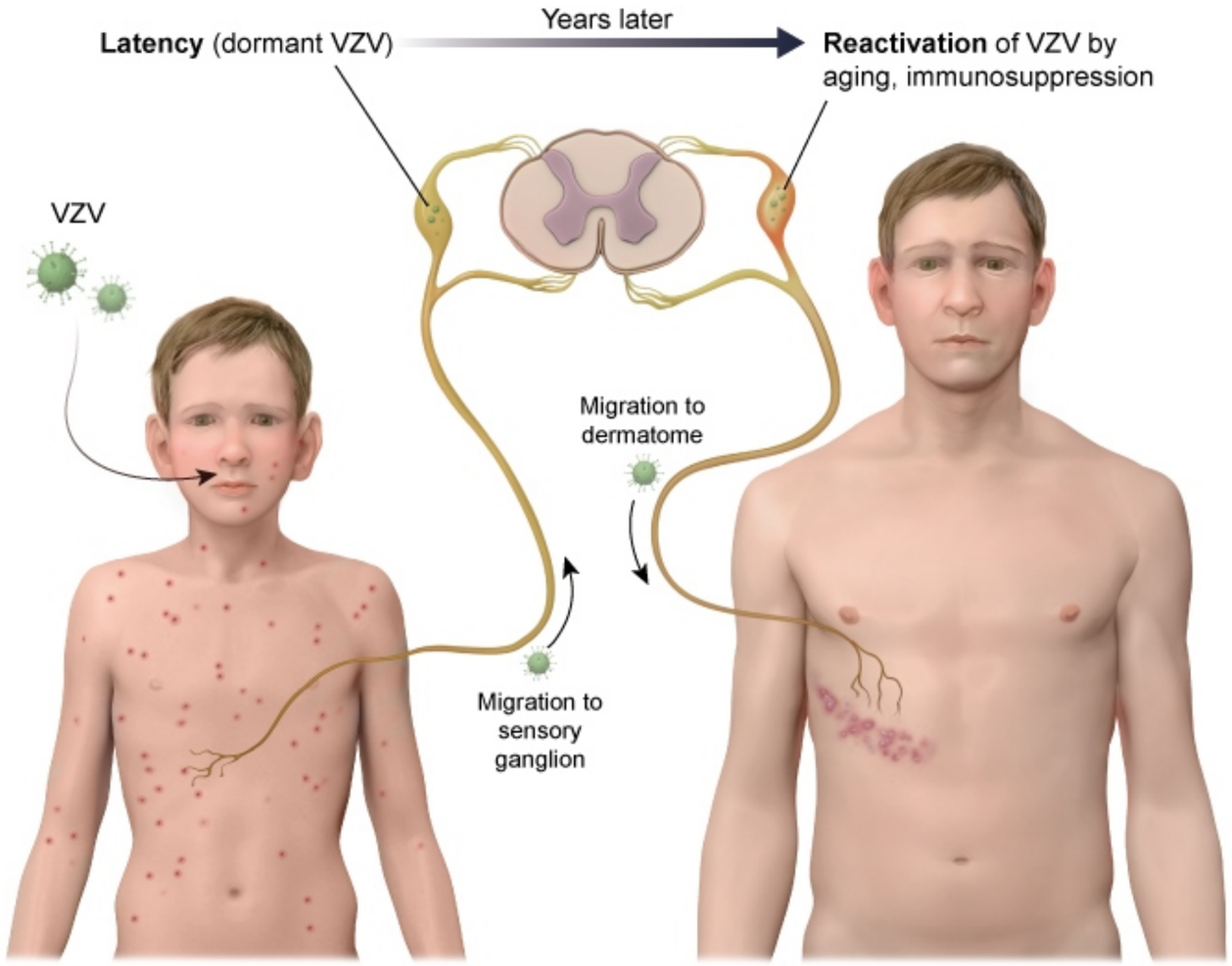

Varicella (chickenpox)
Generalized vesicular rash

Herpes zoster (shingles)
Unilateral, linear vesicular rash

©UWorld

This patient has a crusted vesicular rash in a dermatomal distribution consistent with **shingles** (herpes zoster). Shingles is caused by **reactivation** of **varicella-zoster virus** (VZV), a double-stranded DNA virus of the herpesvirus family. Primary VZV infection occurs most commonly in childhood. Inoculation in the nasopharyngeal mucosa is followed by migration of the virus to the regional lymphatics. Subsequent dermatotrophic migration produces a diffuse vesicular rash associated with fever, malaise, and pharyngitis (**chickenpox**). Then, the virus migrates via sensory nerves to **cranial nerve and dorsal spinal ganglia**, where it lies dormant for decades.

Most patients who have had primary chickenpox do not develop recurrent diffuse disease. Over time, however, waning cell-mediated immune function allows reactivation of the virus, which typically spreads down a single spinal nerve to cause a painful, erythematous, vesicular rash in a dermatomal distribution. The primary risk factor for reactivation is increasing age; other factors can include malignancy, autoimmune disease, and immune-suppressing therapy.

The varicella vaccine is recommended for prevention of primary disease in children, women of childbearing age, adults with sustained risk of exposure, and household contacts of immunocompromised hosts. Zoster vaccine is recommended for adults age ≥50 and reduces the risk of reactivation.

(Choice A) Colonization of the skin by transient flora (eg, *Staphylococcus aureus*, *Candida* species, gram-negative bacilli) occasionally leads to clinical disease, especially following antibiotic exposure (eg, vaginal candidiasis). However, VZV does not remain on the surface of the skin for prolonged periods.

(Choices B and C) Primary VZV infection (ie, chickenpox) can be acquired by direct contact or airborne aerosol from patients with active chickenpox or zoster lesions. However, primary VZV infection causes diffuse lesions; lesions in a dermatomal distribution are seen only with reactivation from sensory ganglia.

(Choice E) Declining VZV-specific immunity increases the risk of reactivation. However, the immune response to VZV is primarily based on cell-mediated, rather than humoral (ie, antibodies), factors.

Educational objective:
Primary varicella-zoster virus infection (chickenpox) occurs most commonly in childhood. Subsequently, the virus migrates to the sensory ganglia, where it lies dormant for decades. Over time, waning cell-mediated immunity allows reactivation of the virus, which spreads down a single nerve to cause a painful, erythematous, vesicular rash in a dermatomal distribution.

dermatomal distribution. The primary risk factor for reactivation is increasing age; other factors can include malignancy, autoimmune disease, and immune-suppressing therapy.

The varicella vaccine is recommended for prevention of primary disease in children, women of childbearing age, adults with sustained risk of exposure, and household contacts of immunocompromised hosts. Zoster vaccine is recommended for adults age ≥50 and reduces the risk of reactivation.

(Choice A) Colonization of the skin by transient flora (eg, *Staphylococcus aureus*, *Candida* species, gram-negative bacilli) occasionally leads to clinical disease, especially following antibiotic exposure (eg, vaginal candidiasis). However, VZV does not remain on the surface of the skin for prolonged periods.

(Choices B and C) Primary VZV infection (ie, chickenpox) can be acquired by direct contact or airborne aerosol from patients with active chickenpox or zoster lesions. However, primary VZV infection causes diffuse lesions; lesions in a dermatomal distribution are seen only with reactivation from sensory ganglia.

(Choice E) Declining VZV-specific immunity increases the risk of reactivation. However, the immune response to VZV is primarily based on cell-mediated, rather than humoral (ie, antibodies), factors.

Educational objective:
Primary varicella-zoster virus infection (chickenpox) occurs most commonly in childhood. Subsequently, the virus migrates to the sensory ganglia, where it lies dormant for decades. Over time, waning cell-mediated immunity allows reactivation of the virus, which spreads down a single nerve to cause a painful, erythematous, vesicular rash in a dermatomal distribution.

References

- Molecular mechanisms of varicella zoster virus pathogenesis.

Microbiology	Nervous System	Herpes zoster
Subject	System	Topic

Copyright © UWorld. All rights reserved.

A 73-year-old woman comes to the physician complaining of progressive, severe pain and discharge from her left ear for the past 2 days. She has had type 2 diabetes for many years and has been noncompliant with her medications and follow-up appointments. On examination, moving or touching the pinna produces extreme pain. Otoscopic examination shows granulation tissue in the left ear canal with a scant amount of discharge. The tympanic membrane is clear, and there is no middle ear effusion. Initial cultures from the ear show a Gram-negative rod. Which of the following microbiological characteristics best describes the infecting organism?

A. Comma-shaped and grows well in high pH

B. Fast lactose fermenter

C. Motile and oxidase positive

D. Nonmotile and a lactose nonfermenter

E. Requires factors V and X for growth

Submit

A 73-year-old woman comes to the physician complaining of progressive, severe pain and discharge from her left ear for the past 2 days. She has had type 2 diabetes for many years and has been noncompliant with her medications and follow-up appointments. On examination, moving or touching the pinna produces extreme pain. Otoscopic examination shows granulation tissue in the left ear canal with a scant amount of discharge. The tympanic membrane is clear, and there is no middle ear effusion. Initial cultures from the ear show a Gram-negative rod. Which of the following microbiological characteristics best describes the infecting organism?

- A. Comma-shaped and grows well in high pH (2%)
- B. Fast lactose fermenter (6%)
- ✓ C. Motile and oxidase positive (42%)
- D. Nonmotile and a lactose nonfermenter (25%)
- E. Requires factors V and X for growth (22%)

Omitted
Correct answer
C

42%
Answered correctly

02 secs
Time Spent

06/07/2020
Last Updated

Explanation

Distinguishing characteristics of Pseudomonas aeruginosa infections

Distinguishing characteristics of Pseudomonas aeruginosa infections	
Types of infections	• Pneumonia (especially in cystic fibrosis and ventilated patients) • Life-threatening infections in neutropenic and burn patients • Otitis externa (particularly malignant) • Hot tub folliculitis • Ecthyma gangrenosum
Microbiology	• Motile aerobic Gram-negative rod • Nonlactose-fermenting, oxidase-positive • Produces pyocyanin (blue-green) pigment • Emits a grapelike, fruity odor • Produces endotoxin (fever, shock) and exotoxin A (inactivates EF-2)
Effective antibiotics	• Aminoglycosides (gentamicin, tobramycin, amikacin) • Antipseudomonal penicillins (ticarcillin, piperacillin) • 3rd- and 4th- generation cephalosporins (ceftazidime, cefepime) • Quinolones (ciprofloxacin)

Microbiology	• Motile aerobic Gram-negative rod • Nonlactose-fermenting, oxidase-positive • Produces pyocyanin (blue-green) pigment • Emits a grapelike, fruity odor • Produces endotoxin (fever, shock) and exotoxin A (inactivates EF-2)
Effective antibiotics	• Aminoglycosides (gentamicin, tobramycin, amikacin) • Antipseudomonal penicillins (ticarcillin, piperacillin) • 3rd- and 4th- generation cephalosporins (ceftazidime, cefepime) • Quinolones (ciprofloxacin) • Monobactams (aztreonam) • Carbapenems (imipenem, meropenem)

©UWorld

This patient's presentation is consistent with malignant otitis externa (MOE), a severe infection most commonly seen in elderly diabetic patients. It is most frequently caused by *Pseudomonas aeruginosa*, a nonlactose-fermenting, oxidase-positive, motile Gram-negative rod. Patients typically present with exquisite ear pain and drainage. The granulation tissue seen within the ear canal is an important characteristic finding of MOE, and the tympanic membrane is usually intact. Progression of this infection can lead to osteomyelitis of the skull base and cranial nerve damage. Treatment consists of systemic antibiotics such as ciprofloxacin that are effective against *P aeruginosa*.

(Choice A) *Vibrio cholerae* is an oxidase-positive, Gram-negative, comma-shaped rod that can grow on an alkaline medium that kills most organisms. *V cholerae* causes a toxin-mediated (stimulates adenylyl cyclase) watery diarrhea.

This patient's presentation is consistent with malignant otitis externa (MOE), a severe infection most commonly seen in elderly diabetic patients. It is most frequently caused by *Pseudomonas aeruginosa*, a nonlactose-fermenting, oxidase-positive, motile Gram-negative rod. Patients typically present with exquisite ear pain and drainage. The granulation tissue seen within the ear canal is an important characteristic finding of MOE, and the tympanic membrane is usually intact. Progression of this infection can lead to osteomyelitis of the skull base and cranial nerve damage. Treatment consists of systemic antibiotics such as ciprofloxacin that are effective against *P aeruginosa*.

(Choice A) *Vibrio cholerae* is an oxidase-positive, Gram-negative, comma-shaped rod that can grow on an alkaline medium that kills most organisms. *V cholerae* causes a toxin-mediated (stimulates adenylyl cyclase) watery diarrhea.

(Choice B) Gram-negative rods that are fast lactose fermenters include *Klebsiella* and *Escherichia coli*. They commonly cause urinary tract infections.

(Choice D) *Shigella* is a Gram-negative, nonlactose-fermenting, nonmotile, rod-shaped bacterium. It causes shigellosis, a hemorrhagic diarrheal disease.

(Choice E) *Haemophilus influenza* is Gram-negative, rod-shaped bacterium that requires factor X (hematin) and factor V (NAD+) for growth. Nontypable (unencapsulated) *H influenzae* is a frequent cause of acute otitis media in children and adults. Acute otitis media is associated with an inflamed, erythematous, bulging, immobile tympanic membrane due to the presence of infected fluid in the middle ear.

Educational objective:
Pseudomonas aeruginosa is a nonlactose-fermenting, oxidase-positive, motile, Gram-negative rod. It is the most common cause of malignant otitis externa (MOE), a serious infection of the ear seen in elderly diabetic patients. MOE presents with exquisite ear pain and drainage, and granulation tissue is often seen within the ear canal.

References

- Malignant otitis externa.

Microbiology	Ear, Nose & Throat (ENT)	Otitis externa
Subject	System	Topic

A 7-year-old boy is brought to the emergency department due to fever, headache, vomiting, and confusion. He has no prior medical conditions and is up to date with immunizations. The patient has not traveled recently, and his parents report no exposure to individuals with similar symptoms or ingestion of anything out of the ordinary. They have recently noticed several dead birds around their neighborhood. Temperature is 39 C (102.2 F). Physical examination shows neck rigidity and right lower extremity weakness with fasciculations. Cerebrospinal fluid analysis shows a leukocyte count of 200/mm^3 with 20% neutrophils and 80% lymphocytes. Which of the following is the most likely pathogen responsible for this patient's condition?

- A. *Cryptococcus neoformans*
- B. *Hemophilus influenzae*
- C. Herpes simplex virus
- D. Nonpolio enterovirus
- E. Polio virus
- F. *Streptococcus pneumoniae*
- G. West Nile virus

Submit

A 7-year-old boy is brought to the emergency department due to fever, headache, vomiting, and confusion. He has no prior medical conditions and is up to date with immunizations. The patient has not traveled recently, and his parents report no exposure to individuals with similar symptoms or ingestion of anything out of the ordinary. They have recently noticed several dead birds around their neighborhood. Temperature is 39 C (102.2 F). Physical examination shows neck rigidity and right lower extremity weakness with fasciculations. Cerebrospinal fluid analysis shows a leukocyte count of 200/mm^3 with 20% neutrophils and 80% lymphocytes. Which of the following is the most likely pathogen responsible for this patient's condition?

- A. *Cryptococcus neoformans* (27%)
- B. *Hemophilus influenzae* (2%)
- C. Herpes simplex virus (2%)
- D. Nonpolio enterovirus (19%)
- E. Polio virus (6%)
- F. *Streptococcus pneumoniae* (1%)
- ✓ G. West Nile virus (40%)

Omitted
Correct answer
G

40%
Answered correctly

03 secs
Time Spent

02/09/2020
Last Updated

Explanation

West Nile virus	
Clinical syndrome	• West Nile fever: fever, headache, rash (maculopapular/morbilliform) • Neuroinvasive: meningitis, encephalitis, acute asymmetric flaccid paralysis ◦ Parkinsonian symptoms (eg, rigidity, bradykinesia, tremor)
Transmission	• Mosquitoes (*Culex* spp.) • More common in summer/fall • Warm climate (southern United States, Latin America, Africa)
Risk factors	• Older age • Malignancy/organ transplant

West Nile virus is an enveloped RNA virus that is found in warm climates worldwide. The virus replicates extensively within **birds** and is passed to **mosquitos** (*Culex* species) during blood feeding. Viral accumulation in mosquito salivary glands can lead to human transmission. Most infected patients develop low-level viremia that is neutralized within a week by the humoral immune response; these individuals typically remain asymptomatic. However, a minority of patients (particularly the young, elderly, or immunosuppressed) are unable to mount an effective immune response and develop significant clinical manifestations, including:

- **West Nile fever** – a self-limited, **flu-like illness** that is often associated with a maculopapular rash
- **Neuroinvasive disease** – the virus is neurotropic and often causes meningitis (eg, fever, headache, neck stiffness), **encephalitis** (eg, confusion, tremors, seizures), and/or **flaccid paralysis** (eg, asymmetric weakness of limbs, fasciculations). Cerebrospinal fluid usually shows a lymphocytic pleocytosis.

Most patients recover completely with supportive care, but some with neuroinvasive disease have long-term neurologic sequelae or die.

(Choice A) *Cryptococcus neoformans*, a fungus found in bird feces, can cause meningoencephalitis. However, most cases occur in those with severe immunosuppression (eg, advanced AIDS).

(Choices B and E) *Hemophilus influenzae* and *Streptococcus pneumoniae* are leading causes of acute bacterial meningitis, which is often

- **West Nile fever** – a self-limited, **flu-like illness** that is often associated with a maculopapular rash
- **Neuroinvasive disease** – the virus is neurotropic and often causes meningitis (eg, fever, headache, neck stiffness), **encephalitis** (eg, confusion, tremors, seizures), and/or **flaccid paralysis** (eg, asymmetric weakness of limbs, fasciculations). Cerebrospinal fluid usually shows a lymphocytic pleocytosis.

Most patients recover completely with supportive care, but some with neuroinvasive disease have long-term neurologic sequelae or die.

(Choice A) *Cryptococcus neoformans*, a fungus found in bird feces, can cause meningoencephalitis. However, most cases occur in those with severe immunosuppression (eg, advanced AIDS).

(Choices B and F) *Hemophilus influenzae* and *Streptococcus pneumoniae* are leading causes of acute bacterial meningitis, which is often associated with fever, headache, vomiting, and neck stiffness. However, cerebrospinal fluid usually shows a high neutrophil count. In addition, lower-motor neuron signs such as fasciculations would be atypical.

(Choice C) Herpes simplex virus is a leading cause of sporadic encephalitis; it is usually characterized by confusion, focal neurologic deficits (eg, hemiparesis, dysphagia, cranial nerve defects), and seizures. It is not harbored in birds; cerebrospinal fluid usually shows elevated erythrocytes (in addition to lymphocytic pleocytosis); and lower-motor neuron signs (eg, fasciculations) are absent.

(Choice D) Nonpolio enteroviruses (eg, Coxsackievirus, echovirus) often cause aseptic (viral) meningitis and can occasionally cause encephalitis. However, these viruses are not associated with bird vectors and do not typically cause lower-motor neuron signs.

(Choice E) Polio virus is a common cause of acute, asymmetric flaccid paralysis, but it has been eliminated from the United States.

Educational objective:
West Nile virus is harbored in birds and transmitted to humans by mosquitos. Most patients are asymptomatic, but the virus can cause an influenza-like illness or neuroinvasive disease with meningitis, encephalitis, and flaccid paralysis.

Microbiology	Nervous System	West Nile virus infection
Subject	System	Topic

1 2 3 4 5 6 7 8 9 10 11 12 13 14 15 16 17 18 19 20 21 22 23 24 25 26 27 28 29 30

A 38-year-old woman comes to the emergency department due to 2 days of headache, nausea, and photophobia. She has had migraines since her early 20s but has had more frequent episodes over the last few years. The current headache is more severe than usual, and ibuprofen did not relieve the pain. A flulike illness preceded the symptoms. Temperature is 38.3 C (100.9 F), blood pressure is 144/86 mm Hg, and pulse is 110/min. The patient appears lethargic. Cranial nerves, sensation, and motor functions are normal. She reports neck pain when instructed to touch the chest with her chin. No skin rash is present. Noncontrast CT scan of the head shows no abnormalities. Which of the following is the best next step in management of this patient?

A. 100% oxygen inhalation

B. Lumbar puncture

C. Metoclopramide

D. MRI of the brain

E. Sumatriptan

F. Topiramate

Submit

A 38-year-old woman comes to the emergency department due to 2 days of headache, nausea, and photophobia. She has had migraines since her early 20s but has had more frequent episodes over the last few years. The current headache is more severe than usual, and ibuprofen did not relieve the pain. A flulike illness preceded the symptoms. Temperature is 38.3 C (100.9 F), blood pressure is 144/86 mm Hg, and pulse is 110/min. The patient appears lethargic. Cranial nerves, sensation, and motor functions are normal. She reports neck pain when instructed to touch the chest with her chin. No skin rash is present. Noncontrast CT scan of the head shows no abnormalities. Which of the following is the best next step in management of this patient?

- A. 100% oxygen inhalation (1%)
- ✓ B. Lumbar puncture (84%)
- C. Metoclopramide (0%)
- D. MRI of the brain (4%)
- E. Sumatriptan (7%)
- F. Topiramate (0%)

Omitted
Correct answer
B

84%
Answered correctly

02 secs
Time Spent

02/03/2020
Last Updated

Explanation

Although migraine headaches are often associated with photophobia and nausea, this patient's fever, stiff neck, and lethargy make **bacterial meningitis** the far more likely diagnosis. Bacterial meningitis is most commonly caused by *Streptococcus pneumoniae* and *Neisseria*

Although migraine headaches are often associated with photophobia and nausea, this patient's fever, stiff neck, and lethargy make **bacterial meningitis** the far more likely diagnosis. Bacterial meningitis is most commonly caused by *Streptococcus pneumoniae* and *Neisseria meningitidis*. These pathogens colonize the host's mucous membranes, spread into the bloodstream, and penetrate the blood-brain barrier. A lack of humoral components (eg, complement system, immunoglobulins) within the central nervous system allows bacteria to rapidly proliferate within the cerebrospinal fluid. The resultant cytokine-mediated inflammatory response causes the classic **triad** of symptoms: **high fever** (>38 C [100.4 F]), **stiff neck**, and **altered level of consciousness**. A generalized severe headache is also usually present.

Patients with suspected bacterial meningitis require urgent blood cultures, empiric antibiotics, and **lumbar puncture** with cerebrospinal fluid analysis to confirm the diagnosis, identify the underlying pathogen, and determine antibiotic sensitivity.

(Choice A) 100% oxygen can be used to abort cluster headaches, which are seen primarily in men and are usually characterized by severe orbital or periorbital pain, restless agitation, and autonomic symptoms (eg, lacrimation, rhinorrhea, ptosis, miosis). Fever and nuchal rigidity would be atypical.

(Choices C, E, and F) Metoclopramide and sumatriptan can be used to abort acute migraines; topiramate is an effective treatment for the prevention of chronic migraine headaches. Migraines are usually characterized by a unilateral throbbing headache with or without associated symptoms such as nausea, aura, or photophobia. Fever, nuchal rigidity, and lethargy would be atypical.

(Choice D) MRI of the brain can be used to evaluate for potential brain tumor. Patients with brain tumors commonly develop dull, constant headaches, focal neurologic symptoms, and seizures. Fever would be atypical. Although brain imaging is often recommended prior to lumbar puncture to evaluate for signs of elevated intracranial pressure, non-contrast head CT is used primarily because it offers rapid results and fewer treatment delays. This patient had a negative head CT; MRI would not be necessary prior to LP.

Educational objective:
The classic triad of fever, stiff neck, and altered mentation should raise suspicion for acute bacterial meningitis. Evaluation requires prompt blood cultures, empiric antibiotics, and lumbar puncture with cerebrospinal fluid analysis.

References

- The evaluation and management of bacterial meningitis: current practice and emerging developments.

within the cerebrospinal fluid. The resultant cytokine-mediated inflammatory response causes the classic **triad** of symptoms: **high fever** (>38 C [100.4 F]), **stiff neck**, and **altered level of consciousness**. A generalized severe headache is also usually present.

Patients with suspected bacterial meningitis require urgent blood cultures, empiric antibiotics, and **lumbar puncture** with cerebrospinal fluid analysis to confirm the diagnosis, identify the underlying pathogen, and determine antibiotic sensitivity.

(Choice A) 100% oxygen can be used to abort cluster headaches, which are seen primarily in men and are usually characterized by severe orbital or periorbital pain, restless agitation, and autonomic symptoms (eg, lacrimation, rhinorrhea, ptosis, miosis). Fever and nuchal rigidity would be atypical.

(Choices C, E, and F) Metoclopramide and sumatriptan can be used to abort acute migraines; topiramate is an effective treatment for the prevention of chronic migraine headaches. Migraines are usually characterized by a unilateral throbbing headache with or without associated symptoms such as nausea, aura, or photophobia. Fever, nuchal rigidity, and lethargy would be atypical.

(Choice D) MRI of the brain can be used to evaluate for potential brain tumor. Patients with brain tumors commonly develop dull, constant headaches, focal neurologic symptoms, and seizures. Fever would be atypical. Although brain imaging is often recommended prior to lumbar puncture to evaluate for signs of elevated intracranial pressure, non-contrast head CT is used primarily because it offers rapid results and fewer treatment delays. This patient had a negative head CT; MRI would not be necessary prior to LP.

Educational objective:
The classic triad of fever, stiff neck, and altered mentation should raise suspicion for acute bacterial meningitis. Evaluation requires prompt blood cultures, empiric antibiotics, and lumbar puncture with cerebrospinal fluid analysis.

References

- The evaluation and management of bacterial meningitis: current practice and emerging developments.

Microbiology	Nervous System	Meningitis
Subject	System	Topic

Copyright © UWorld. All rights reserved.

1 2 3 4 5 6 7 8 9 10 11 12 13 14 15 16 17 18 19 20 21 22 23 24 25 26 27 28 29 30

A 5-year-old boy is brought to the emergency department with worsening somnolence, lethargy, and decreased urine output. The patient has no prior medical conditions but had abdominal cramps and diarrhea several days ago that later became frankly bloody. Physical examination shows mild pallor and moist mucous membranes. Laboratory studies reveal elevated blood urea nitrogen and serum creatinine levels. Peripheral blood smear shows fragmented erythrocytes. This patient's condition is most likely related to consumption of which of the following foods?

- A. Canned beans
- B. Custard
- C. Fried rice
- D. Mayonnaise
- E. Oysters
- F. Raw eggs
- G. Undercooked beef

Submit

A 5-year-old boy is brought to the emergency department with worsening somnolence, lethargy, and decreased urine output. The patient has no prior medical conditions but had abdominal cramps and diarrhea several days ago that later became frankly bloody. Physical examination shows mild pallor and moist mucous membranes. Laboratory studies reveal elevated blood urea nitrogen and serum creatinine levels. Peripheral blood smear shows fragmented erythrocytes. This patient's condition is most likely related to consumption of which of the following foods?

- A. Canned beans (9%)
- B. Custard (1%)
- C. Fried rice (2%)
- D. Mayonnaise (4%)
- E. Oysters (4%)
- F. Raw eggs (4%)
- ✓ G. Undercooked beef (73%)

Omitted
Correct answer
G

73%
Answered correctly

02 secs
Time Spent

01/27/2020
Last Updated

Explanation

Hemolytic uremic syndrome

Hemolytic uremic syndrome	
Etiology	Shiga toxin-producing bacteria • *Escherichia coli* O157:H7 • *Shigella*
Clinical features	• Antecedent diarrheal illness (often bloody) • Hemolytic anemia with schistocytes • Thrombocytopenia • Acute kidney injury

©UWorld

Hemolytic uremic syndrome (HUS) is a major cause of acute renal failure in children. It is characterized by the triad of renal insufficiency, thrombocytopenia, and microangiopathic hemolytic anemia. Most cases occur due to underlying **enterohemorrhagic *Escherichia coli*** (EHEC) infection, particularly with the O157:H7 serotype.

EHEC is a gram-negative, enteric rod that acquires the ability to produce **Shiga toxin** from a lysogenic bacteriophage. Shiga toxin enters the cytosol of host cells and cleaves a protein motif off the 60S ribosomal subunit, which irreversibly halts host protein synthesis and causes cell death. Toxin-mediated injury to the colonic mucosa and the colonic capillaries causes abdominal pain and **bloody diarrhea**. The absorption of Shiga toxin into the systemic circulation causes glomerular (renal insufficiency) and vascular (thrombocytopenia, microangiopathic hemolytic anemia) injury in a minority of patients, leading to HUS.

The primary reservoir for EHEC is the gastrointestinal tract of healthy cattle. Humans primarily acquire the organism after consuming contaminated, **undercooked beef**. Because low infectious doses (10-100 organisms) are required for disease, meatpacking facilities that process high volumes of ground beef are an important source of outbreaks. Other less common routes of transmission include person-to-person contact and fruits and vegetables contaminated with manure.

(Choice A) Canned foods that are contaminated with *Clostridium botulinum* can be associated with foodborne illness due to the consumption of

EHEC is a gram-negative, enteric rod that acquires the ability to produce **Shiga toxin** from a lysogenic bacteriophage. Shiga toxin enters the cytosol of host cells and cleaves a protein motif off the 60S ribosomal subunit, which irreversibly halts host protein synthesis and causes cell death. Toxin-mediated injury to the colonic mucosa and the colonic capillaries causes abdominal pain and **bloody diarrhea**. The absorption of Shiga toxin into the systemic circulation causes glomerular (renal insufficiency) and vascular (thrombocytopenia, microangiopathic hemolytic anemia) injury in a minority of patients, leading to HUS.

The primary reservoir for EHEC is the gastrointestinal tract of healthy cattle. Humans primarily acquire the organism after consuming contaminated, **undercooked beef**. Because low infectious doses (10-100 organisms) are required for disease, meatpacking facilities that process high volumes of ground beef are an important source of outbreaks. Other less common routes of transmission include person-to-person contact and fruits and vegetables contaminated with manure.

(Choice A) Canned foods that are contaminated with *Clostridium botulinum* can be associated with foodborne illness due to the consumption of preformed botulism toxin. Patients typically develop descending, symmetric paralysis.

(Choices B and D) The consumption of preformed, heat-stable *Staphylococcus aureus* enterotoxin causes self-limited nausea, vomiting, and abdominal cramping 1-6 hours after ingestion. Dairy (eg, custard), produce, meats, eggs (eg, mayonnaise), and salads are common culprits and are usually inoculated during preparation by a food handler.

(Choice C) *Bacillus cereus* enterotoxin is classically associated with reheated rice. It causes a vomiting-predominant, foodborne illness that clinically resembles the illness seen with *S aureus* enterotoxin.

(Choice E) Consumption of raw oysters can lead to infection with *Vibrio parahaemolyticus* (which causes voluminous watery diarrhea similar to cholera) and *Vibrio vulnificus* (which causes sepsis with high mortality), as well as other *Vibrio* infections.

(Choice F) The consumption of raw eggs or incompletely cooked poultry can lead to *Salmonella* gastroenteritis, which usually causes watery diarrhea, abdominal cramping, vomiting, and fever.

Educational objective:
Enterohemorrhagic *Escherichia coli* (EHEC) is primarily contracted after eating undercooked ground beef. EHEC produces Shiga toxin, which causes hemorrhagic colitis and can lead to hemolytic-uremic syndrome (HUS). HUS is characterized by acute renal failure, thrombocytopenia,

The primary reservoir for EHEC is the gastrointestinal tract of healthy cattle. Humans primarily acquire the organism after consuming contaminated, **undercooked beef**. Because low infectious doses (10-100 organisms) are required for disease, meatpacking facilities that process high volumes of ground beef are an important source of outbreaks. Other less common routes of transmission include person-to-person contact and fruits and vegetables contaminated with manure.

(Choice A) Canned foods that are contaminated with *Clostridium botulinum* can be associated with foodborne illness due to the consumption of preformed botulism toxin. Patients typically develop descending, symmetric paralysis.

(Choices B and D) The consumption of preformed, heat-stable *Staphylococcus aureus* enterotoxin causes self-limited nausea, vomiting, and abdominal cramping 1-6 hours after ingestion. Dairy (eg, custard), produce, meats, eggs (eg, mayonnaise), and salads are common culprits and are usually inoculated during preparation by a food handler.

(Choice C) *Bacillus cereus* enterotoxin is classically associated with reheated rice. It causes a vomiting-predominant, foodborne illness that clinically resembles the illness seen with *S aureus* enterotoxin.

(Choice E) Consumption of raw oysters can lead to infection with *Vibrio parahaemolyticus* (which causes voluminous watery diarrhea similar to cholera) and *Vibrio vulnificus* (which causes sepsis with high mortality), as well as other *Vibrio* infections.

(Choice F) The consumption of raw eggs or incompletely cooked poultry can lead to *Salmonella* gastroenteritis, which usually causes watery diarrhea, abdominal cramping, vomiting, and fever.

Educational objective:
Enterohemorrhagic *Escherichia coli* (EHEC) is primarily contracted after eating undercooked ground beef. EHEC produces Shiga toxin, which causes hemorrhagic colitis and can lead to hemolytic-uremic syndrome (HUS). HUS is characterized by acute renal failure, thrombocytopenia, and microangiopathic hemolytic anemia; children age <10 are at greatest risk.

Microbiology	Hematology & Oncology	Acute diarrhea
Subject	System	Topic

Copyright © UWorld. All rights reserved.

1 2 3 4 5 6 7 8 9 10 11 12 13 14 15 16 17 18 19 20 21 22 23 24 25 26 27 28 29 30

A 28-year-old man comes to the emergency department due to 2 weeks of headaches, fever, and episodes of inattentiveness. The patient has a history of Hodgkin lymphoma and is undergoing treatment with combination chemotherapy. Temperature is 38.2 C (100.8 F), blood pressure is 138/84 mm Hg, and pulse is 72/min. Lumbar puncture reveals an elevated opening pressure, and cerebrospinal fluid analysis shows moderately increased protein levels and low glucose levels. Light microscopy of the cerebrospinal fluid is shown in the image.

Which of the following should be included in initial treatment for this patient's current condition?

- A. Amphotericin B
- B. Ampicillin
- C. Ceftriaxone
- D. Ganciclovir
- E. Pyrimethamine
- F. Voriconazole

Submit

A 28-year-old man comes to the emergency department due to 2 weeks of headaches, fever, and episodes of inattentiveness. The patient has a history of Hodgkin lymphoma and is undergoing treatment with combination chemotherapy. Temperature is 38.2 C (100.8 F), blood pressure is 138/84 mm Hg, and pulse is 72/min. Lumbar puncture reveals an elevated opening pressure, and cerebrospinal fluid analysis shows moderately increased protein levels and low glucose levels. Light microscopy of the cerebrospinal fluid is shown in the image.

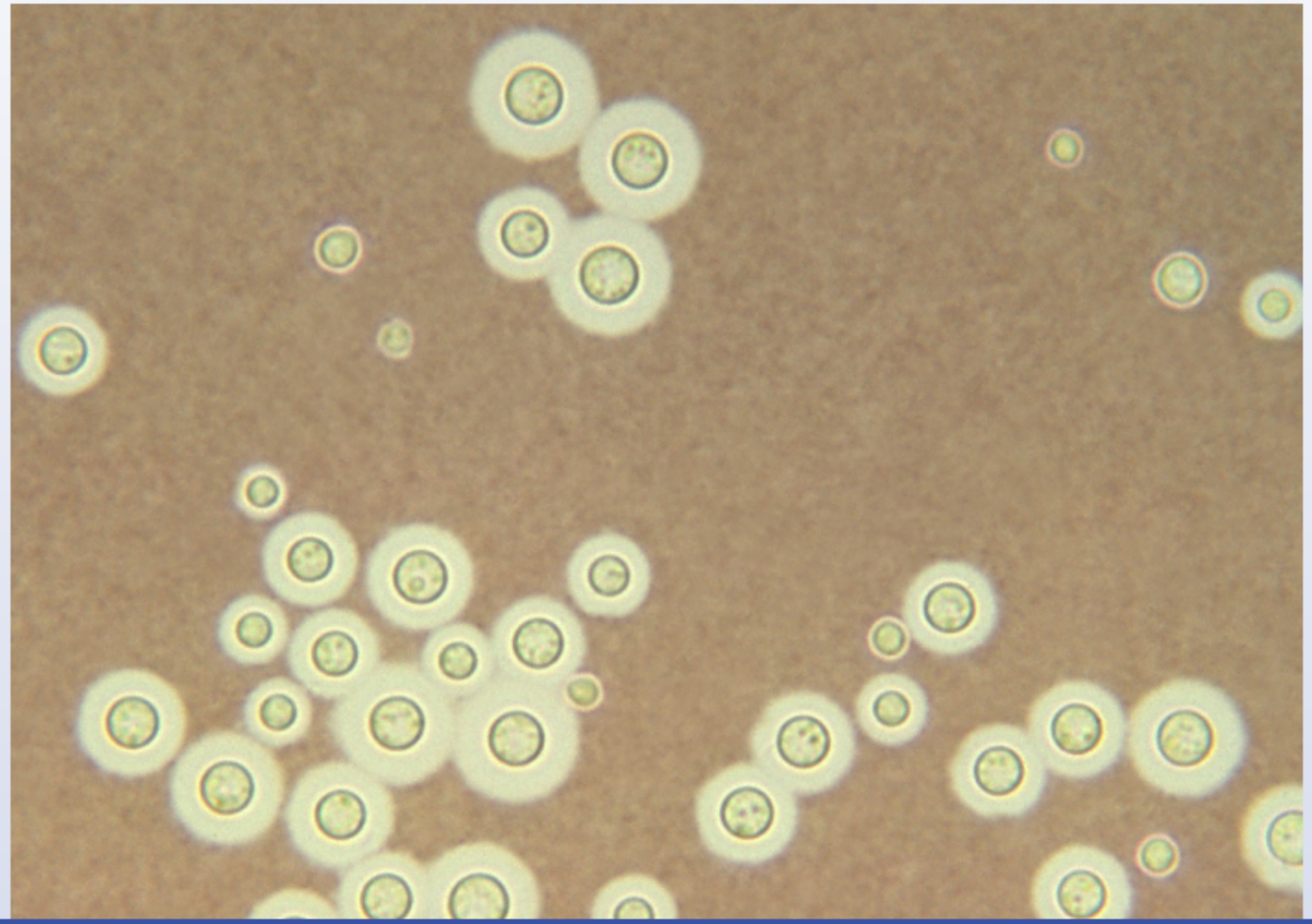

1
2
3
4
5
6
7
8
9
10
11
12
13
14
15
16
17
18
19
20
21
22
23
24
25
26
27
28
29
30

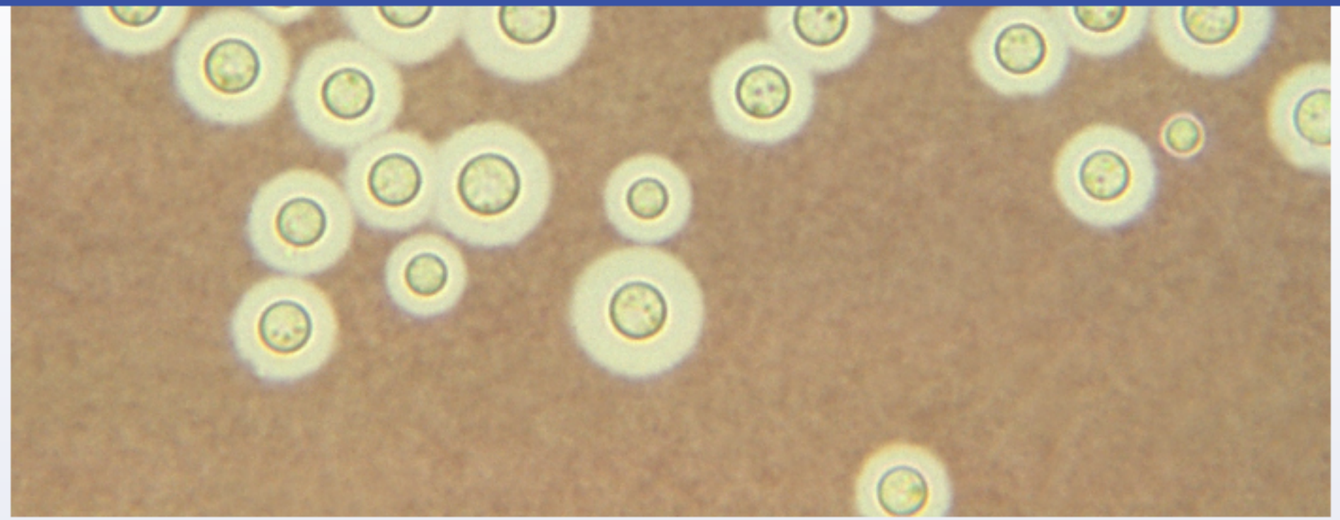

Which of the following should be included in initial treatment for this patient's current condition?

A. Amphotericin B

B. Ampicillin

C. Ceftriaxone

D. Ganciclovir

E. Pyrimethamine

F. Voriconazole

Submit

1 2 3 4 5 6 7 8 9 10 11 12 13 14 15 16 17 18 19 20 21 22 23 24 25 26 27 28 29 30

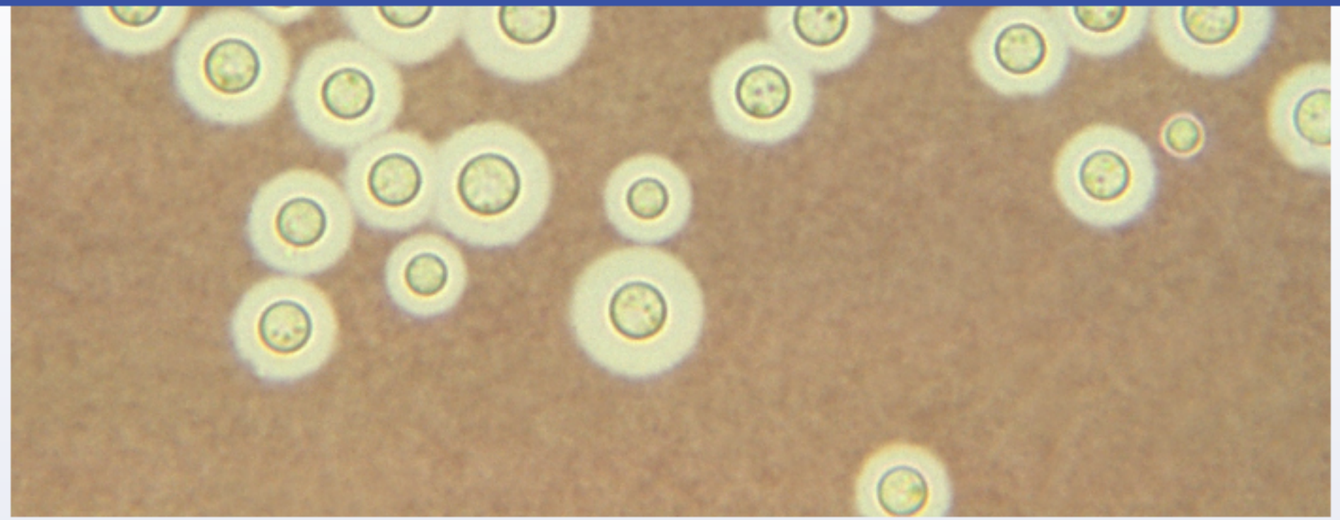

Which of the following should be included in initial treatment for this patient's current condition?

- ✓ A. Amphotericin B (82%)
- B. Ampicillin (1%)
- C. Ceftriaxone (5%)
- D. Ganciclovir (3%)
- E. Pyrimethamine (2%)
- F. Voriconazole (5%)

Omitted
Correct answer

82%
Answered correctly

06 secs
Time Spent

02/27/2020
Last Updated

Explanation

Clinical features of cryptococcal meningoencephalitis	
Presentation	• Headache, fever & lethargy typically developing over 2 weeks, sometimes longer • Symptoms often more acute & severe in HIV patients
Diagnosis	• Lumbar puncture showing low glucose & increased protein; leukocyte count particularly low in HIV patients • Transparent capsule seen on India ink staining • Cryptococcal antigen detected in cerebrospinal fluid • Culture on Sabouraud agar
Treatment	• Initial treatment: Amphotericin B & flucytosine • Long-term maintenance therapy: Fluconazole

Cryptococcus neoformans is an opportunistic yeast that can be visualized with **India ink staining**. India ink stains the background of the slide black, which allows the **thick polysaccharide capsule** of the yeast to be visualized (clear halo between the dark background and the black center of the organism). India ink staining of the cerebrospinal fluid (CSF) is a common diagnostic modality in those with suspected cryptococcal meningitis. However, CSF cryptococcal (polysaccharide) antigen testing is more sensitive and specific, so it is also usually performed. Culture of the fungus on **Sabouraud agar** confirms the diagnosis.

Patients with cryptococcal meningitis usually develop slowly worsening headache, fever, and lethargy. Immunocompromised individuals are at greatest risk, particularly those who have AIDS or hematologic cancers or patients on chronic glucocorticoids. CSF analysis usually shows low glucose, increased protein, and mild pleocytosis with a predominance of lymphocytes. Initial treatment involves induction therapy with **amphotericin B** and flucytosine. Once patients are stabilized, they are switched to long-term maintenance therapy with fluconazole.

(Choices B and C) Ampicillin is used to treat *Listeria* meningitis; *Listeria* is a gram-positive rod with characteristic tumbling motility on light microscopy. Ceftriaxone can treat pneumococcal and *Haemophilus influenzae* meningitis. Ampicillin and ceftriaxone are beta-lactam antibiotics

	• Long-term maintenance therapy: Fluconazole

Cryptococcus neoformans is an opportunistic yeast that can be visualized with **India ink staining**. India ink stains the background of the slide black, which allows the **thick polysaccharide capsule** of the yeast to be visualized (clear halo between the dark background and the black center of the organism). India ink staining of the cerebrospinal fluid (CSF) is a common diagnostic modality in those with suspected cryptococcal meningitis. However, CSF cryptococcal (polysaccharide) antigen testing is more sensitive and specific, so it is also usually performed. Culture of the fungus on **Sabouraud agar** confirms the diagnosis.

Patients with cryptococcal meningitis usually develop slowly worsening headache, fever, and lethargy. Immunocompromised individuals are at greatest risk, particularly those who have AIDS or hematologic cancers or patients on chronic glucocorticoids. CSF analysis usually shows low glucose, increased protein, and mild pleocytosis with a predominance of lymphocytes. Initial treatment involves induction therapy with **amphotericin B** and flucytosine. Once patients are stabilized, they are switched to long-term maintenance therapy with fluconazole.

(Choices B and C) Ampicillin is used to treat *Listeria* meningitis; *Listeria* is a gram-positive rod with characteristic tumbling motility on light microscopy. Ceftriaxone can treat pneumococcal and *Haemophilus influenzae* meningitis. Ampicillin and ceftriaxone are beta-lactam antibiotics that inhibit peptidoglycan cross-linking and lead to bactericidal effects. Fungi cannot be treated with beta-lactam antibiotics as their cell walls do not contain peptidoglycan.

(Choice D) Ganciclovir inhibits viral DNA synthesis and is used to treat cytomegalovirus meningoencephalitis, which is diagnosed using PCR.

(Choice E) Pyrimethamine is an antifolate agent used in the treatment of malaria and toxoplasmosis.

(Choice F) Azole drugs inhibit the synthesis of ergosterol, a crucial fungal cell membrane component. Spectrum of activity varies based on the particular agent; voriconazole is most effective against *Aspergillus*. Fluconazole is used for long-term maintenance therapy in cryptococcal meningitis, but is fungistatic at typically used doses and is less effective than amphotericin B for initial treatment.

Educational objective:
Patients with suspected cryptococcal meningitis can be diagnosed using India ink staining of the cerebrospinal fluid. Treatment with amphotericin B and flucytosine is required at first, followed by long-term fluconazole maintenance therapy.

1
2
3
4
5
6
7
8
9
10
11
12
13
14
15
16
17
18
19
20
21
22
23
24
25
26
27
28
29
30

of the organism). India ink staining of the cerebrospinal fluid (CSF) is a common diagnostic modality in those with suspected cryptococcal meningitis. However, CSF cryptococcal (polysaccharide) antigen testing is more sensitive and specific, so it is also usually performed. Culture of the fungus on **Sabouraud agar** confirms the diagnosis.

Patients with cryptococcal meningitis usually develop slowly worsening headache, fever, and lethargy. Immunocompromised individuals are at greatest risk, particularly those who have AIDS or hematologic cancers or patients on chronic glucocorticoids. CSF analysis usually shows low glucose, increased protein, and mild pleocytosis with a predominance of lymphocytes. Initial treatment involves induction therapy with **amphotericin B** and flucytosine. Once patients are stabilized, they are switched to long-term maintenance therapy with fluconazole.

(Choices B and C) Ampicillin is used to treat *Listeria* meningitis; *Listeria* is a gram-positive rod with characteristic tumbling motility on light microscopy. Ceftriaxone can treat pneumococcal and *Haemophilus influenzae* meningitis. Ampicillin and ceftriaxone are beta-lactam antibiotics that inhibit peptidoglycan cross-linking and lead to bactericidal effects. Fungi cannot be treated with beta-lactam antibiotics as their cell walls do not contain peptidoglycan.

(Choice D) Ganciclovir inhibits viral DNA synthesis and is used to treat cytomegalovirus meningoencephalitis, which is diagnosed using PCR.

(Choice E) Pyrimethamine is an antifolate agent used in the treatment of malaria and toxoplasmosis.

(Choice F) Azole drugs inhibit the synthesis of ergosterol, a crucial fungal cell membrane component. Spectrum of activity varies based on the particular agent; voriconazole is most effective against *Aspergillus*. Fluconazole is used for long-term maintenance therapy in cryptococcal meningitis, but is fungistatic at typically used doses and is less effective than amphotericin B for initial treatment.

Educational objective:
Patients with suspected cryptococcal meningitis can be diagnosed using India ink staining of the cerebrospinal fluid. Treatment with amphotericin B and flucytosine is required at first, followed by long-term fluconazole maintenance therapy.

Microbiology	Nervous System	Meningitis
Subject	System	Topic

Copyright © UWorld. All rights reserved.

1 2 3 4 5 6 7 8 9 10 11 12 13 14 15 16 17 18 19 20 21 22 23 24 25 26 27 28 29 30

A 34-year-old man comes to the emergency department due to 2 weeks of slowly progressive global headache, malaise, and fevers. He has also had unintentional weight loss over the past several months. The patient has a history of injection drug use and was diagnosed with HIV 3 years ago; he has not been compliant with antiretroviral therapy. Temperature is 38.3 C (100.9 F). Examination shows white patches on the oropharyngeal mucosa and mild generalized lymphadenopathy. Brain imaging reveals no intracranial mass. India ink staining of cerebrospinal fluid obtained via lumbar puncture demonstrates spherical yeast forms with thick capsules. Which of the following is most likely to have been the site of primary infection in this patient?

- A. Intestine
- B. Lungs
- C. Nasopharynx
- D. Oral cavity
- E. Skin
- F. Urinary tract

Submit

1 2 3 4 5 6 7 8 9 10 11 12 13 14 15 16 17 18 19 20 21 22 23 24 25 26 27 28 29 30

A 34-year-old man comes to the emergency department due to 2 weeks of slowly progressive global headache, malaise, and fevers. He has also had unintentional weight loss over the past several months. The patient has a history of injection drug use and was diagnosed with HIV 3 years ago; he has not been compliant with antiretroviral therapy. Temperature is 38.3 C (100.9 F). Examination shows white patches on the oropharyngeal mucosa and mild generalized lymphadenopathy. Brain imaging reveals no intracranial mass. India ink staining of cerebrospinal fluid obtained via lumbar puncture demonstrates spherical yeast forms with thick capsules. Which of the following is most likely to have been the site of primary infection in this patient?

- A. Intestine (1%)
- ✓ B. Lungs (62%)
- C. Nasopharynx (27%)
- D. Oral cavity (6%)
- E. Skin (2%)
- F. Urinary tract (0%)

Omitted
Correct answer
B

62%
Answered correctly

02 secs
Time Spent

02/27/2020
Last Updated

Explanation

Cryptococcus neoformans is a yeast with a **thick polysaccharide capsule** that causes opportunistic infections in patients with advanced immunosuppression, particularly those with untreated **AIDS**. This pathogen is found in the environment in soil contaminated by bird droppings

Cryptococcus neoformans is a yeast with a **thick polysaccharide capsule** that causes opportunistic infections in patients with advanced immunosuppression, particularly those with untreated **AIDS**. This pathogen is found in the environment in soil contaminated by bird droppings (eg, pigeons) and is inhaled into the alveoli of the **lungs**, where it establishes a (usually) asymptomatic primary infection.

Cryptococcal meningitis occurs when *C neoformans* spreads from the lungs into the circulation and then penetrates the endothelial cells of the cerebral capillaries. Replication within the cerebrospinal fluid (CSF) leads to slowly worsening headache, fever, and confusion. Visualization of the organism on CSF samples using India ink stain (round/oval yeast with a thick capsule) confirms the diagnosis. Most patients also undergo polysaccharide antigen (cryptococcal antigen) testing using latex agglutination.

(Choice C) Acute bacterial meningitis is caused primarily by pathogens (eg, *Streptococcus pneumoniae*, *Neisseria meningitidis*, *Haemophilus influenzae*) that colonize the nasopharynx. Manifestations of acute bacterial meningitis usually include the rapid onset of high fever, neck stiffness, and altered mental state. Bacteria are not seen on India ink stain.

(Choice D) Patients who have untreated AIDS often develop multiple opportunistic infections; the white patches on this patient's oral mucosa likely indicate oropharyngeal candidiasis. Superficial *Candida* infections rarely cause invasive disease. In addition, *Candida* does not have a thick polysaccharide capsule and is not seen on India ink stain.

Educational objective:
Cryptococcus neoformans is a yeast with a thick polysaccharide capsule that is found primarily in soil contaminated by bird droppings. Inhalation of the pathogen into the lungs leads to (a usually asymptomatic) primary infection. In patients who are immunocompromised (eg, advanced AIDS), the pathogen can spread through the bloodstream to other organs, particularly the central nervous system.

References

- Molecular mechanisms of cryptococcal meningitis.

Microbiology	Nervous System	Meningitis
Subject	System	Topic

Copyright © UWorld. All rights reserved.

Settings

1
2
3
4
5
6
7
8
9
10
11
12
13
14
15
16
17
18
19
20
21
22
23
24
25
26
27
28
29
30

Item 22 of 38
Question Id: 113

Mark | Previous | Next | Full Screen | Tutorial | Lab Values | Notes | Calculator | Reverse Color | Text Zoom | Settings

Cryptococcus neoformans is a yeast with a **thick polysaccharide capsule** that causes opportunistic infections in patients with advanced

Exhibit Display

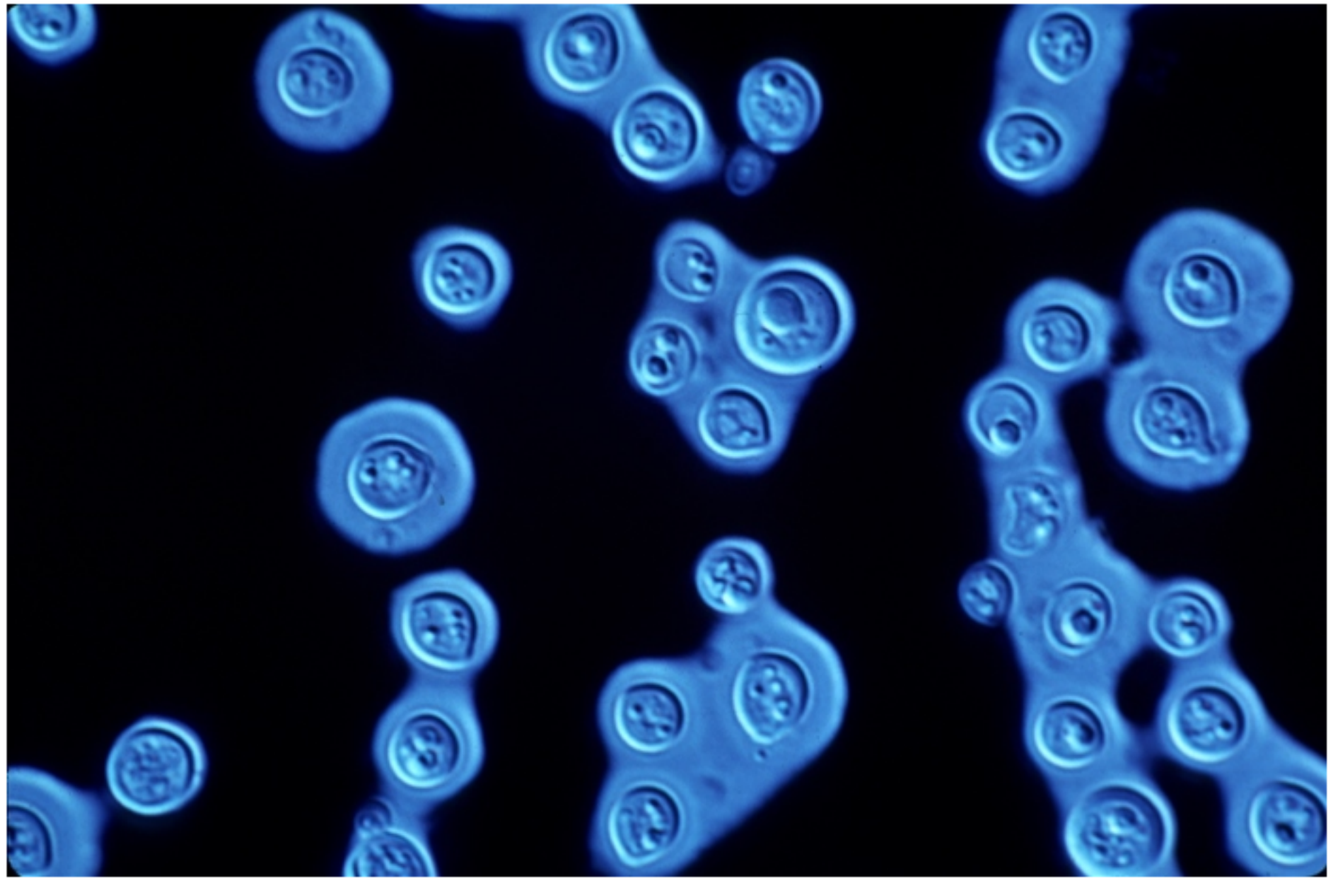

Zoom In | Zoom Out | Reset | Add To New Card | Existing Card

Block Time Remaining: 00:01:22
TUTOR

2 | Feedback | Suspend | End Block

A 46-year-old man comes to the emergency department due to worsening blurry vision, difficulty swallowing, and dry mouth for the past hour. He has also been having nausea and abdominal discomfort but has no headache or fever. The patient has no prior medical conditions and takes no medications. He smokes a pack of cigarettes daily but does not use alcohol or illicit drugs. The patient has not traveled recently but attended a community potluck event yesterday where he sampled home-canned foods. Physical examination shows bilateral ptosis and sluggish pupillary response. Which of the following steps in neuromuscular transmission is most likely affected in this patient?

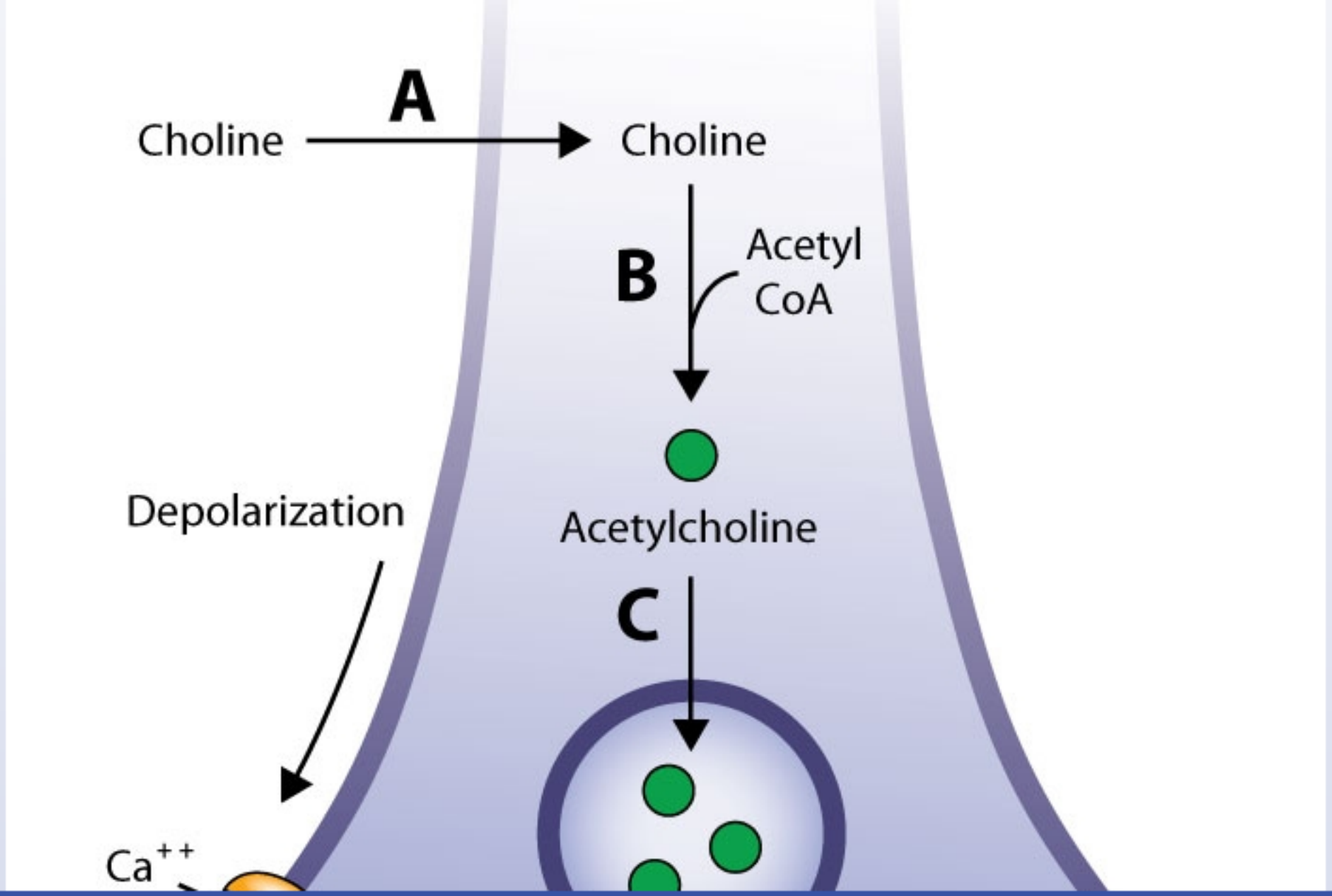

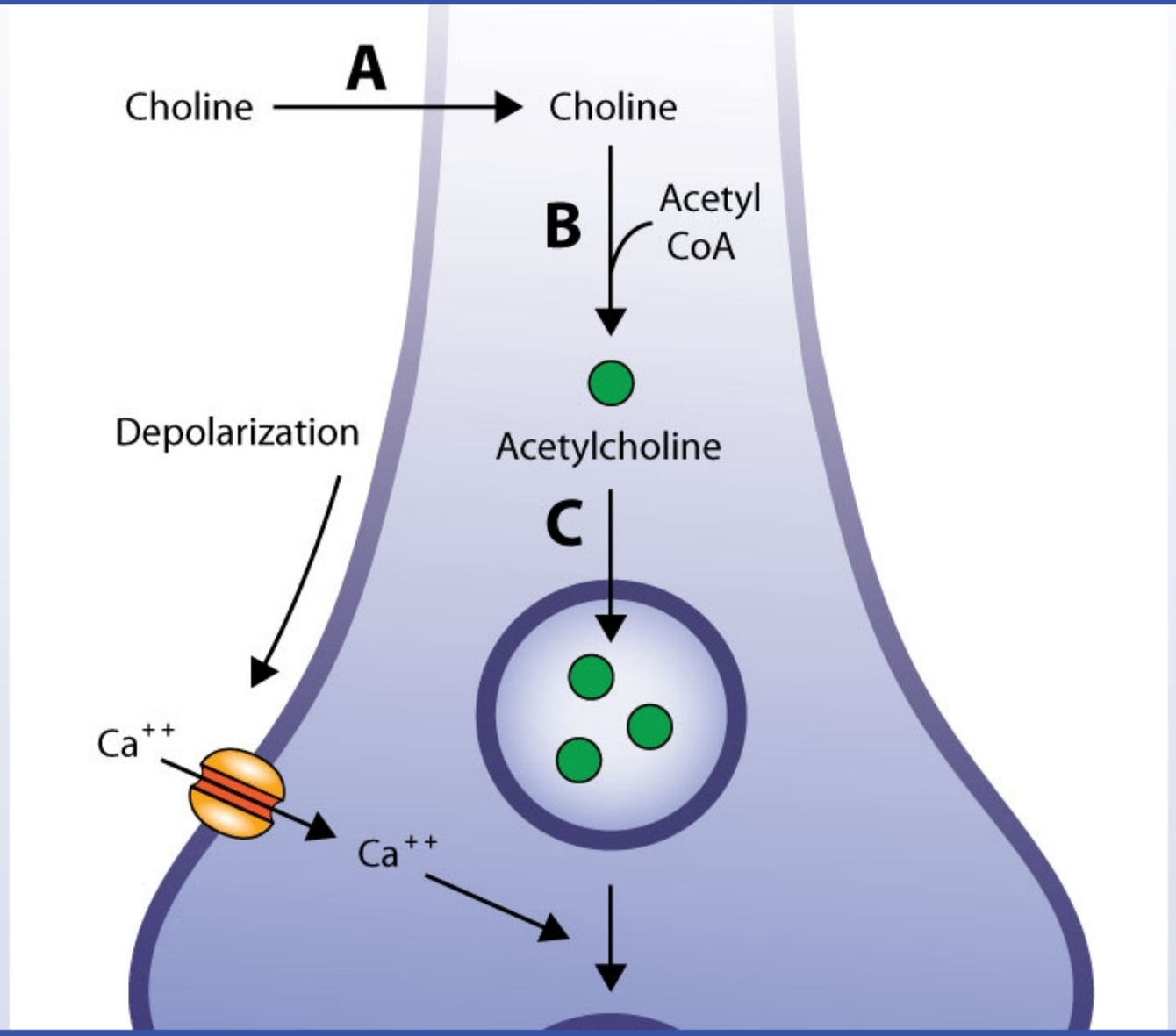
A
Choline
Choline
B
Acetyl
CoA
Acetylcholine
Depolarization
C
Ca++
Ca++

Settings

1
2
3
4
5
6
7
8
9
10
11
12
13
14
15
16
17
18
19
20
21
22
23
24
25
26
27
28
29
30

Item 23 of 38
Question Id: 1997

Mark | Previous | Next | Full Screen | Tutorial | Lab Values | Notes | Calculator | Reverse Color | Text Zoom | Settings

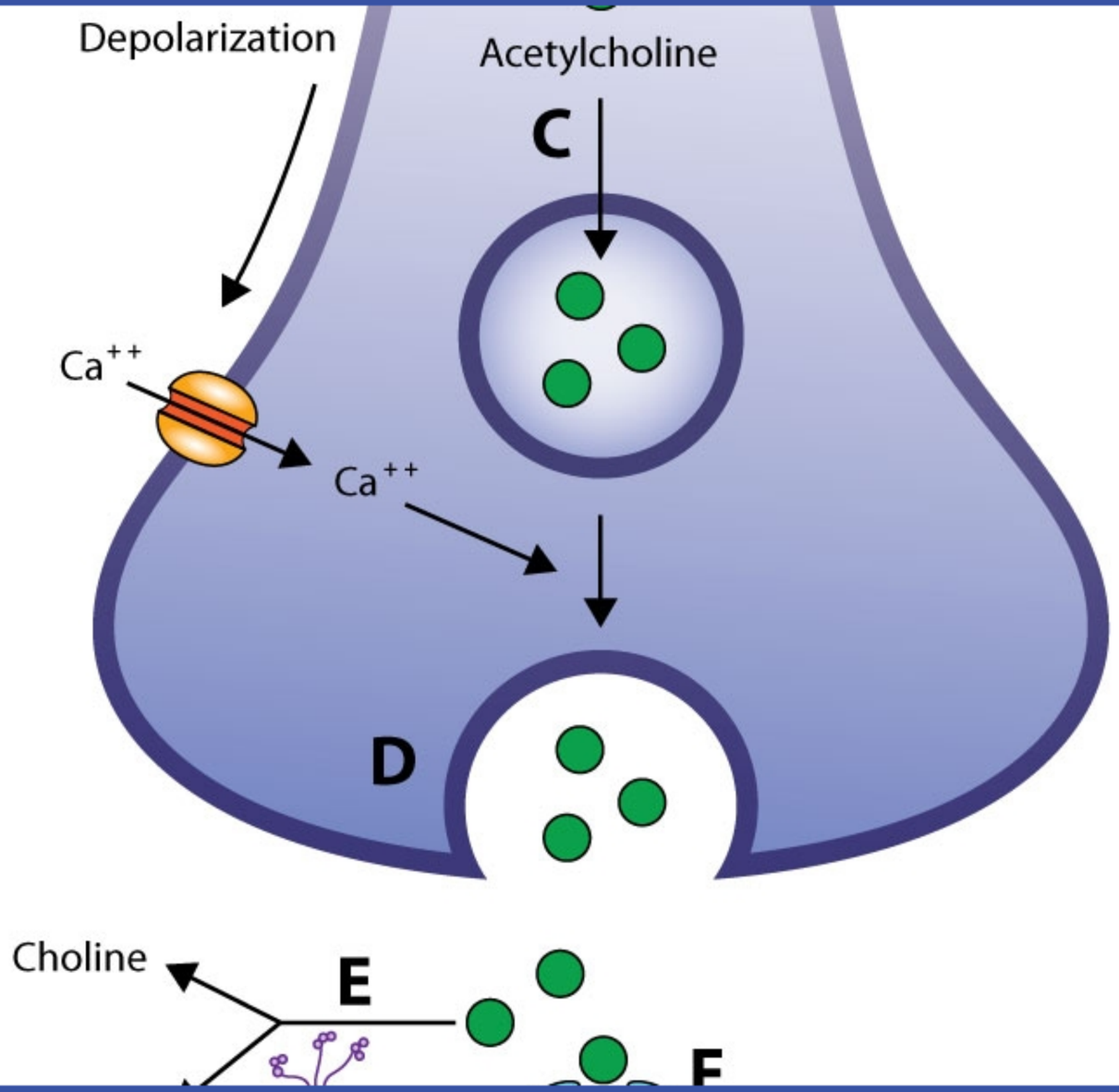

Block Time Remaining: 00:01:28
TUTOR

6 | Feedback | Suspend | End Block

1 2 3 4 5 6 7 8 9 10 11 12 13 14 15 16 17 18 19 20 21 22 23 24 25 26 27 28 29 30

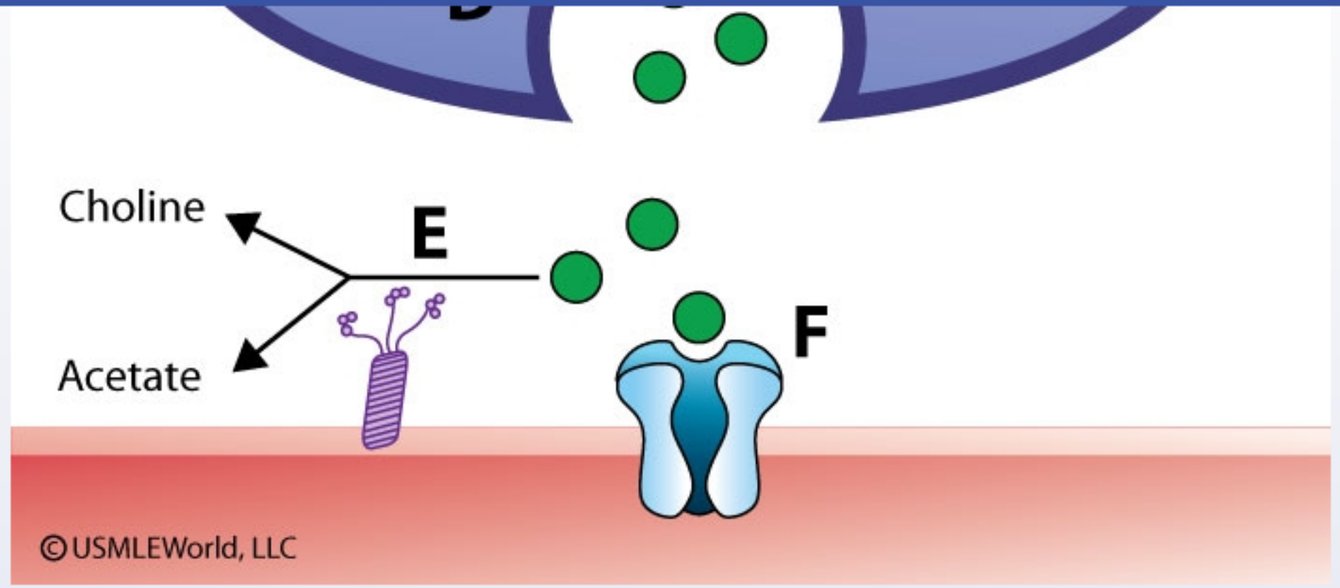

A. A
B. B
C. C
D. D
E. E
F. F

Submit

Settings

1 2 3 4 5 6 7 8 9 10 11 12 13 14 15 16 17 18 19 20 21 22 23 24 25 26 27 28 29 30

Item 23 of 38
Question Id: 1997

Mark | Previous | Next | Full Screen | Tutorial | Lab Values | Notes | Calculator | Reverse Color | Text Zoom | Settings

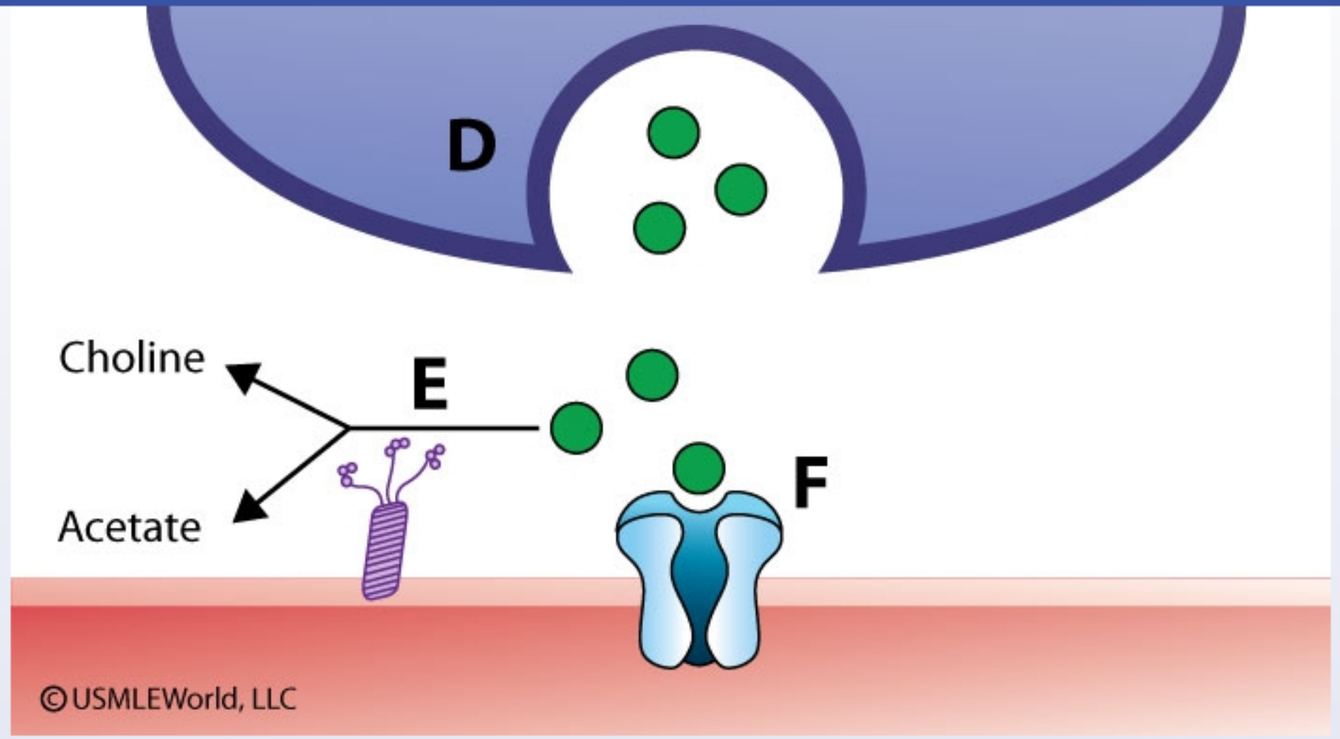

A. A (0%)
B. B (0%)
C. C (4%)
✓ D. D (75%)
E. E (7%)
F. F (11%)

Block Time Remaining: 00:01:32
TUTOR

6 | Feedback | Suspend | End Block

Settings

1 2 3 4 5 6 7 8 9 10 11 12 13 14 15 16 17 18 19 20 21 22 23 24 25 26 27 28 29 30

Item 23 of 38
Question Id: 1997

Mark | Previous | Next | Full Screen | Tutorial | Lab Values | Notes | Calculator | Reverse Color | Text Zoom | Settings

Exhibit Display

Inhibitors of acetylcholine neurotransmission

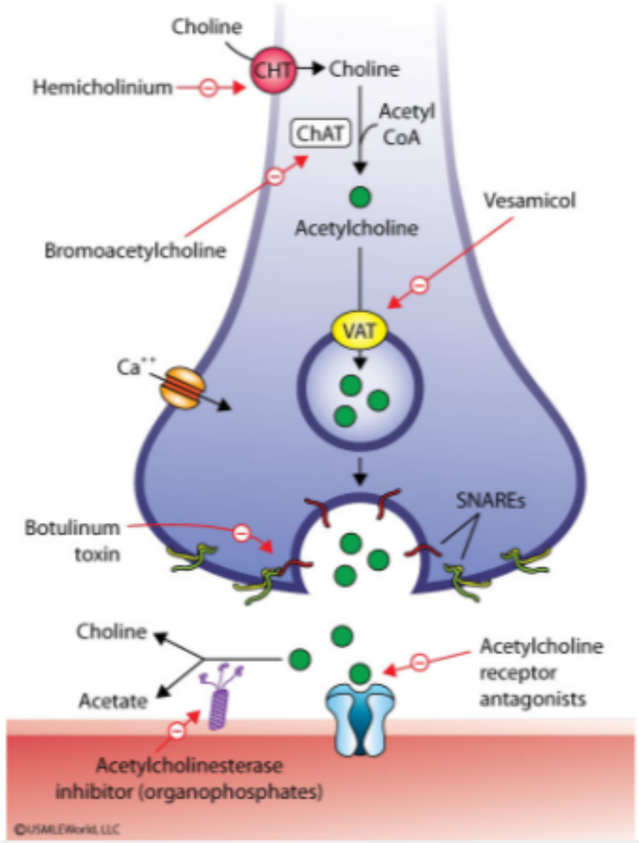

Zoom In | Zoom Out | Reset | Add To New Card | Existing Card

Block Time Remaining: 00:01:32
TUTOR

6 | Feedback | Suspend | End Block

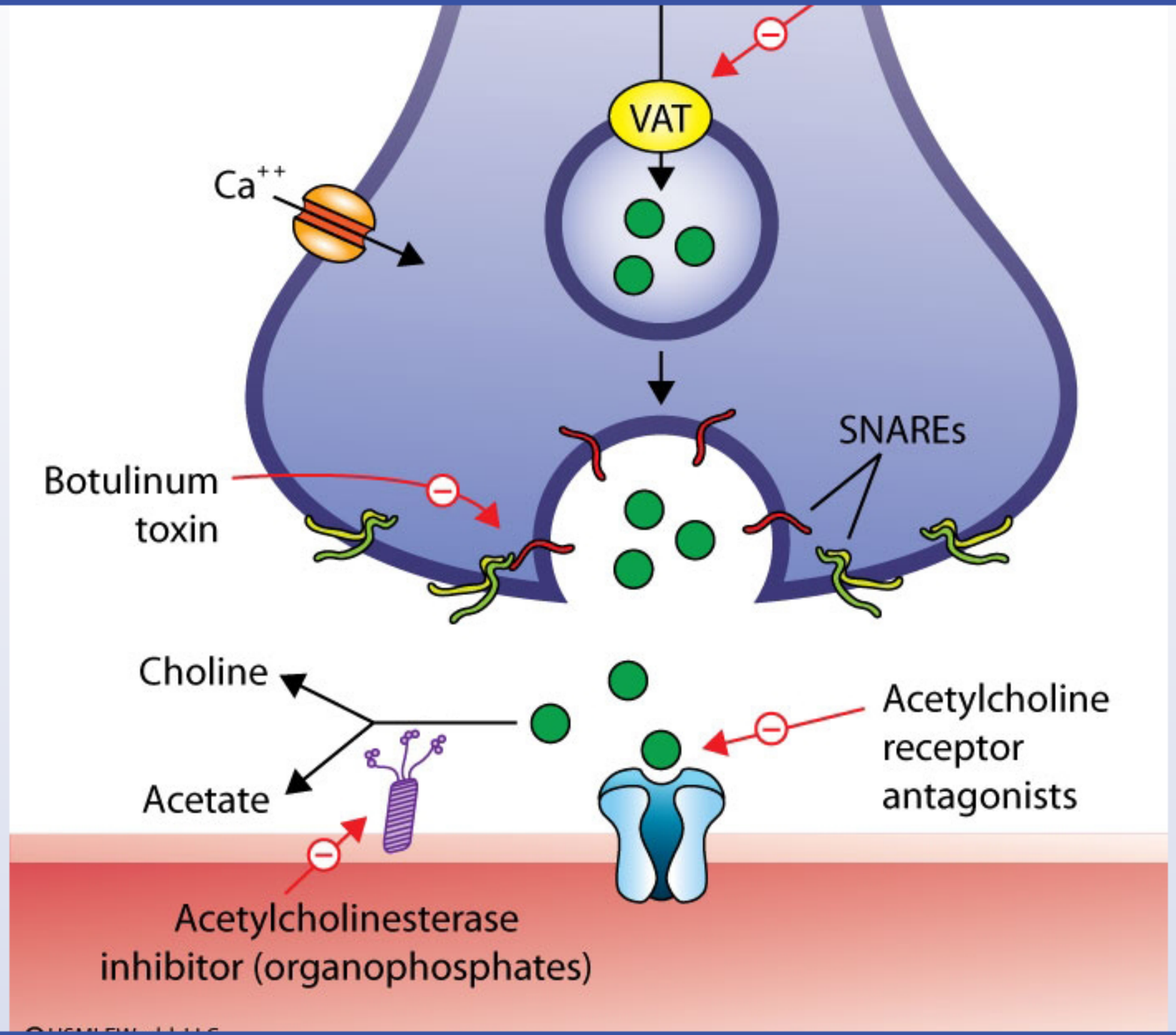
VAT
Ca++
SNAREs
Botulinum toxin
Choline
Acetate
Acetylcholine receptor antagonists
Acetylcholinesterase inhibitor (organophosphates)

This patient with gastrointestinal discomfort has manifestations of both **nicotinic** blockade (eg, dysphagia, ptosis) and **muscarinic blockade** (eg, dry mouth) that developed after eating home-canned food. This is strongly suggestive of food poisoning with ***Clostridium botulinum* toxin**, a preformed neurotoxin. Botulism characteristically presents as a symmetric, descending paralysis that first manifests with cranial nerve abnormalities (**diplopia, dysphagia, dysphonia ["3Ds"]**). Nausea, vomiting, and abdominal pain may also occur in foodborne botulism, which classically occurs 12-36 hours after consumption of contaminated, **home-canned foods**.

Botulinum toxin causes disease by inhibiting cholinergic nerves, including nicotinic and muscarinic motor neurons. It enters the nerve terminals through endocytosis, where it prevents binding and fusion of acetylcholine (ACh)-containing synaptic vesicles with the plasma membrane through the destruction of SNARE proteins. This effectively blocks ACh release into the neuromuscular synapse. Botulinum toxin is highly potent; a very small quantity can be lethal without ventilatory support. The toxin is **heat-labile**, so disease can be prevented by thoroughly heating food prior to consumption.

(Choice A) Hemicholinium blocks choline uptake by the presynaptic neuron, preventing ACh synthesis through depletion of intracellular choline.

(Choice B) Bromoacetylcholine inhibits choline acetyltransferase, blocking the synthesis of ACh from acetate and choline.

(Choice C) Vesamicol noncompetitively blocks the vesicular ACh transporter, preventing ACh from entering secretory vesicles in the presynaptic nerve terminal.

(Choice E) Acetylcholinesterase inhibitors such as organophosphates (commonly used as insecticides) prevent ACh breakdown. Manifestations of organophosphate poisoning reflect depolarizing blockade (eg, muscle weakness, fasciculations, paralysis), central nervous system effects (eg, lethargy, seizures), and muscarinic overstimulation (eg, miosis, bradycardia, increased lacrimation and salivation).

(Choice F) Anticholinergic poisoning due to competitive antagonists of muscarinic ACh receptors (eg, atropine, scopolamine) is relatively common and can manifest as cutaneous vasodilation, anhidrosis, hyperthermia, mydriasis, and delirium. However, these agents have no effect on the nicotinic ACh receptors controlling voluntary muscles. Poisoning due to **nicotinic** receptor antagonists (eg, pancuronium, tubocurarine) is uncommon as these agents have poor oral absorption.

Educational objective:
Botulinum toxin blocks the presynaptic exocytosis of ACh vesicles, causing impaired muscarinic and nicotinic neurotransmission; it characteristically presents as a symmetric, descending paralysis that first manifests with cranial nerve abnormalities, often following consumption

consumption.

(Choice A) Hemicholinium blocks choline uptake by the presynaptic neuron, preventing ACh synthesis through depletion of intracellular choline.

(Choice B) Bromoacetylcholine inhibits choline acetyltransferase, blocking the synthesis of ACh from acetate and choline.

(Choice C) Vesamicol noncompetitively blocks the vesicular ACh transporter, preventing ACh from entering secretory vesicles in the presynaptic nerve terminal.

(Choice E) Acetylcholinesterase inhibitors such as organophosphates (commonly used as insecticides) prevent ACh breakdown. Manifestations of organophosphate poisoning reflect depolarizing blockade (eg, muscle weakness, fasciculations, paralysis), central nervous system effects (eg, lethargy, seizures), and muscarinic overstimulation (eg, miosis, bradycardia, increased lacrimation and salivation).

(Choice F) Anticholinergic poisoning due to competitive antagonists of muscarinic ACh receptors (eg, atropine, scopolamine) is relatively common and can manifest as cutaneous vasodilation, anhidrosis, hyperthermia, mydriasis, and delirium. However, these agents have no effect on the nicotinic ACh receptors controlling voluntary muscles. Poisoning due to **nicotinic** receptor antagonists (eg, pancuronium, tubocurarine) is uncommon as these agents have poor oral absorption.

Educational objective:
Botulinum toxin blocks the presynaptic exocytosis of ACh vesicles, causing impaired muscarinic and nicotinic neurotransmission; it characteristically presents as a symmetric, descending paralysis that first manifests with cranial nerve abnormalities, often following consumption of home-canned foods.

References

- Large outbreak of botulism associated with a church potluck meal—Ohio, 2015.

Microbiology	Nervous System	Botulism
Subject	System	Topic

Copyright © UWorld. All rights reserved.

Acetylcholinesterase

Exhibit Display

Botulism

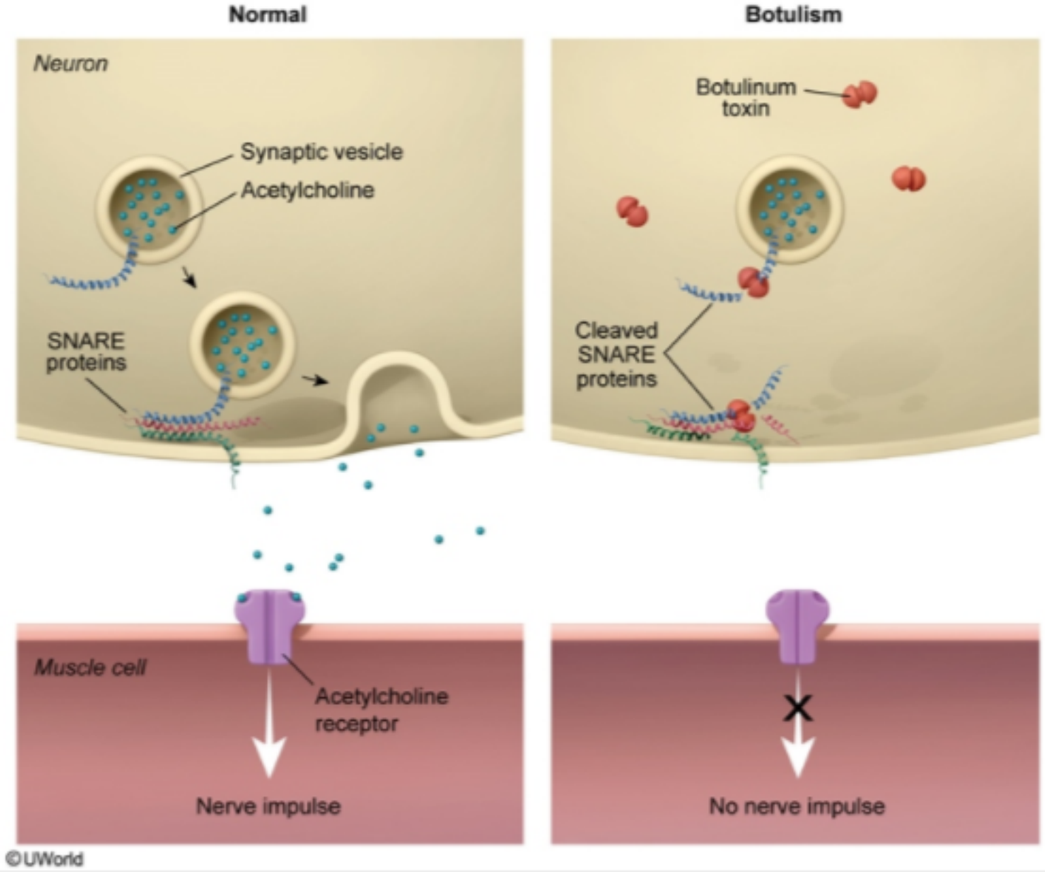

Zoom In | Zoom Out | Reset | Add To New Card | Existing Card

the nicotinic ACh receptors controlling voluntary muscles. Poisoning due to **nicotinic** receptor antagonists (eg, pancuronium, tubocurarine) is

1 2 3 4 5 6 7 8 9 10 11 12 13 14 15 16 17 18 19 20 21 22 23 24 25 26 27 28 29 30

the destruction of SNARE proteins. This effectively blocks ACh release into the neuromuscular synapse. Botulinum toxin is highly potent; a very small quantity can be letha to consumption.

(Choice A) Hemicholiniu e.

(Choice B) Bromoacetylc

(Choice C) Vesamicol no tic nerve terminal.

(Choice E) Acetylcholine ons of organophosphate poisc eg, lethargy, seizures), and m

(Choice F) Anticholinergi common and can manifes t on the nicotinic ACh receptor uncommon as these agen

Educational objective:
Botulinum toxin blocks the characteristically presents on of home-canned foods.

References

- Large outbreak of botu

Microbiology — Subject
Nervo — System
Topic

Exhibit Display

Cholinergic toxicity	
Muscarinic effects **(DUMBELS)**	• **D**iarrhea/diaphoresis • **U**rination • **M**iosis • **B**ronchospasm, bronchorrhea & bradycardia • **E**mesis • **L**acrimation • **S**alivation
Nicotinic effects	• Muscle weakness, paralysis & fasciculations

Add To New Card | Existing Card

the destruction of SNARE proteins. This effectively blocks ACh release into the neuromuscular synapse. Botulinum toxin is highly potent; a very small quantity can be letha to consumption.

(Choice A) Hemicholiniu e.

(Choice B) Bromoacetylc

(Choice C) Vesamicol no tic nerve terminal.

(Choice E) Acetylcholine ons of organophosphate poisc eg, lethargy, seizures), and m

(Choice F) Anticholinergi common and can manifes t on the nicotinic ACh receptor uncommon as these agen

Educational objective:
Botulinum toxin blocks the characteristically presents on of home-canned foods.

References

- Large outbreak of botu

Microbiology — Subject
Nervo — System
Topic

Exhibit Display

Anticholinergic toxicity	
Symptom	**Mechanism**
"Hot as a hare" ↑ Body temperature	↓ Sweating leads to ↓ heat dissipation
"Dry as a bone" ↓ Secretions (eg, mucous membranes, sweat glands)	↓ Glandular secretion & smooth muscle contraction
"Red as a beet" Flushed skin	Superficial vasodilation from ↑ body heat
"Blind as a bat" Cycloplegia, mydriasis	Paralysis of ciliary muscle & iris sphincter
"Mad as a hatter" Altered mental status	Permeates blood-brain barrier & affects CNS pathways
"Full as a flask" Urinary retention Constipation	↓ Detrusor contraction & ↓ internal urethral sphincter relaxation ↓ Intestinal smooth muscle contraction
"Fast as a fiddle" Tachycardia	↓ Vagal tone at the sinoatrial node

Add To New Card | Existing Card

1 2 3 4 5 6 7 8 9 10 11 12 13 14 15 16 17 18 19 20 21 22 23 24 25 26 27 28 29 30

An 8-year-old boy is brought to the emergency department due to 24 hours of fever and chills. Temperature is 38.3 C (101 F). On examination, the patient is lethargic with dry mucous membranes. There are no oropharyngeal lesions, and tympanic membranes are normal. The lungs are clear on auscultation, and heart sounds are normal. The abdomen is soft and nontender. There is no skin rash. Laboratory testing shows a leukocyte count of 24,000/mm^3 with 15% bands, 80% neutrophils, and 5% lymphocytes. Peripheral blood smear is shown in the exhibit. Blood cultures are obtained and intravenous fluids and empiric antibiotics are initiated. The patient's blood cultures are most likely to grow which of the following organisms?

A. *Escherichia coli*

B. *Pseudomonas aeruginosa*

C. *Staphylococcus aureus*

D. *Streptococcus pneumoniae*

E. *Streptococcus pyogenes*

F. Viridans streptococci

Submit

An 8-year-old boy is brought to the emergency department due to 24 hours of fever and chills. Temperature is 38.3 C (101 F). On examination, the patient is lethargic with dry mucous membranes. There are no oropharyngeal lesions, and tympanic membranes are normal. The lungs are clear on auscultation, and heart sounds are normal. The abdomen is soft and nontender. There is no skin rash. Laboratory testing shows a leukocyte count of 24,000/mm^3 with 15% bands, 80% neutrophils, and 5% lymphocytes. Peripheral blood smear is shown in the exhibit. Blood cultures are obtained and intravenous fluids and empiric antibiotics are initiated. The patient's blood cultures are most likely to grow which of the following organisms?

A. *Escherichia coli* (22%)

B. *Pseudomonas aeruginosa* (8%)

C. *Staphylococcus aureus* (11%)

✓ D. *Streptococcus pneumoniae* (47%)

E. *Streptococcus pyogenes* (5%)

F. Viridans streptococci (3%)

Omitted
Correct answer
D

47%
Answered correctly

02 secs
Time Spent

05/31/2020
Last Updated

Explanation

Patients with **sickle cell anemia** have mutations in the beta-globulin gene that cause hemoglobin to reversibly polymerize when deoxygenated, which leads to the formation of sickled-shaped erythrocytes that clog small capillaries and cause end-organ ischemia. The spleen is particularly

Explanation

Patients with **sickle cell anemia** have mutations in the beta-globulin gene that cause hemoglobin to reversibly polymerize when deoxygenated, which leads to the formation of sickled-shaped erythrocytes that clog small capillaries and cause end-organ ischemia. The spleen is particularly vulnerable; repeated microinfarction of splenic vascular beds usually results in **functional asplenia** within the first 18-36 months of life.

Because the spleen produces opsonizing antibodies that are important for clearing **encapsulated bacteria** from the blood, asplenia is associated with significant risk of fulminant bacterial infections. ***Streptococcus pneumoniae*** is the leading pathogen, but *Neisseria meningitidis* and *Haemophilus influenzae* are also frequently isolated. Therefore, patients with sickle cell anemia who present with signs/symptoms of infection (eg, fever, chills, leukocytosis) require urgent empiric antibiotic therapy that covers these pathogens. Vaccination (pneumococcal and *Haemophilus influenzae* type b) is recommended to reduce risk of future infection.

(Choices A, B, C, E, and F) Patients with sickle cell anemia are at increased risk for overwhelming bacterial infections with a variety of pathogens. However, *S pneumoniae* infections are particularly common, accounting for 40%-60% of total bacterial infections in this population. Although *Pseudomonas aeruginosa* is encapsulated, it is not a common pathogen in patients with sickle cell disease (it occurs more often in those with cystic fibrosis, severe chronic obstructive pulmonary disease, and diabetes mellitus). Patients with sickle cell anemia are also particularly prone to salmonella osteomyelitis.

Educational objective:
Patients with sickle cell disease become functionally asplenic within the first few years of life due to repeated microinfarction of splenic vascular beds. This dramatically increases the risk for fulminant infections with encapsulated bacterial organisms, particularly *Streptococcus pneumoniae*. Patients with sickle cell disease are also at increased risk for other bacterial infections, most notably salmonella osteomyelitis.

Microbiology	Hematology & Oncology	Sickle cell
Subject	System	Topic

Copyright © UWorld. All rights reserved.

Settings

1 2 3 4 5 6 7 8 9 10 11 12 13 14 15 16 17 18 19 20 21 22 23 24 25 26 27 28 29 30

Item 24 of 38
Question Id: 896

Mark | Previous | Next | Full Screen | Tutorial | Lab Values | Notes | Calculator | Reverse Color | Text Zoom | Settings

Explanation

Patients with **sickle**
which leads to the f
vulnerable; repeated

Because the spleen
with significant risk
Haemophilus influen
fever, chills, leukocy
influenzae type b) is

(Choices A, B, C, E
pathogens. Howeve
Although *Pseudomo*
with cystic fibrosis,
prone to salmonella

Educational object
Patients with sickle
beds. This dramatic
Patients with sickle

Microbiology
Subject

Exhibit Display

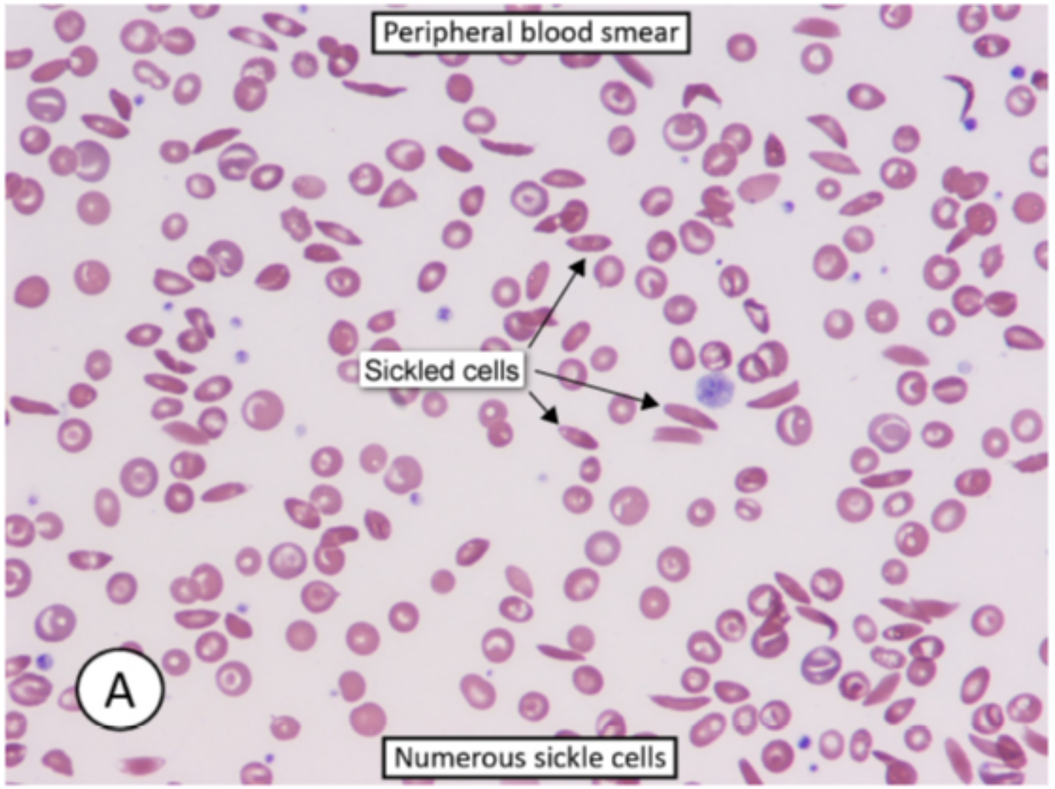

Zoom In | Zoom Out | Reset | Add To New Card | Existing Card

Block Time Remaining:
TUTOR

3 | Feedback | Suspend | End Block

1 2 3 4 5 6 7 8 9 10 11 12 13 14 15 16 17 18 19 20 21 22 23 24 25 26 27 28 29 30

A 32-year-old man comes to the emergency department due to a 2-day history of progressive difficulty walking and tingling in his feet. He says that his feet feel "like they've gone to sleep" and states that he tripped while walking this morning. Medical history is unremarkable except for an episode of acute diarrhea 2 weeks ago that resolved spontaneously. The patient takes no medications. He drinks 1-2 alcoholic beverages daily and does not use tobacco products or illicit drugs. Vital signs are within normal limits. Physical examination shows decreased muscular strength in the lower extremities bilaterally with absent deep tendon reflexes. Which of the following agents is most likely associated with this patient's condition?

A. *Campylobacter jejuni*

B. Rotavirus

C. *Salmonella*

D. Shiga toxin–producing *Escherichia coli*

E. *Shigella*

F. Zika virus

Submit

1 2 3 4 5 6 7 8 9 10 11 12 13 14 15 16 17 18 19 20 21 22 23 24 25 26 27 28 29 30

A 32-year-old man comes to the emergency department due to a 2-day history of progressive difficulty walking and tingling in his feet. He says that his feet feel "like they've gone to sleep" and states that he tripped while walking this morning. Medical history is unremarkable except for an episode of acute diarrhea 2 weeks ago that resolved spontaneously. The patient takes no medications. He drinks 1-2 alcoholic beverages daily and does not use tobacco products or illicit drugs. Vital signs are within normal limits. Physical examination shows decreased muscular strength in the lower extremities bilaterally with absent deep tendon reflexes. Which of the following agents is most likely associated with this patient's condition?

- ✓ A. *Campylobacter jejuni* (93%)
- B. Rotavirus (1%)
- C. *Salmonella* (0%)
- D. Shiga toxin–producing *Escherichia coli* (1%)
- E. *Shigella* (1%)
- F. Zika virus (1%)

Omitted
Correct answer
A

93%
Answered correctly

02 secs
Time Spent

03/15/2020
Last Updated

Explanation

Guillain-Barré syndrome

Guillain-Barré syndrome	
Mechanism	• Immune-mediated polyneuropathy due to cross-reacting antibodies (molecular mimicry)
Triggering events	• *Campylobacter jejuni* • Viral illness (eg, HIV, upper respiratory viral illness) • Trauma/surgery • Vaccinations
Pathology	• Endoneurial inflammation • Segmental demyelination & axon damage
Manifestations	• Symmetric, progressive muscle weakness • Depressed deep tendon reflexes • Paresthesias; back pain • Respiratory compromise

This patient with progressive lower extremity weakness, depressed deep tendon reflexes, and paresthesias has **Guillain-Barré syndrome** (GBS). GBS represents a group of immune-mediated demyelinating polyneuropathies that are thought to be caused by **molecular mimicry**. An antecedent event (typically an infection) provokes an immune response that cross-reacts with the Schwann cells and myelin sheath of the peripheral nerves. The myelin sheath is stripped from the axon, leading to loss of neuronal conductivity and axonal degeneration. Up to one-third of GBS cases are preceded by ***Campylobacter jejuni*** infection, a common cause of acute (sometimes bloody) **diarrhea**. Less common antecedent infections include upper respiratory viral illnesses, Epstein-Barr virus, cytomegalovirus, Zika virus, and HIV.

Patients with GBS experience **symmetric**, **ascending weakness** that typically begins in the legs and progresses to flaccid paralysis and respiratory failure. Decreased or absent deep tendon reflexes, paresthesias, pain (often of the back), and dysautonomia are common.

(Choices B, C, D, and E) Rotavirus, *Salmonella*, Shiga toxin–producing *Escherichia coli*, and *Shigella* are all important causes of diarrhea but are

1 2 3 4 5 6 7 8 9 10 11 12 13 14 15 16 17 18 19 20 21 22 23 24 25 26 27 28 29 30

	• Respiratory compromise

This patient with progressive lower extremity weakness, depressed deep tendon reflexes, and paresthesias has **Guillain-Barré syndrome** (GBS). GBS represents a group of immune-mediated demyelinating polyneuropathies that are thought to be caused by **molecular mimicry**. An antecedent event (typically an infection) provokes an immune response that cross-reacts with the Schwann cells and myelin sheath of the peripheral nerves. The myelin sheath is stripped from the axon, leading to loss of neuronal conductivity and axonal degeneration. Up to one-third of GBS cases are preceded by ***Campylobacter jejuni*** infection, a common cause of acute (sometimes bloody) **diarrhea**. Less common antecedent infections include upper respiratory viral illnesses, Epstein-Barr virus, cytomegalovirus, Zika virus, and HIV.

Patients with GBS experience **symmetric**, **ascending weakness** that typically begins in the legs and progresses to flaccid paralysis and respiratory failure. Decreased or absent deep tendon reflexes, paresthesias, pain (often of the back), and dysautonomia are common.

(Choices B, C, D, and E) Rotavirus, *Salmonella*, Shiga toxin–producing *Escherichia coli*, and *Shigella* are all important causes of diarrhea but are not associated with GBS. Both Shiga toxin–producing *E coli* and *Shigella* can cause bloody diarrhea and are associated with hemolytic uremic syndrome. Salmonella typically causes nonbloody diarrhea and may lead to bacteremia, particularly in an asplenic patient. Rotavirus, most commonly seen in children, causes nonbloody diarrhea and can lead to gastrointestinal obstruction due to small bowel intussusception.

(Choice F) Zika virus is associated with GBS; however, patients with Zika virus typically present with a pruritic maculopapular rash, low-grade fever, arthralgias, and conjunctivitis rather than diarrhea.

Educational objective:
Guillain-Barré syndrome represents a group of immune-mediated polyneuropathies that are thought to be caused by molecular mimicry, leading to demyelination of the peripheral nerves. Up to one-third of GBS cases are preceded by a *Campylobacter jejuni* infection, which is a common cause of acute diarrheal illness.

Microbiology	Nervous System	Guillain Barre syndrome
Subject	System	Topic

Copyright © UWorld. All rights reserved.

A 42-year-old woman is brought to the office in summer due to 2 weeks of personality changes. Her family reports that she has become withdrawn and does not talk as much as before. She has also had difficulty picking things up with her right hand. The patient has HIV infection and does not take her antiretroviral therapy consistently. She is a former smoker and used injection drugs in the past. The patient works in a food-processing facility and has not traveled recently. Temperature is 37 C (98.6 F), blood pressure is 126/78 mm Hg, pulse is 82/min, and respirations are 14/min. The patient is oriented to time, place, and person but is slow to respond to questions. Motor strength is decreased in her right upper extremity, with an exaggerated biceps reflex. CD4 count is 78 cells/mm^3, and plasma HIV RNA (viral load) is 400,000 copies/mL. CT scan of the head shows a small hypodense area in the left frontal lobe with ring enhancement after intravenous contrast administration. Two similar lesions are present in the basal ganglia and cerebellum. Which of the following is the most likely route of transmission of the infectious agent causing this patient's current condition?

A. Bite from an insect
B. Close contact with an infected person
C. Ingestion of contaminated particles
D. Inhalation of bird droppings
E. Scratch from an infected animal
F. Unprotected sexual intercourse

Submit

1 2 3 4 5 6 7 8 9 10 11 12 13 14 15 16 17 18 19 20 21 22 23 24 25 26 27 28 29 30

A 42-year-old woman is brought to the office in summer due to 2 weeks of personality changes. Her family reports that she has become withdrawn and does not talk as much as before. She has also had difficulty picking things up with her right hand. The patient has HIV infection and does not take her antiretroviral therapy consistently. She is a former smoker and used injection drugs in the past. The patient works in a food-processing facility and has not traveled recently. Temperature is 37 C (98.6 F), blood pressure is 126/78 mm Hg, pulse is 82/min, and respirations are 14/min. The patient is oriented to time, place, and person but is slow to respond to questions. Motor strength is decreased in her right upper extremity, with an exaggerated biceps reflex. CD4 count is 78 cells/mm^3, and plasma HIV RNA (viral load) is 400,000 copies/mL. CT scan of the head shows a small hypodense area in the left frontal lobe with ring enhancement after intravenous contrast administration. Two similar lesions are present in the basal ganglia and cerebellum. Which of the following is the most likely route of transmission of the infectious agent causing this patient's current condition?

- A. Bite from an insect (1%)
- B. Close contact with an infected person (5%)
- ✓ C. Ingestion of contaminated particles (67%)
- D. Inhalation of bird droppings (12%)
- E. Scratch from an infected animal (12%)
- F. Unprotected sexual intercourse (2%)

Omitted
Correct answer
C

67%
Answered correctly

02 secs
Time Spent

01/24/2020
Last Updated

Explanation

Toxoplasma encephalitis	
Setting	• Exposure to cat feces with subsequent ingestion of ***Toxoplasma gondii*** • Reactivation in setting of immunosuppression • Primarily **AIDS** with **CD4 count <100/mm^3**
Clinical	• Headache • Confusion • Fever • Focal neurologic deficits/seizures
Diagnostic	• Positive *Toxoplasma gondii* IgG • Multiple **ring-enhancing** brain lesions
Therapeutic	• Sulfadiazine & pyrimethamine (leucovorin) • Antiretroviral initiation • Prophylaxis: **TMP-SMX** (CD4 count <100/mm^3)

TMP-SMX = trimethoprim-sulfamethoxazole.

This patient with untreated AIDS has neurologic manifestations and multiple ring-enhancing brain lesions, raising strong suspicion for **toxoplasmic encephalitis**. The underlying pathogen is *Toxoplasma gondii*, an obligate intracellular parasite whose definitive host is **cats**. Transmission primarily occurs when individuals are exposed to contaminated **cat feces** (eg, litter box or cat handling) and subsequently **ingest oocytes**; it may also be transmitted by the consumption of undercooked meat from an intermediate host (eg, pig, sheep).

Healthy individuals rapidly contain the infection via a cell mediated immune response and rarely develop clinical symptoms. However, latent infection is established (tissue cysts), and reactivation can occur in the setting of immunocompromisation (eg, **advanced AIDS**). The most common manifestation of reactivation is toxoplasmic encephalitis, which is characterized by progressive headache, confusion, focal neurologic deficits, and/or seizure. Brain imaging classically shows multiple ring-enhancing lesions.

This patient with untreated AIDS has neurologic manifestations and multiple ring-enhancing brain lesions, raising strong suspicion for **toxoplasmic encephalitis**. The underlying pathogen is *Toxoplasma gondii*, an obligate intracellular parasite whose definitive host is **cats**. Transmission primarily occurs when individuals are exposed to contaminated **cat feces** (eg, litter box or cat handling) and subsequently **ingest oocytes**; it may also be transmitted by the consumption of undercooked meat from an intermediate host (eg, pig, sheep).

Healthy individuals rapidly contain the infection via a cell mediated immune response and rarely develop clinical symptoms. However, latent infection is established (tissue cysts), and reactivation can occur in the setting of immunocompromisation (eg, **advanced AIDS**). The most common manifestation of reactivation is toxoplasmic encephalitis, which is characterized by progressive headache, confusion, focal neurologic deficits, and/or seizure. Brain imaging classically shows multiple ring-enhancing lesions.

(Choice A) Mosquito bites can transmit viral pathogens (eg, West Nile, Zika) that can cause encephalitis. Patients may present with slowly worsening headache, confusion, seizure, or focal neurologic findings. However, viral pathogens do not typically cause ring-enhancing brain lesions.

(Choice B) Herpes virus type 1 is typically transmitted by close contact (eg, kissing) with an infected patient who has active lesions. Although this virus is the most common cause of sporadic encephalitis, imaging usually shows inflammation in the temporal lobe with edema and mass effect.

(Choice D) *Cryptococcus neoformans*, a fungus found in soil contaminated by bird (especially pigeon) droppings, is a common cause of meningoencephalitis in patients with untreated AIDS and usually presents with slowly worsening fever, malaise, and headache. Brain imaging rarely shows lesions, but signs of elevated intracranial pressure (eg, hydrocephalus) may be present.

(Choice E) *Bartonella henselae* is a gram-negative bacterium transmitted to humans during a cat scratch. Healthy individuals can subsequently develop cat-scratch disease (regional lymphadenopathy), but patients with advanced AIDS are at risk for the more serious clinical syndrome of bacillary angiomatosis (violaceous, highly vascular skin lesions with constitutional symptoms). However, central nervous system manifestations are uncommon.

(Choice F) Syphilis can be transmitted by unprotected sexual intercourse, and patients with HIV are at greater risk for developing neurosyphilis. This often presents with confusion, meningeal symptoms (eg, stiff neck), eye abnormalities, and cranial nerve palsies. However, MRI of the brain usually shows leptomeningeal enhancement, not ring-enhancing lesions.

Educational objective:

(Choice A) Mosquito bites can transmit viral pathogens (eg, West Nile, Zika) that can cause encephalitis. Patients may present with slowly worsening headache, confusion, seizure, or focal neurologic findings. However, viral pathogens do not typically cause ring-enhancing brain lesions.

(Choice B) Herpes virus type 1 is typically transmitted by close contact (eg, kissing) with an infected patient who has active lesions. Although this virus is the most common cause of sporadic encephalitis, imaging usually shows inflammation in the temporal lobe with edema and mass effect.

(Choice D) *Cryptococcus neoformans*, a fungus found in soil contaminated by bird (especially pigeon) droppings, is a common cause of meningoencephalitis in patients with untreated AIDS and usually presents with slowly worsening fever, malaise, and headache. Brain imaging rarely shows lesions, but signs of elevated intracranial pressure (eg, hydrocephalus) may be present.

(Choice E) *Bartonella henselae* is a gram-negative bacterium transmitted to humans during a cat scratch. Healthy individuals can subsequently develop cat-scratch disease (regional lymphadenopathy), but patients with advanced AIDS are at risk for the more serious clinical syndrome of bacillary angiomatosis (violaceous, highly vascular skin lesions with constitutional symptoms). However, central nervous system manifestations are uncommon.

(Choice F) Syphilis can be transmitted by unprotected sexual intercourse, and patients with HIV are at greater risk for developing neurosyphilis. This often presents with confusion, meningeal symptoms (eg, stiff neck), eye abnormalities, and cranial nerve palsies. However, MRI of the brain usually shows leptomeningeal enhancement, not ring-enhancing lesions.

Educational objective:
Toxoplasma gondii is an intracellular parasite that is typically transmitted to humans after accidental ingestion of contaminated cat feces (eg, cat handling, litter box). Most initial cases are asymptomatic. However, the organism establishes a latent infection that can reactivate in the setting of severe immunocompromise, particularly advanced AIDS. Patients usually develop encephalitis with multiple ring-enhancing lesions.

Microbiology	Nervous System	Toxoplasmosis
Subject	System	Topic

Copyright © UWorld. All rights reserved.

1
2
3
4
5
6
7
8
9
10
11
12
13
14
15
16
17
18
19
20
21
22
23
24
25
26
27
28
29
30

- Sulfadiazine & pyrimethamine (leucovorin)

Exhibit Display

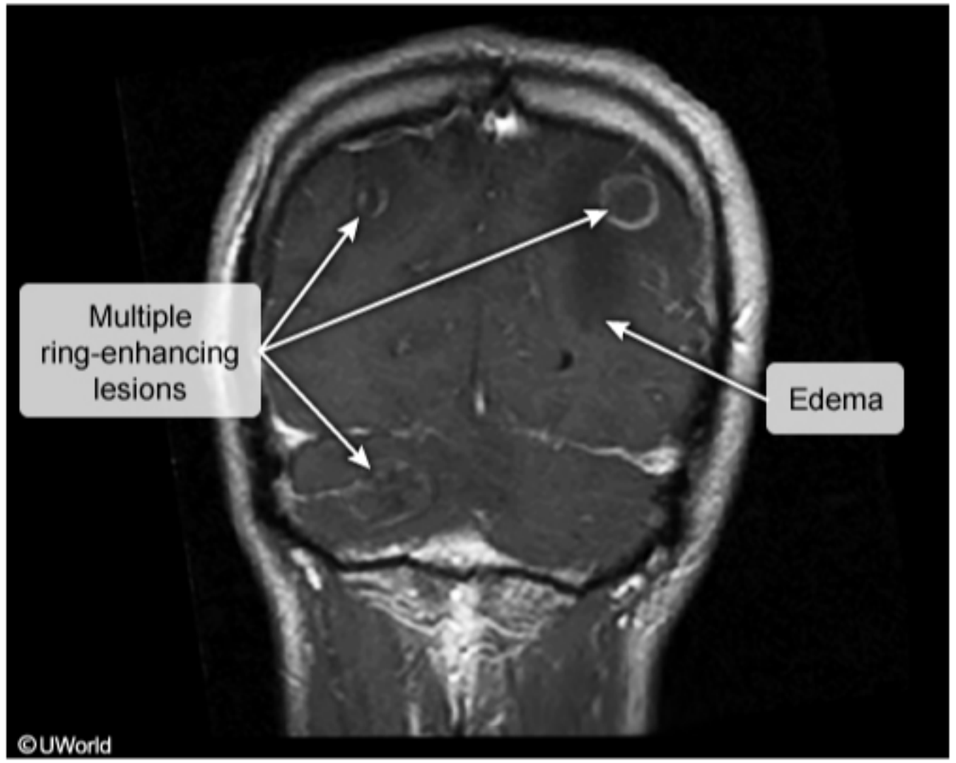

Zoom In | Zoom Out | Reset | Add To New Card | Existing Card

Settings

1 2 3 4 5 6 7 8 9 10 11 12 13 14 15 16 17 18 19 20 21 22 23 24 25 26 27 28 29 30

Item 26 of 38
Question Id: 14905

Mark | Previous | Next | Full Screen | Tutorial | Lab Values | Notes | Calculator | Reverse Color | Text Zoom | Settings

- Sulfadiazine & pyrimethamine (leucovorin)

Exhibit Display

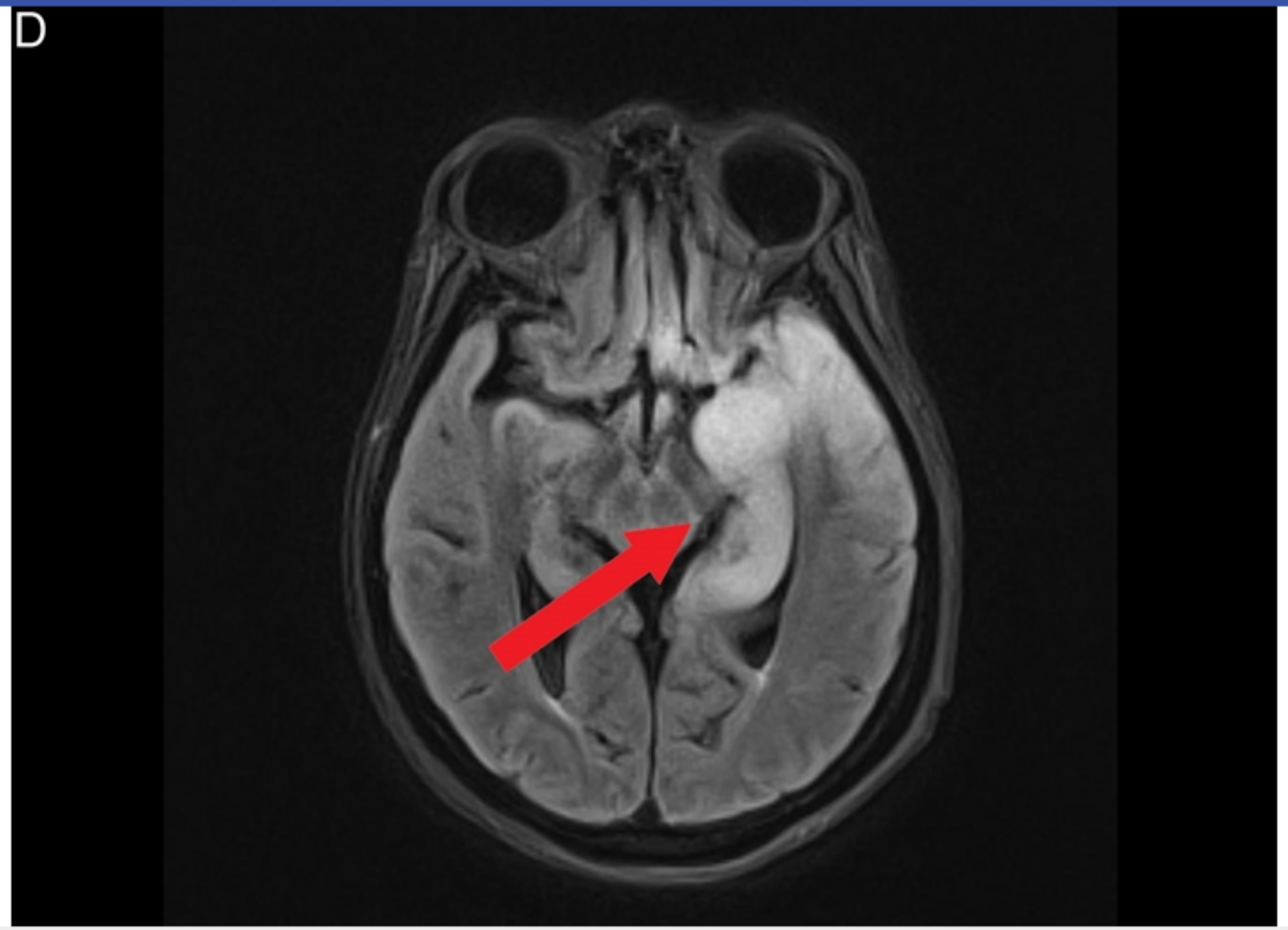

Zoom In | Zoom Out | Reset | Add To New Card | Existing Card

Block Time Remaining: 00:01:38
TUTOR

3 | Feedback | Suspend | End Block

A 3-week-old baby boy is brought to the emergency department with fever, irritability, and poor feeding. Examination of the cerebrospinal fluid shows a leukocyte count of 600 cells/μL (80% neutrophils), protein of 160 mg/dL, and glucose of 20 mg/dL. Blood cultures grow gram-negative rods that form pink colonies on MacConkey agar. Which of the following is the most important bacterial virulence factor for the development of this patient's condition?

- A. Capsule
- B. Fimbrial antigen
- C. Lipid A
- D. O antigen
- E. Verotoxin

Submit

A 3-week-old baby boy is brought to the emergency department with fever, irritability, and poor feeding. Examination of the cerebrospinal fluid shows a leukocyte count of 600 cells/μL (80% neutrophils), protein of 160 mg/dL, and glucose of 20 mg/dL. Blood cultures grow gram-negative rods that form pink colonies on MacConkey agar. Which of the following is the most important bacterial virulence factor for the development of this patient's condition?

- ✓ A. Capsule (56%)
- B. Fimbrial antigen (16%)
- C. Lipid A (17%)
- D. O antigen (7%)
- E. Verotoxin (2%)

Omitted
Correct answer
A

56%
Answered correctly

02 secs
Time Spent

07/05/2020
Last Updated

Explanation

Escherichia coli virulence factors		
Virulence factor	**Mechanism**	**Presentation**

***Escherichia coli* virulence factors**		
Virulence factor	**Mechanism**	**Presentation**
Lipopolysaccharide	Macrophage activation causes widespread release of IL-1, IL-6 & TNF-α	Bacteriemia & septic shock
K1 capsular polysaccharide	Prevents phagocytosis & complement-mediated lysis	Neonatal meningitis
Verotoxin (shiga-like toxin)	Inactivates the 60S ribosomal component, halting protein synthesis & causing cell death	Gastroenteritis (bloody)
Heat-stable/heat-labile enterotoxins	Promotes fluid & electrolyte secretion from intestinal epithelium	Gastroenteritis (watery)
P fimbriae	Allows adhesion to uroepithelium	Urinary tract infections

©UWorld

Group B *Streptococcus* is the most common cause of neonatal meningitis (0-3 months) in the United States, followed by *Escherichia coli* and *Listeria monocytogenes*. In older infants (>3 months) and adults, the most common pathogens are *Streptococcus pneumoniae* and *Neisseria meningitidis*.

Group B *Streptococcus* is the most common cause of neonatal meningitis (0-3 months) in the United States, followed by *Escherichia coli* and *Listeria monocytogenes*. In older infants (>3 months) and adults, the most common pathogens are *Streptococcus pneumoniae* and *Neisseria meningitidis*.

This patient has meningitis secondary to ***E coli*** infection. *E coli* is a motile, gram-negative, facultative anaerobic rod that is able to ferment both lactose and glucose. It grows well on blood, MacConkey, and eosin methylene blue agar plates. **MacConkey agar** is a selective and differential medium used to isolate gram-negative organisms from contaminants in clinical specimens. The bile salts and crystal violet present in MacConkey agar prevent the growth of gram-positive organisms. Organisms that **ferment lactose** (eg, *E coli*, *Klebsiella*, *Enterobacter*) cause a local drop in pH, resulting in **colonies with a pink-red appearance**. Non-lactose fermenting organisms remain colorless.

E coli can invade the blood stream of infants from the nasopharynx or gastrointestinal tract and can then travel hematogenously to the meninges. The **K1 capsular antigen** is present in 20%-40% of intestinal *E coli* isolates and is considered the major virulence factor among *E coli* strains that cause **neonatal meningitis**. Bacterial capsules are important for most meningeal pathogens. They help facilitate survival in the blood by preventing recognition of bacterial antigens, complement deposition, and subsequent phagocytosis. The K1 capsule is immunogenic and anti-capsular antibodies are protective against repeat infection.

(Choice B) Fimbriae (pili) are a virulence factor that allows bacteria to adhere to the target tissue, thereby establishing infection. Examples of organisms that use pili are *Neisseria gonorrhoeae*, uropathogenic *E coli*, and *Vibrio cholerae*.

(Choice C) The lipid A unit in lipopolysaccharides is similar for all enteric bacteria; it causes activation of macrophages, leading to widespread release of IL-1 and TNF-α, which in turn cause the signs and symptoms of septic shock.

(Choice D) The O antigen is the outermost component of the lipopolysaccharide molecule. It is a variable polysaccharide that can be used to classify gram-negative bacteria.

(Choice E) Verotoxin (shiga-like toxin) is synthesized by enterohemorrhagic *E coli*. Exotoxin expression is not present in any of the pathogens commonly associated with neonatal meningitis.

Educational objective:
Escherichia coli is a frequent cause of neonatal meningitis, second only to group B streptococci. *E coli* strains that cause neonatal meningitis possess the K1 capsular antigen. The K1 capsule is a virulence factor that allows the bacteria to survive in the bloodstream and establish

1 2 3 4 5 6 7 8 9 10 11 12 13 14 15 16 17 18 19 20 21 22 23 24 25 26 27 28 29 30

agar prevent the growth of gram-positive organisms. Organisms that **ferment lactose** (eg, *E coli*, *Klebsiella*, *Enterobacter*) cause a local drop in pH, resulting in **colonies with a pink-red appearance**. Non-lactose fermenting organisms remain colorless.

E coli can invade the blood stream of infants from the nasopharynx or gastrointestinal tract and can then travel hematogenously to the meninges. The **K1 capsular antigen** is present in 20%-40% of intestinal *E coli* isolates and is considered the major virulence factor among *E coli* strains that cause **neonatal meningitis**. Bacterial capsules are important for most meningeal pathogens. They help facilitate survival in the blood by preventing recognition of bacterial antigens, complement deposition, and subsequent phagocytosis. The K1 capsule is immunogenic and anti-capsular antibodies are protective against repeat infection.

(Choice B) Fimbriae (pili) are a virulence factor that allows bacteria to adhere to the target tissue, thereby establishing infection. Examples of organisms that use pili are *Neisseria gonorrhoeae*, uropathogenic *E coli*, and *Vibrio cholerae*.

(Choice C) The lipid A unit in lipopolysaccharides is similar for all enteric bacteria; it causes activation of macrophages, leading to widespread release of IL-1 and TNF-α, which in turn cause the signs and symptoms of septic shock.

(Choice D) The O antigen is the outermost component of the lipopolysaccharide molecule. It is a variable polysaccharide that can be used to classify gram-negative bacteria.

(Choice E) Verotoxin (shiga-like toxin) is synthesized by enterohemorrhagic *E coli*. Exotoxin expression is not present in any of the pathogens commonly associated with neonatal meningitis.

Educational objective:
Escherichia coli is a frequent cause of neonatal meningitis, second only to group B streptococci. *E coli* strains that cause neonatal meningitis possess the K1 capsular antigen. The K1 capsule is a virulence factor that allows the bacteria to survive in the bloodstream and establish meningeal infection.

Microbiology	Nervous System	Neonatal sepsis
Subject	System	Topic

Copyright © UWorld. All rights reserved.

A 14-year-old girl comes to the emergency department due to rapidly progressive exertional dyspnea and generalized weakness, which were preceded by a mild febrile illness several days ago. She has a history of sickle cell disease and takes a daily folic acid supplement. Her temperature is 37.2 C (99.1 F), blood pressure is 115/70 mm Hg, and pulse is 112/min and regular. On examination, the patient has conjunctival pallor but no icterus. A cardiac flow murmur is present. The abdomen is soft and nontender with no organomegaly. Laboratory studies show a hematocrit of 16% with reticulocyte count of 0.1% (normal range, 0.5%-1.5%). Leukocyte and platelet counts are normal. Which of the following best describes the virus most likely responsible for this patient's current condition?

- A. Enveloped double-stranded DNA virus
- B. Enveloped negative-sense RNA virus
- C. Enveloped positive-sense RNA virus
- D. Nonenveloped double-stranded DNA virus
- E. Nonenveloped positive-sense RNA virus
- F. Nonenveloped single-stranded DNA virus

Submit

A 14-year-old girl comes to the emergency department due to rapidly progressive exertional dyspnea and generalized weakness, which were preceded by a mild febrile illness several days ago. She has a history of sickle cell disease and takes a daily folic acid supplement. Her temperature is 37.2 C (99.1 F), blood pressure is 115/70 mm Hg, and pulse is 112/min and regular. On examination, the patient has conjunctival pallor but no icterus. A cardiac flow murmur is present. The abdomen is soft and nontender with no organomegaly. Laboratory studies show a hematocrit of 16% with reticulocyte count of 0.1% (normal range, 0.5%-1.5%). Leukocyte and platelet counts are normal. Which of the following best describes the virus most likely responsible for this patient's current condition?

- A. Enveloped double-stranded DNA virus (11%)
- B. Enveloped negative-sense RNA virus (5%)
- C. Enveloped positive-sense RNA virus (9%)
- D. Nonenveloped double-stranded DNA virus (11%)
- E. Nonenveloped positive-sense RNA virus (7%)
- ✓ F. Nonenveloped single-stranded DNA virus (53%)

Omitted
Correct answer
F

53%
Answered correctly

02 secs
Time Spent

06/22/2020
Last Updated

Explanation

This patient has developed severe anemia following a minor febrile illness. If her bone marrow were able to respond appropriately to the degree of anemia, the reticulocyte count would be elevated (normal reticulocyte count is 0.5%-1.5% of red cells). Instead, the patient's reticulocyte count

This patient has developed severe anemia following a minor febrile illness. If her bone marrow were able to respond appropriately to the degree of anemia, the reticulocyte count would be elevated (normal reticulocyte count is 0.5%-1.5% of red cells). Instead, the patient's reticulocyte count is markedly reduced.

This scenario describes an **aplastic crisis**, which in sickle cell patients is usually due to **parvovirus B19** infection of erythroid precursor cells in the **bone marrow**. Parvovirus is a nonenveloped single-stranded DNA virus. Destruction of the erythroid precursor cells by this virus diminishes the number of reticulocytes available to replace the deformed and/or removed erythrocytes. Aplastic crisis, which is limited to affecting erythrocytes, should not be confused with aplastic anemia, which, despite its name, represents bone marrow failure manifesting as pancytopenia (not just anemia).

(Choices A, C, and E) Epstein-Barr virus (enveloped double-stranded DNA virus), hepatitis C virus (enveloped single-stranded positive-sense RNA virus), and hepatitis E virus (nonenveloped single-stranded positive-sense RNA virus) can cause hematopoietic depression and some measure of aplastic anemia. HIV is another enveloped single-stranded positive-sense RNA virus that can cause aplastic anemia. However, these viruses are not the most common cause of hematopoietic depression and aplastic anemia, especially in a patient with sickle cell anemia.

(Choice B) Important enveloped negative-sense RNA viruses include orthomyxoviruses (eg, influenza), paramyxoviruses (eg, measles and mumps), and rhabdoviruses (eg, rabies). However, these viruses are not known to infect erythroid progenitor cells in sufficient numbers to significantly impact erythropoiesis.

(Choice D) Nonenveloped double-stranded DNA viruses include adenoviruses, papillomaviruses, and polyomaviruses, which are not commonly known to cause hematopoietic depression or aplastic anemia.

Educational objective:
In patients with sickle cell anemia and other chronic hemolytic disorders, the most common viral cause of an aplastic crisis is infection of erythroid progenitor cells with parvovirus B19, a nonenveloped single-stranded DNA virus.

Microbiology	Hematology & Oncology	Sickle cell
Subject	System	Topic

Copyright © UWorld. All rights reserved.

A 3-month-old infant is irritable, feeds poorly, and frequently vomits. His current weight is at the 45th percentile and his head circumference is at the 96th percentile. Funduscopy reveals white-yellow chorioretinal lesions in both eyes. Head CT shows enlarged ventricles and scattered intracranial calcifications. Which of the following is the most likely cause of this patient's condition?

A. Chromosomal abnormality

B. Single gene disease

C. In-utero infection

D. Intrapartum infection

E. Postpartum infection

Submit

A 3-month-old infant is irritable, feeds poorly, and frequently vomits. His current weight is at the 45th percentile and his head circumference is at the 96th percentile. Funduscopy reveals white-yellow chorioretinal lesions in both eyes. Head CT shows enlarged ventricles and scattered intracranial calcifications. Which of the following is the most likely cause of this patient's condition?

- A. Chromosomal abnormality (5%)
- B. Single gene disease (6%)
- ✓ C. In-utero infection (64%)
- D. Intrapartum infection (18%)
- E. Postpartum infection (5%)

Omitted
Correct answer
C

64%
Answered correctly

02 secs
Time Spent

02/03/2020
Last Updated

Explanation

Hydrocephalus, intracranial calcifications and chorioretinitis form the classic triad of congenital toxoplasmosis. Hydrocephalus occurs due to CNS inflammation and is evidenced by macrocephaly and enlargement of the ventricles. Chorioretinitis refers to inflammation of the choroids and the retina that can leave cotton-like white/yellow scars on the retina visible on funduscopy. Affected neonates also have hepatosplenomegaly, rash and multiple neurological abnormalities such as seizures, altered muscle tone and ocular movement defects. Occasionally microcephaly occurs when hydrocephalus is not severe.

Congenital toxoplasmosis is transmitted transplacentally. The fetus is affected only if the mother is infected with toxoplasmosis during the first six

Explanation

Hydrocephalus, intracranial calcifications and chorioretinitis form the classic triad of congenital toxoplasmosis. Hydrocephalus occurs due to CNS inflammation and is evidenced by macrocephaly and enlargement of the ventricles. Chorioretinitis refers to inflammation of the choroids and the retina that can leave cotton-like white/yellow scars on the retina visible on funduscopy. Affected neonates also have hepatosplenomegaly, rash and multiple neurological abnormalities such as seizures, altered muscle tone and ocular movement defects. Occasionally microcephaly occurs when hydrocephalus is not severe.

Congenital toxoplasmosis is transmitted transplacentally. The fetus is affected only if the mother is infected with toxoplasmosis during the first six months of pregnancy. As the majority of healthy individuals are exposed to *Toxoplasma* early in childhood, most adults are immune and primary infection in pregnancy is rare. Pregnant women, however, should be warned not to handle cat litter in order to prevent contact with *Toxoplasma*, which is often found in cat feces.

(Choice D) Infection with herpes simplex is acquired by a neonate during delivery (intrapartum). Ophthalmia neonatorum refers to neonatal conjunctivitis caused by a number of agents such as *Chlamydia*, *Neisseria* (which can cause blindness), and viruses; these infections are acquired during birth. Group B streptococcal sepsis is also acquired during birth.

(Choice E) Postpartum infections include any infections acquired after birth and are numerous.

Educational Objective:
Congenital toxoplasmosis is a transplacental infection (acquired in utero). Its classic triad includes hydrocephalus, intracranial calcifications and chorioretinitis. Expecting mothers should avoid cat feces to help prevent exposure to *Toxoplasma*.

Microbiology	Nervous System	Toxoplasmosis
Subject	System	Topic

Copyright © UWorld. All rights reserved.

Settings

1 2 3 4 5 6 7 8 9 10 11 12 13 14 15 16 17 18 19 20 21 22 23 24 25 26 27 28 29 30

Item 30 of 38
Question Id: 907

Mark | Previous | Next | Full Screen | Tutorial | Lab Values | Notes | Calculator | Reverse Color | Text Zoom | Settings

A 9-year-old girl is brought to the emergency department following a 3-minute generalized seizure. She has had a fever with a worsening headache for 3 days. The girl has no medical problems and is not taking any medications. She lives with her parents and pet cat and has traveled to Canada and England. On physical examination, she is disoriented and has difficulty staying awake. Her speech is difficult to understand due to inappropriate word choice. She is admitted to the intensive care unit for further workup. The patient becomes unresponsive the following day and dies overnight. Autopsy reveals bilateral, hemorrhagic necrosis of the inferior and medial temporal lobes. This patient's condition was most likely caused by infection with which of the following?

A. Enterovirus

B. Herpes simplex virus

C. *Naegleria fowleri*

D. *Neisseria meningitidis*

E. *Streptococcus pneumoniae*

F. *Toxoplasma gondii*

Submit

Block Time Remaining: 00:01:44
TUTOR

5 | Feedback | Suspend | End Block

A 9-year-old girl is brought to the emergency department following a 3-minute generalized seizure. She has had a fever with a worsening headache for 3 days. The girl has no medical problems and is not taking any medications. She lives with her parents and pet cat and has traveled to Canada and England. On physical examination, she is disoriented and has difficulty staying awake. Her speech is difficult to understand due to inappropriate word choice. She is admitted to the intensive care unit for further workup. The patient becomes unresponsive the following day and dies overnight. Autopsy reveals bilateral, hemorrhagic necrosis of the inferior and medial temporal lobes. This patient's condition was most likely caused by infection with which of the following?

- A. Enterovirus (1%)
- ✓ B. Herpes simplex virus (52%)
- C. *Naegleria fowleri* (13%)
- D. *Neisseria meningitidis* (4%)
- E. *Streptococcus pneumoniae* (2%)
- F. *Toxoplasma gondii* (24%)

Omitted
Correct answer
B

52%
Answered correctly

03 secs
Time Spent

01/09/2020
Last Updated

Explanation

HSV encephalitis

HSV encephalitis	
Pathogenesis	HSV-1 → olfactory tract → olfactory cortex (temporal lobe)
Presentation	Fever, headache, seizures, aphasia, mental status/behavior changes
Diagnosis	Temporal lobe hemorrhage/edema on brain imaging Cerebrospinal fluid PCR for HSV
Treatment	Intravenous acyclovir

HSV-1 = herpes simplex virus type 1.

Herpes simplex virus type 1 (HSV-1) encephalitis is the most common cause of fatal sporadic encephalitis, or inflammation of the brain parenchyma. HSV-1 encephalitis results from **primary oropharyngeal infection** that travels via the olfactory tract or from the **reactivation of latent virus** in the trigeminal ganglion with subsequent spread into the cerebral vault. CT, MRI (red arrow), and post-mortem macroscopic brain examination reveal **edema and hemorrhagic necrosis of the temporal lobe**. Unilateral involvement is most common, but bilateral necrosis can also occur. Definitive diagnosis is made by polymerase chain reaction testing of cerebrospinal fluid.

Symptoms of acute encephalitis include acute onset of **headache, fever, mental status changes** (eg, lethargy, disorientation), cranial nerve deficits (eg, Bell's palsy), and **seizures**. Temporal lobe damage can result in receptive **aphasia** and **personality changes** (eg, hypersexuality, aggression).

(Choice A) Enterovirus, particularly group B coxsackievirus, is the most common cause of viral meningitis in children. Less commonly, enterovirus causes encephalitis and acute flaccid paralysis, but temporal lobe involvement is not typical.

(Choice C) *Naegleria fowleri* is a free-living, protozoan parasite that causes rapid meningoencephalitis with a high mortality rate. *N fowleri* is found in fresh water, and transmission occurs through nasal inhalation during recreational activities (eg, swimming, diving). After spread through the cribriform plate to the olfactory cortex, infection leads to symptoms of encephalitis, as described above, in addition to smell and taste abnormalities. Inflammation can be seen in the frontal and temporal lobes, brainstem, and meninges.

enterovirus causes encephalitis and acute flaccid paralysis, but temporal lobe involvement is not typical.

(Choice C) *Naegleria fowleri* is a free-living, protozoan parasite that causes rapid meningoencephalitis with a high mortality rate. *N fowleri* is found in fresh water, and transmission occurs through nasal inhalation during recreational activities (eg, swimming, diving). After spread through the cribriform plate to the olfactory cortex, infection leads to symptoms of encephalitis, as described above, in addition to smell and taste abnormalities. Inflammation can be seen in the frontal and temporal lobes, brainstem, and meninges.

(Choices D and E) *Neisseria meningitidis* and *Streptococcus pneumoniae* are the 2 most common causes of bacterial meningitis. Unlike encephalitis, meningitis does not affect the brain parenchyma; rather, infection of the connective tissue layers of the brain leads to classic symptoms of fever, nuchal rigidity, and altered mental status.

(Choice F) Immunocompromised hosts (eg, patients with HIV) are predisposed to opportunistic pathogens (eg, *Toxoplasma gondii*, cytomegalovirus [CMV]) that can cause encephalitis. Toxoplasma encephalitis is classically associated with ring-enhancing lesions (white arrows) in the parietal or frontal lobes after ingestion of oocysts from soil or cat litter. CMV encephalitis can lead to parenchymal micro-nodules and ventricular enlargement.

Educational objective:
Herpes simplex virus type 1 encephalitis is a potentially fatal complication from primary infection or reactivation of latent disease. Nervous system invasion leads to necrosis of the temporal lobe, which can result in aphasia and personality changes in addition to classic features of encephalitis (eg, headache, fever, altered mental status, seizure).

References

- Herpes simplex encephalitis: adolescents and adults.
- Herpes simplex encephalitis: from virus to therapy.

Microbiology	Nervous System	HSV infection
Subject	System	Topic

Copyright © UWorld. All rights reserved.

Settings

1
2
3
4
5
6
7
8
9
10
11
12
13
14
15
16
17
18
19
20
21
22
23
24
25
26
27
28
29
30

Item 30 of 38
Question Id: 907

Mark | Previous | Next | Full Screen | Tutorial | Lab Values | Notes | Calculator | Reverse Color | Text Zoom | Settings

Exhibit Display

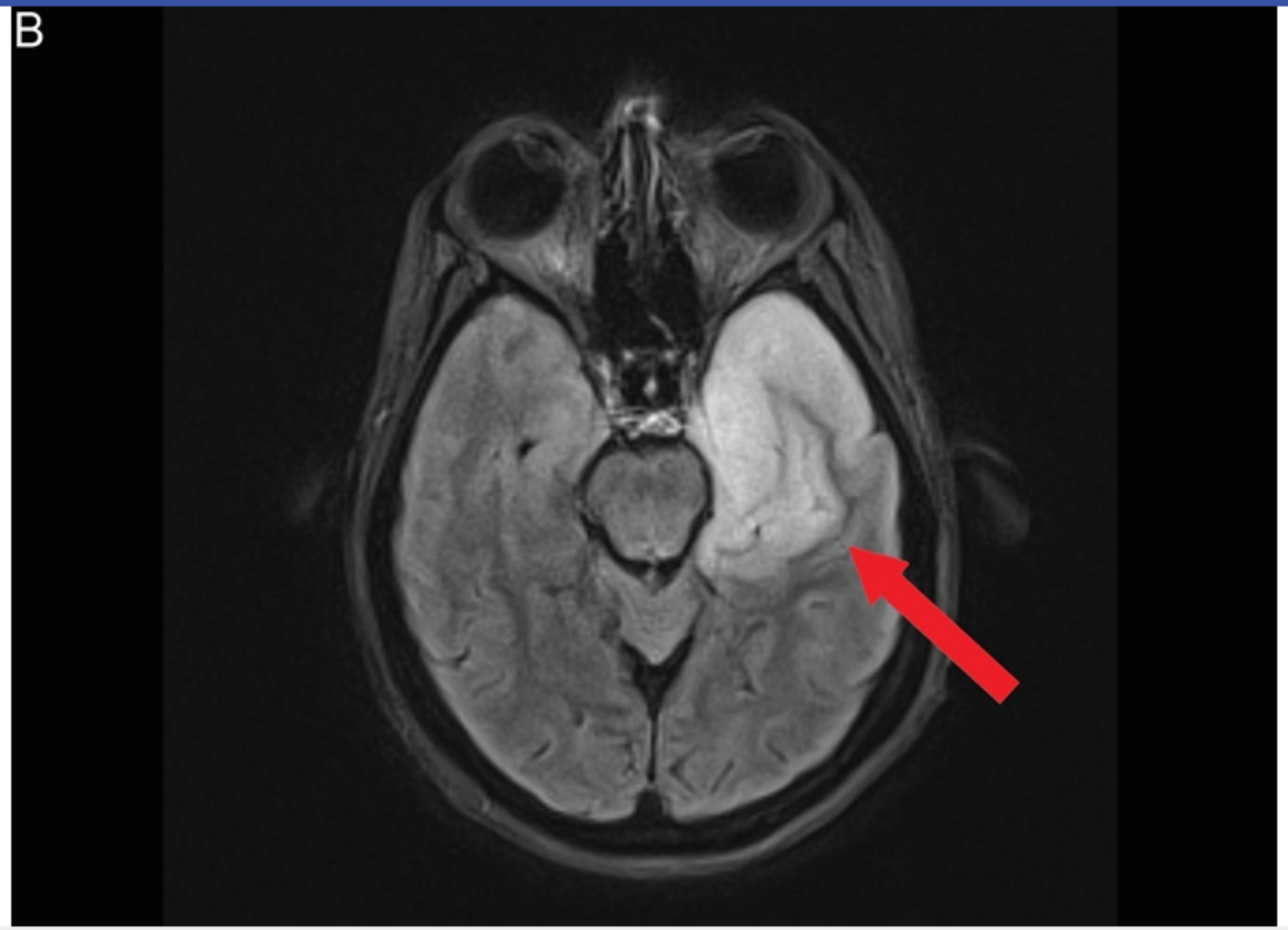

Zoom In | Zoom Out | Reset | Add To New Card | Existing Card

ventricular enlargement.

Block Time Remaining: 00:01:47
TUTOR

5 | Feedback | Suspend | End Block

Exhibit Display

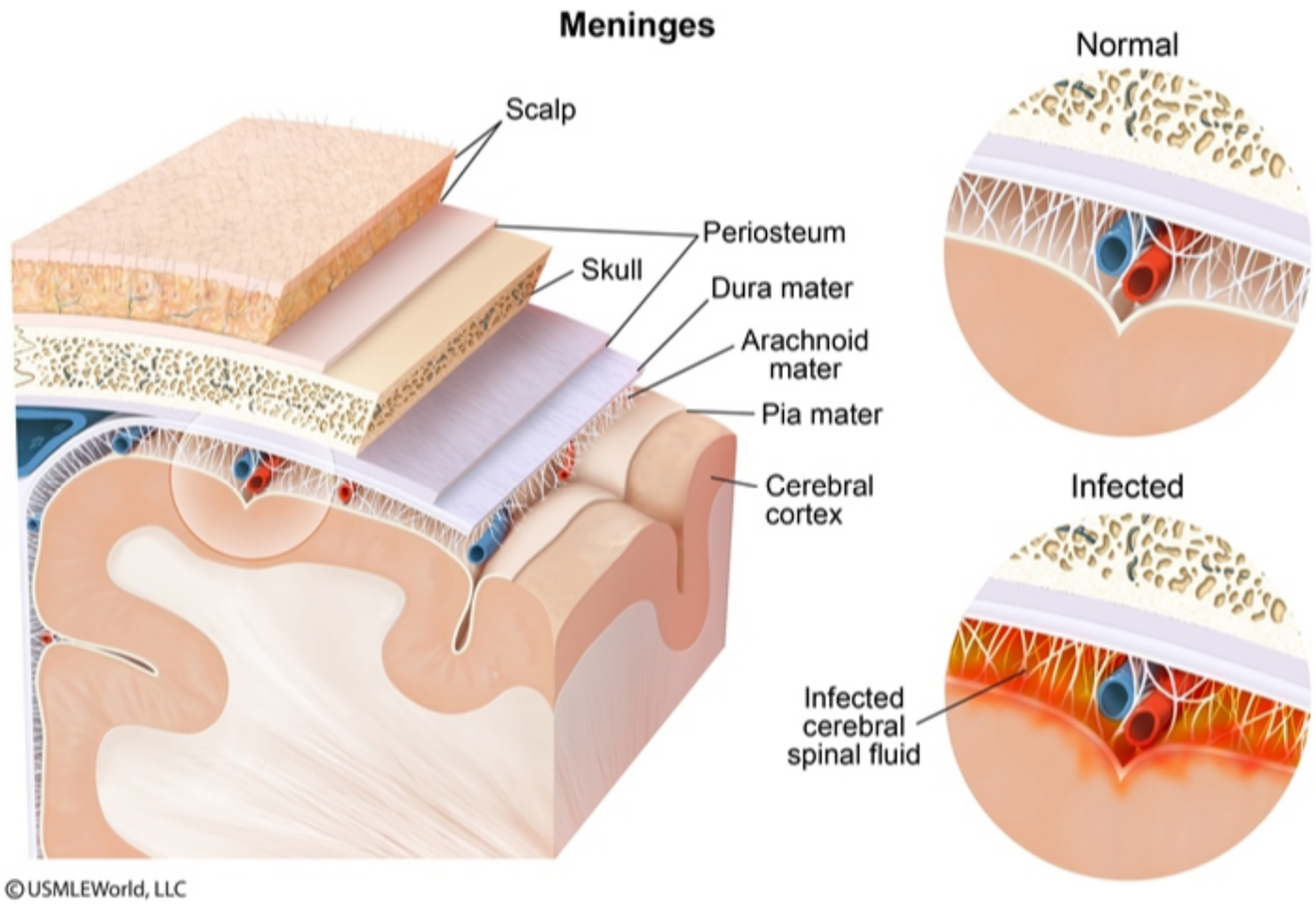

Zoom In | Zoom Out | Reset | Add To New Card | Existing Card

ventricular enlargement.

deficits (eg, Bell's palsy), and **seizures**. Temporal lobe damage can result in receptive **aphasia** and **personality changes** (eg, hypersexuality,

Exhibit Display

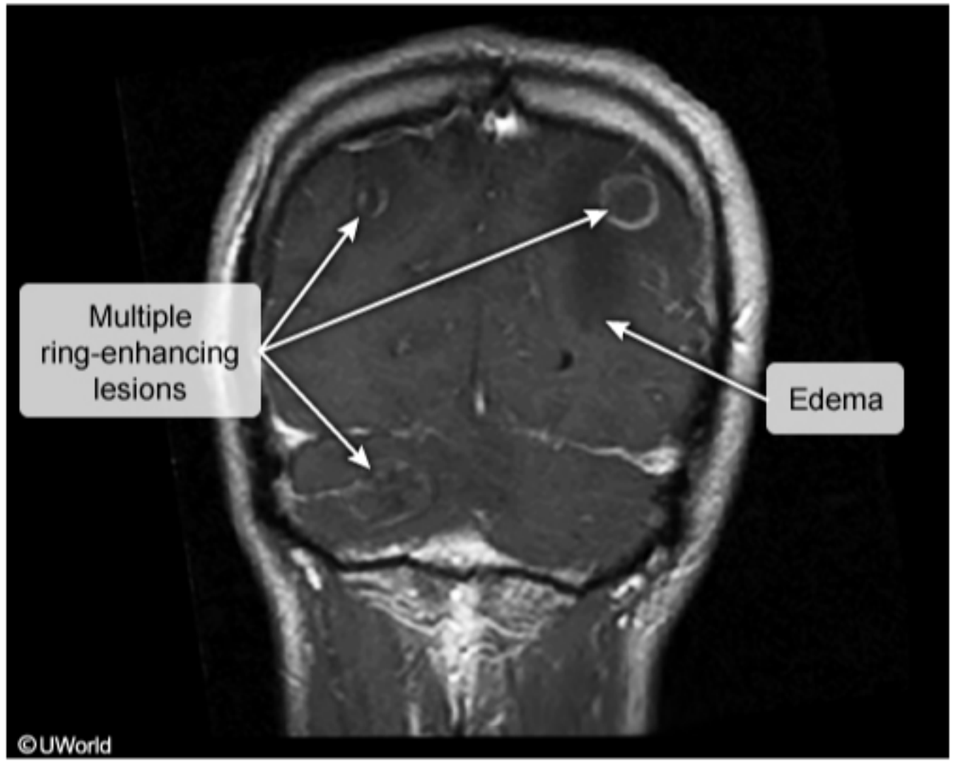

Zoom In | Zoom Out | Reset | Add To New Card | Existing Card

Microbiology Nervous System HSV infection

A 42-year-old man is brought to the emergency department following an episode of generalized tonic-clonic seizure witnessed by his family. He has no prior history of seizure but has had headaches for the past several weeks. The patient works in construction. He has no history of travel outside the United States and has never had any pets. He smokes a pack of cigarettes daily and drinks 3-4 cans of beer every evening. Physical examination is notable for a postictal state, oral thrush, and several enlarged cervical and inguinal lymph nodes. An MRI of his brain with contrast is shown in the image below.

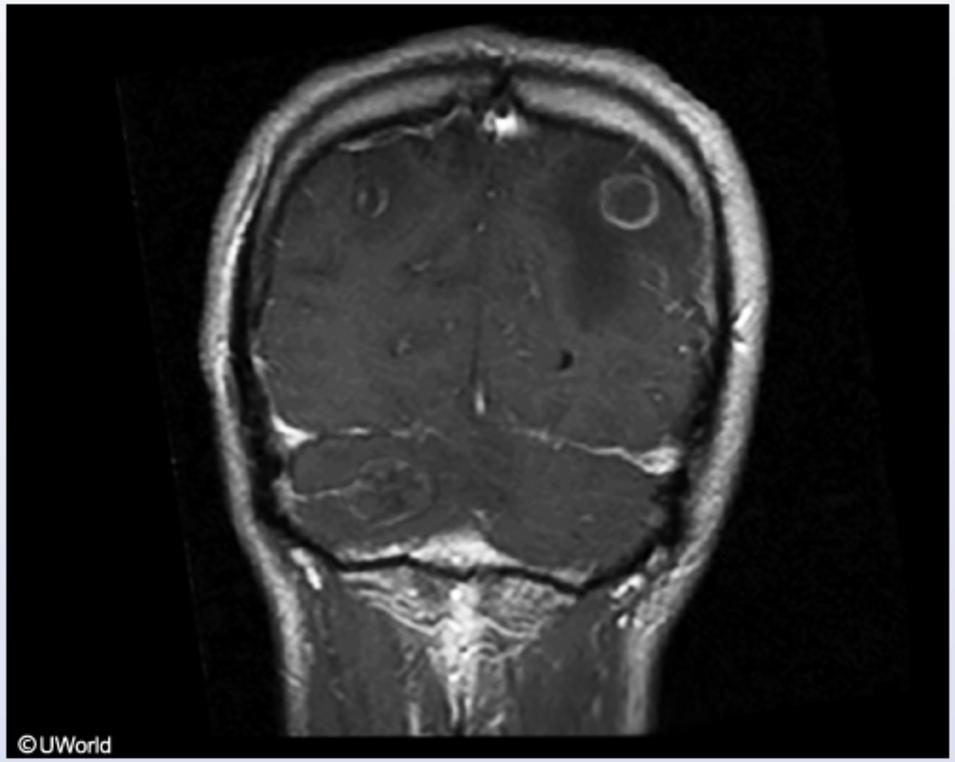

Which of the following is the most likely cause of this patient's symptoms?

A. *Aspergillus fumigatus*

1 2 3 4 5 6 7 8 9 10 11 12 13 14 15 16 17 18 19 20 21 22 23 24 25 26 27 28 29 30

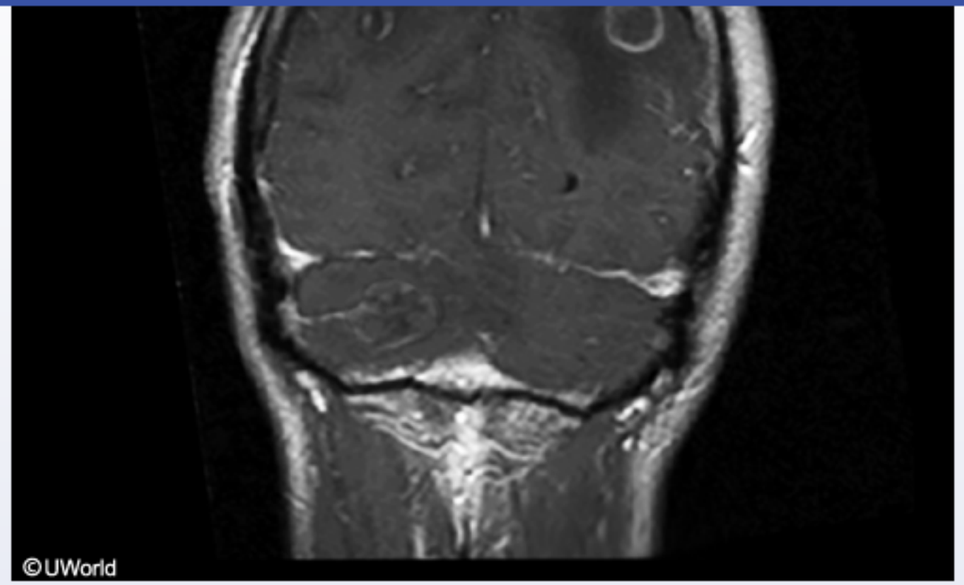

Which of the following is the most likely cause of this patient's symptoms?

A. *Aspergillus fumigatus*

B. Glioblastoma multiforme

C. *Mycobacterium tuberculosis*

D. Neurocysticercosis

E. Toxoplasmosis

Submit

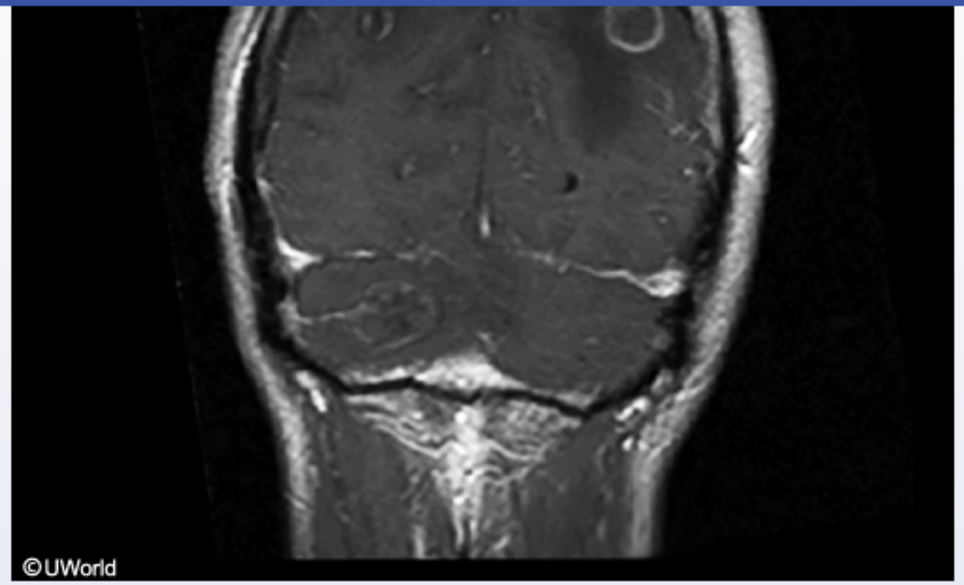

Which of the following is the most likely cause of this patient's symptoms?

A. *Aspergillus fumigatus* (13%)

B. Glioblastoma multiforme (4%)

C. *Mycobacterium tuberculosis* (2%)

D. Neurocysticercosis (14%)

✓ E. Toxoplasmosis (65%)

Omitted
Correct answer

65%
Answered correctly

04 secs
Time Spent

06/01/2020
Last Updated

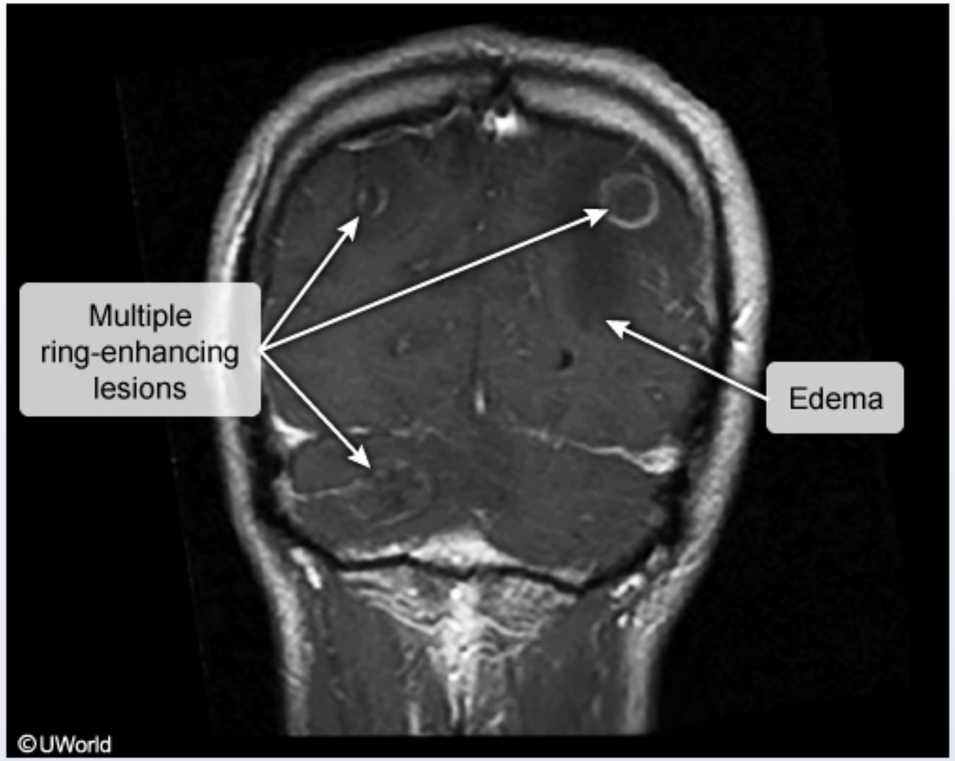

This patient likely has **HIV** given his oral thrush (usually seen with CD4 count <200/mm^3), cervical and inguinal lymphadenopathy, and brain lesions. In patients with HIV (particularly those with low CD4 counts), headaches, **seizures**, and **multiple ring-enhancing** central nervous system (CNS) lesions on MRI (white arrows) suggest **toxoplasmic encephalitis**. Seizures are a common complication of such brain lesions and their surrounding edema. Extensive pet (cat) exposure is not essential for the diagnosis, as toxoplasmosis can also be transmitted through contaminated foods.

(Choice A) *Aspergillus* is not a leading opportunistic pathogen in patients with HIV, possibly because they have relatively intact phagocytic function despite their T cell dysfunction. *Aspergillus* typically affects the lungs; however, it can cause brain abscesses in patients who are immunocompromised due to neutropenia or transplant.

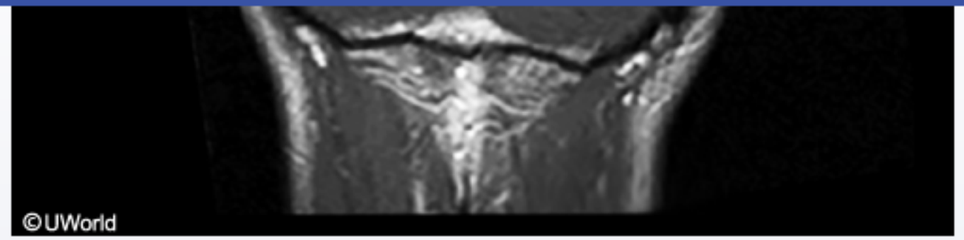

This patient likely has **HIV** given his oral thrush (usually seen with CD4 count <200/mm^3), cervical and inguinal lymphadenopathy, and brain lesions. In patients with HIV (particularly those with low CD4 counts), headaches, **seizures**, and **multiple ring-enhancing** central nervous system (CNS) lesions on MRI (white arrows) suggest **toxoplasmic encephalitis**. Seizures are a common complication of such brain lesions and their surrounding edema. Extensive pet (cat) exposure is not essential for the diagnosis, as toxoplasmosis can also be transmitted through contaminated foods.

(Choice A) *Aspergillus* is not a leading opportunistic pathogen in patients with HIV, possibly because they have relatively intact phagocytic function despite their T cell dysfunction. *Aspergillus* typically affects the lungs; however, it can cause brain abscesses in patients who are immunocompromised due to neutropenia or transplant.

(Choice B) Although CNS glioblastomas are ring-enhancing, they are typically solitary and often have a characteristic butterfly appearance.

(Choices C and D) Neurocysticercosis (due to *Taenia solium* [pork tapeworm] ingestion) can cause multiple brain lesions but would be unlikely in this patient with no travel history to South or Central America. Similarly, *Mycobacterium tuberculosis* CNS infection, which can cause similar lesions, is a consideration in developing countries but is a less likely diagnosis in the United States.

Educational objective:
The finding of multiple ring-enhancing lesions in an HIV patient is most likely due to toxoplasmosis.

Microbiology	Nervous System	Toxoplasmosis
Subject	System	Topic

Copyright © UWorld. All rights reserved.

Settings

1
2
3
4
5
6
7
8
9
10
11
12
13
14
15
16
17
18
19
20
21
22
23
24
25
26
27
28
29
30

Item 31 of 38
Question Id: 1573

Mark | Previous | Next | Full Screen | Tutorial | Lab Values | Notes | Calculator | Reverse Color | Text Zoom | Settings

Exhibit Display

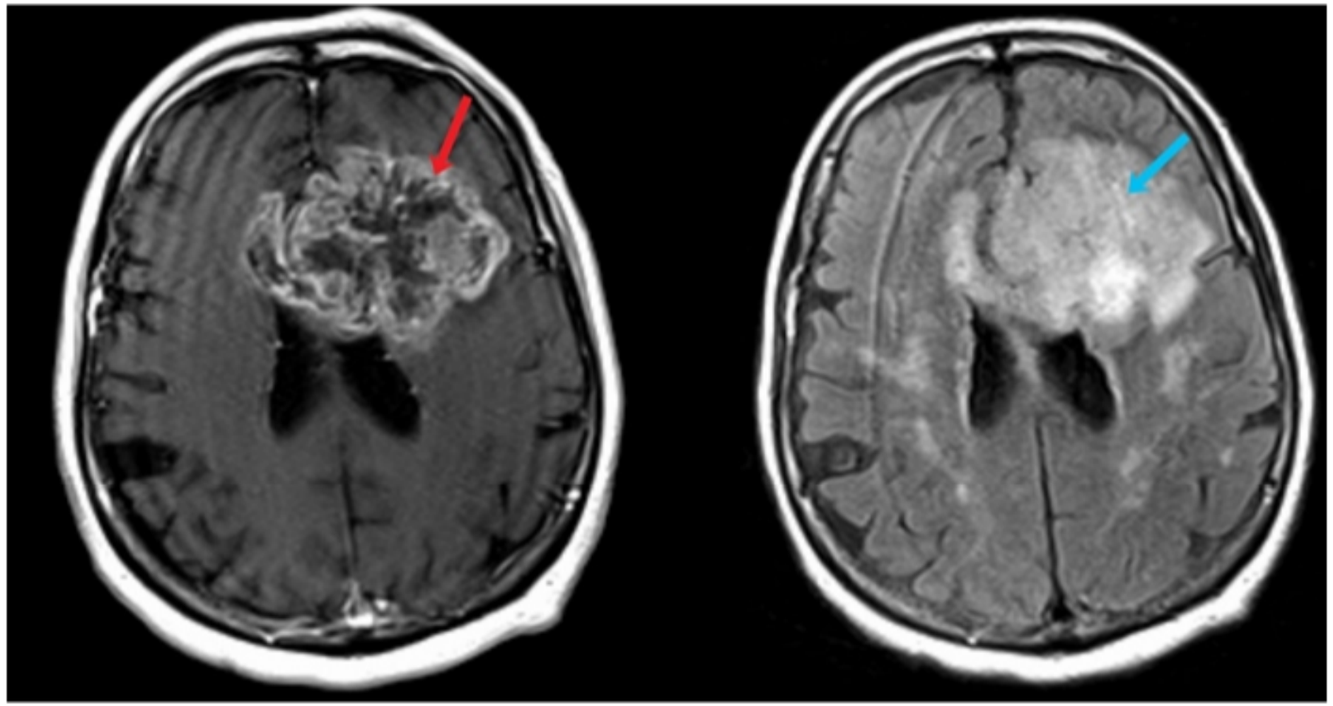

Zoom In | Zoom Out | Reset | Add To New Card | Existing Card

Block Time Remaining: 00:01:51
TUTOR

4 | Feedback | Suspend | End Block

A 22-year-old woman comes to the office for a routine prenatal visit. She is 16 weeks pregnant with her first child. Two months ago, she had a mononucleosis-like illness with fever, myalgia, and fatigue, and she was diagnosed with cytomegalovirus infection. The patient recovered with symptomatic treatment and is currently asymptomatic. Her other medical problems include episodic migraine headaches and benign choroidal nevus. She takes prenatal vitamins and does not use tobacco, alcohol, or illicit drugs. The patient has a family history of hypertension and glaucoma. Physical examination findings and prenatal ultrasound are unremarkable. This patient's unborn infant is at greatest risk for which of the following eye conditions?

- A. Chorioretinitis
- B. Choroidal nevus
- C. Congenital cataract
- D. Glaucoma
- E. Inclusion conjunctivitis
- F. Retinitis pigmentosa
- G. Retinoblastoma

Submit

A 22-year-old woman comes to the office for a routine prenatal visit. She is 16 weeks pregnant with her first child. Two months ago, she had a mononucleosis-like illness with fever, myalgia, and fatigue, and she was diagnosed with cytomegalovirus infection. The patient recovered with symptomatic treatment and is currently asymptomatic. Her other medical problems include episodic migraine headaches and benign choroidal nevus. She takes prenatal vitamins and does not use tobacco, alcohol, or illicit drugs. The patient has a family history of hypertension and glaucoma. Physical examination findings and prenatal ultrasound are unremarkable. This patient's unborn infant is at greatest risk for which of the following eye conditions?

- ✓ A. Chorioretinitis (60%)
- B. Choroidal nevus (2%)
- C. Congenital cataract (18%)
- D. Glaucoma (3%)
- E. Inclusion conjunctivitis (8%)
- F. Retinitis pigmentosa (5%)
- G. Retinoblastoma (1%)

Omitted
Correct answer
A

60%
Answered correctly

02 secs
Time Spent

01/18/2020
Last Updated

Explanation

Up to 5% of women develop a **primary cytomegalovirus (CMV) infection** (typically a mononucleosis-like illness with fever and mild hepatitis)

Explanation

Up to 5% of women develop a **primary cytomegalovirus (CMV) infection** (typically a mononucleosis-like illness with fever and mild hepatitis) during pregnancy. Vertical transmission to the fetus occurs in approximately one-third of cases, with the highest risk of transmission occurring in the first trimester. **CMV-related complications** observed in infants exposed to the virus **in utero** include **chorioretinitis** (most common eye-related problem), sensorineural deafness, seizures, jaundice, hepatomegaly, splenomegaly, and microcephaly.

(Choice B) Choroidal nevus (eye freckle) is a nonhereditary, usually benign pigmented area underneath the retina and is not associated with in-utero CMV infection.

(Choice C) Congenital cataract can be seen with in-utero rubella infection.

(Choice D) Glaucoma can be present at birth and may be primary or secondary (eg, tumor). However, it is not a known complication of CMV infection.

(Choice E) Inclusion conjunctivitis is seen with *Chlamydia trachomatis* infection of the newborn.

(Choice F) Retinitis pigmentosa is an inherited degenerative eye disease that leads to severe vision impairment and is not a complication of in-utero CMV infection.

(Choice G) Retinoblastoma is the most common malignant eye cancer in children and is caused by a chromosomal mutation that is hereditary or sporadic. CMV infection in utero is not associated with causing retinoblastoma.

Educational objective:
The most common eye-related complication of congenital cytomegalovirus infection is chorioretinitis.

References

- Ocular abnormalities in congenital cytomegalovirus infection.

Microbiology	Ophthalmology	Cytomegalovirus
Subject	System	Topic

Up to 5% of women develop a **primary cytomegalovirus (CMV) infection** (typically a mononucleosis-like illness with fever and mild hepatitis) during pregnancy. Vertical transmission to the fetus occurs in approximately one-third of cases, with the highest risk of transmission occurring in the first trimester. **CMV-related complications** observed in infants exposed to the virus **in utero** include **chorioretinitis** (most common eye-related problem), sensorineural deafness, seizures, jaundice, hepatomegaly, splenomegaly, and microcephaly.

(Choice B) Choroidal nevus (eye freckle) is a nonhereditary, usually benign pigmented area underneath the retina and is not associated with in-utero CMV infection.

(Choice C) Congenital cataract can be seen with in-utero rubella infection.

(Choice D) Glaucoma can be present at birth and may be primary or secondary (eg, tumor). However, it is not a known complication of CMV infection.

(Choice E) Inclusion conjunctivitis is seen with *Chlamydia trachomatis* infection of the newborn.

(Choice F) Retinitis pigmentosa is an inherited degenerative eye disease that leads to severe vision impairment and is not a complication of in-utero CMV infection.

(Choice G) Retinoblastoma is the most common malignant eye cancer in children and is caused by a chromosomal mutation that is hereditary or sporadic. CMV infection in utero is not associated with causing retinoblastoma.

Educational objective:
The most common eye-related complication of congenital cytomegalovirus infection is chorioretinitis.

References

- Ocular abnormalities in congenital cytomegalovirus infection.

Microbiology	Ophthalmology	Cytomegalovirus
Subject	System	Topic

Copyright © UWorld. All rights reserved.

A 68-year-old woman is brought to the emergency department due to confusion and lower extremity weakness. The symptoms began 2 days ago along with fever, headache, malaise, and myalgias. Today, the patient was noted to be confused and had difficulty ambulating due to left lower extremity weakness. The patient has a history of lymphoma in remission, hypertension, and type 2 diabetes mellitus. She drinks alcohol socially but does not use tobacco or illicit drugs. She is visiting her family in Texas for the summer and has never traveled outside the United States. Temperature is 38.3 C (101 F), blood pressure is 130/70 mm Hg, and pulse is 96/min. The patient is oriented to place and person only and has a coarse hand tremor. There is flaccid paralysis of the left lower extremity with preserved sensation. CT scan of the head shows no abnormalities. Lumbar puncture is performed, and cerebrospinal fluid analysis shows lymphocytic pleocytosis and elevated protein. Cerebrospinal fluid polymerase chain reaction testing yields viral RNA. The agent infecting this patient most likely uses which of the following modes of transmission?

- A. Blood transfusion
- B. Fecal-oral
- C. Insect bite
- D. Respiratory
- E. Sexual

Submit

A 68-year-old woman is brought to the emergency department due to confusion and lower extremity weakness. The symptoms began 2 days ago along with fever, headache, malaise, and myalgias. Today, the patient was noted to be confused and had difficulty ambulating due to left lower extremity weakness. The patient has a history of lymphoma in remission, hypertension, and type 2 diabetes mellitus. She drinks alcohol socially but does not use tobacco or illicit drugs. She is visiting her family in Texas for the summer and has never traveled outside the United States. Temperature is 38.3 C (101 F), blood pressure is 130/70 mm Hg, and pulse is 96/min. The patient is oriented to place and person only and has a coarse hand tremor. There is flaccid paralysis of the left lower extremity with preserved sensation. CT scan of the head shows no abnormalities. Lumbar puncture is performed, and cerebrospinal fluid analysis shows lymphocytic pleocytosis and elevated protein. Cerebrospinal fluid polymerase chain reaction testing yields viral RNA. The agent infecting this patient most likely uses which of the following modes of transmission?

- A. Blood transfusion (2%)
- B. Fecal-oral (34%)
- ✓ C. Insect bite (35%)
- D. Respiratory (21%)
- E. Sexual (5%)

Omitted
Correct answer
C

35%
Answered correctly

02 secs
Time Spent

04/25/2020
Last Updated

Explanation

West Nile virus

West Nile virus	
Clinical syndrome	• West Nile fever: fever, headache, rash (maculopapular/morbilliform) • Neuroinvasive: meningitis, encephalitis, acute asymmetric flaccid paralysis ◦ Parkinsonian symptoms (eg, rigidity, bradykinesia, tremor)
Transmission	• Mosquitoes (*Culex* spp.) • More common in summer/fall • Warm climate (southern United States, Latin America, Africa)
Risk factors	• Older age • Malignancy/organ transplant

This patient has acute confusion associated with fever and asymmetric lower extremity paralysis, consistent with neuroinvasive **West Nile virus** (WNV) infection. WNV is a positive-sense, single-strand RNA flavivirus transmitted by female **mosquitoes** (*Culex spp*), most commonly in the summer in warmer regions (eg, southern United States, Latin America, Africa). Most WNV infections are asymptomatic or present with a flu-like illness (ie, West Nile fever: fever, headache, myalgias), often with a maculopapular or morbilliform rash on the back and chest.

Neuroinvasive infection is an uncommon complication of WNV but has a 10% fatality rate. It occurs most commonly in older patients and those with a history of malignancy or organ transplant, and is characterized by meningitis (ie, headache, meningismus) and/or encephalitis (altered mental status). The presence of acute-onset **asymmetric flaccid paralysis** is highly suggestive of WNV, particularly if the patient demonstrates concurrent **parkinsonian features** (eg, rigidity, bradykinesia, tremor, postural instability). Diagnosis can be made when compatible clinical findings are associated with positive cerebrospinal fluid **anti-WNV antibodies** (polymerase chain reaction testing often not needed).

(Choices A and E) HIV, cytomegalovirus, and Epstein-Barr virus can be transmitted via blood transfusion or sexual contact, whereas herpes simplex virus 1 and 2 are transmitted through sexual or oral contact. Although these viruses can cause aseptic meningitis and encephalitis, asymmetric flaccid paralysis and concurrent tremor are more suggestive of WNV.

(Choice B) The enteroviruses, so named due to their fecal-oral transmission, account for most aseptic meningitis cases, but most are very rarely associated with flaccid paralysis. Of the enteroviruses, poliovirus can cause paralysis but would be extremely unlikely (eradicated in the United

with a history of malignancy or organ transplant, and is characterized by meningitis (ie, headache, meningismus) and/or encephalitis (altered mental status). The presence of acute-onset **asymmetric flaccid paralysis** is highly suggestive of WNV, particularly if the patient demonstrates concurrent **parkinsonian features** (eg, rigidity, bradykinesia, tremor, postural instability). Diagnosis can be made when compatible clinical findings are associated with positive cerebrospinal fluid **anti-WNV antibodies** (polymerase chain reaction testing often not needed).

(Choices A and E) HIV, cytomegalovirus, and Epstein-Barr virus can be transmitted via blood transfusion or sexual contact, whereas herpes simplex virus 1 and 2 are transmitted through sexual or oral contact. Although these viruses can cause aseptic meningitis and encephalitis, asymmetric flaccid paralysis and concurrent tremor are more suggestive of WNV.

(Choice B) The enteroviruses, so named due to their fecal-oral transmission, account for most aseptic meningitis cases, but most are very rarely associated with flaccid paralysis. Of the enteroviruses, poliovirus can cause paralysis but would be extremely unlikely (eradicated in the United States). Post-polio syndrome can occur in patients with prior infection, but it generally causes slowly progressive weakness without acute fever, confusion, or rash.

(Choice D) Varicella, mumps, and adenoviruses are spread via respiratory secretions and are capable of causing aseptic meningitis or encephalitis, but paralysis is rare.

Educational objective:
West Nile virus is a single-strand flavivirus transmitted by mosquitoes, most commonly in the summer. Most infections are asymptomatic or may present with a flu-like illness (West Nile fever), often with a maculopapular or morbilliform rash. Neuroinvasive disease manifests as meningitis, encephalitis, or asymmetric flaccid paralysis; patients may have parkinsonian features.

References

- West Nile virus: review of the literature.

Microbiology	Nervous System	West Nile virus infection
Subject	System	Topic

Copyright © UWorld. All rights reserved.

A 44-year-old man is brought to the emergency department by his wife because of confusion that began a few hours ago. Earlier in the day, he complained of a severe headache and nausea. On physical examination, his temperature is 38.3 C (101 F) and nuchal rigidity is present. Lumbar puncture and cerebrospinal fluid (CSF) examination show:

Opening pressure	300 mm H_2O
Glucose	20 mg/dL
Protein	200 mg/dL
RBCs	4 cells/μL
Leukocytes	760 cells/μL
Neutrophils	90%
Lymphocytes	10%

Gram stain of the CSF would most likely reveal which of the following?

A. Bean-shaped, Gram-negative cocci in pairs
B. Lancet-shaped, Gram-positive cocci in pairs
C. Gram-positive cocci in clusters
D. Non-motile Gram-negative coccobacilli
E. Motile Gram-positive rods

Submit

complained of a severe headache and nausea. On physical examination, his temperature is 38.3 C (101 F) and nuchal rigidity is present. Lumbar puncture and cerebrospinal fluid (CSF) examination show:

Opening pressure	300 mm H_2O
Glucose	20 mg/dL
Protein	200 mg/dL
RBCs	4 cells/μL
Leukocytes	760 cells/μL
Neutrophils	90%
Lymphocytes	10%

Gram stain of the CSF would most likely reveal which of the following?

A. Bean-shaped, Gram-negative cocci in pairs
B. Lancet-shaped, Gram-positive cocci in pairs
C. Gram-positive cocci in clusters
D. Non-motile Gram-negative coccobacilli
E. Motile Gram-positive rods

Submit

complained of a severe headache and nausea. On physical examination, his temperature is 38.3 C (101 F) and nuchal rigidity is present. Lumbar puncture and cerebrospinal fluid (CSF) examination show:

Opening pressure	300 mm H_2O
Glucose	20 mg/dL
Protein	200 mg/dL
RBCs	4 cells/μL
Leukocytes	760 cells/μL
Neutrophils	90%
Lymphocytes	10%

Gram stain of the CSF would most likely reveal which of the following?

A. Bean-shaped, Gram-negative cocci in pairs (29%)

✓ B. Lancet-shaped, Gram-positive cocci in pairs (57%)

C. Gram-positive cocci in clusters (5%)

D. Non-motile Gram-negative coccobacilli (5%)

E. Motile Gram-positive rods (1%)

Omitted
Correct answer

57%
Answered correctly

05 secs
Time Spent

02/16/2020
Last Updated

Explanation

A patient presenting with confusion, headache, fever, and nuchal rigidity should immediately raise suspicion for meningitis. In bacterial meningitis, cerebrospinal fluid (CSF) analysis typically shows elevated opening pressure, increased neutrophils, decreased glucose, and elevated protein. The morphology of any observed bacteria on CSF Gram stain provides an excellent preliminary identification of the pathogen (whereas cultures take time to grow).

***Streptococcus pneumoniae* is the most common cause of bacterial meningitis in adults of all ages** (see reference). On CSF Gram stain, lancet-shaped Gram-positive cocci are found in pairs. *S pneumoniae* meningitis often follows a pulmonary infection or mild upper respiratory infection. Alcoholics, sickle cell anemia patients, asplenic individuals, and those in generally poor health are at greater risk for *S pneumoniae* meningitis.

(Choice A) Bean-shaped Gram-negative cocci in pairs indicate *Neisseria meningitidis*. *N meningitidis* is the second most common cause of meningitis in patients < 60 years of age. *N meningitidis* tends to occur in outbreaks where many individuals live in close quarters (eg, army barracks and college dormitories).

(Choice C) Gram-positive cocci in clusters indicate *Staphylococcus* species. *Staphylococcus* is an unusual cause of community-acquired meningitis but is common in neurosurgical patients. It is thought that bacteria gain access to the meninges by direct inoculation during the procedure or postoperatively through the wound.

(Choice D) *Haemophilus influenzae* is a Gram-negative coccobacillus. *H influenzae* infection is becoming less common now that vaccination with the Hib capsule vaccine, a protein-capsule polysaccharide conjugate vaccine, has become widespread.

(Choice E) *Listeria monocytogenes* is a facultatively intracellular, motile, Gram-positive rod. It is the third most common cause of meningitis in neonates, after group B *Streptococci* and *Escherichia coli*. *Listeria* also causes meningitis in immunosuppressed patients and the elderly.

Educational objective:
Bacterial meningitis causes an increase in cerebrospinal fluid (CSF) neutrophil count and protein concentration as well as a decrease in CSF glucose. *Streptococcus pneumoniae* is a leading cause of community-acquired pneumonia, otitis media, and meningitis in adults. *S pneumoniae* appears on Gram stain as lancet-shaped, Gram-positive cocci in pairs.

Explanation

Exhibit Display

Common causes of bacterial meningitis

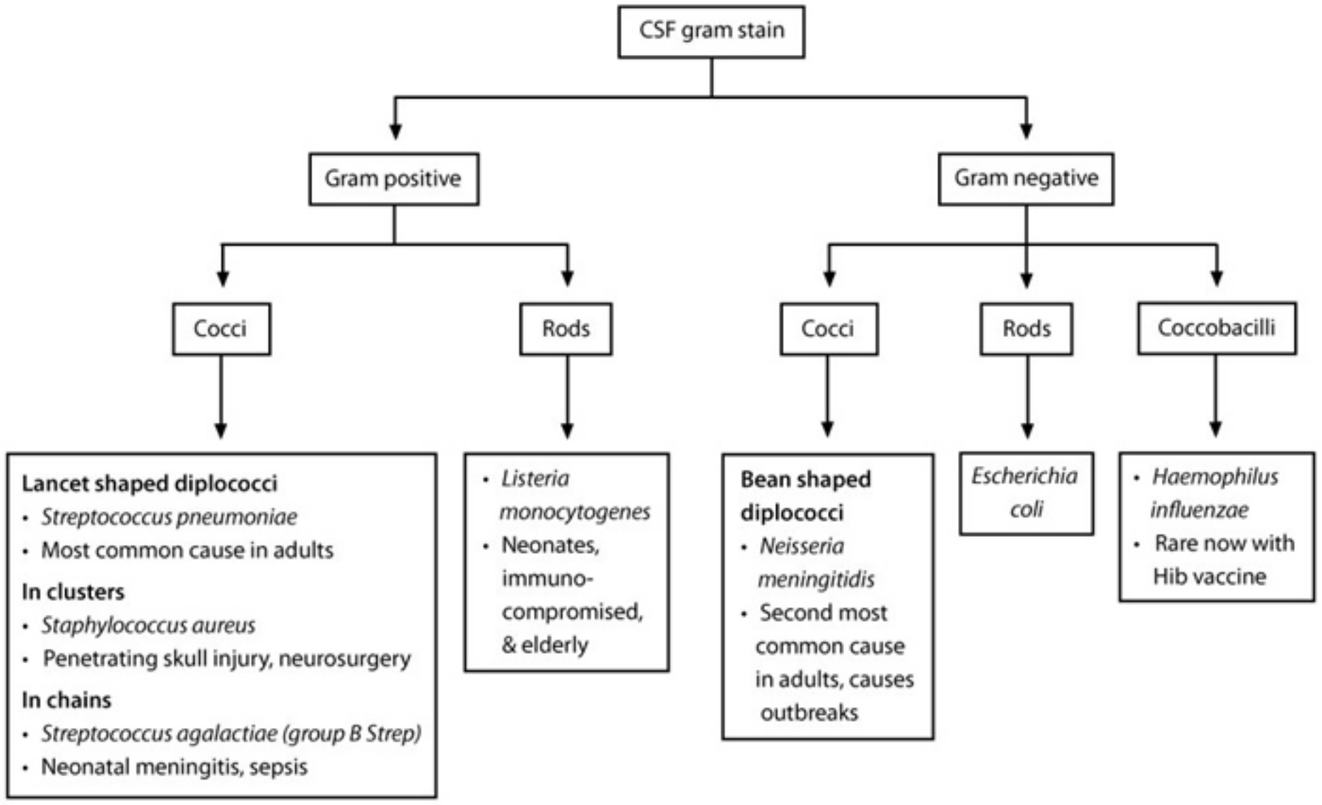

© USMLEWorld, LLC

Zoom In | Zoom Out | Reset | Add To New Card | Existing Card

lancet-shaped Gram-positive cocci are found in pairs. *S pneumoniae* meningitis often follows a pulmonary infection or mild upper respiratory infection. Alcoholics, sickle cell anemia patients, asplenic individuals, and those in generally poor health are at greater risk for *S pneumoniae* meningitis.

(Choice A) Bean-shaped Gram-negative cocci in pairs indicate *Neisseria meningitidis*. *N meningitidis* is the second most common cause of meningitis in patients < 60 years of age. *N meningitidis* tends to occur in outbreaks where many individuals live in close quarters (eg, army barracks and college dormitories).

(Choice C) Gram-positive cocci in clusters indicate *Staphylococcus* species. *Staphylococcus* is an unusual cause of community-acquired meningitis but is common in neurosurgical patients. It is thought that bacteria gain access to the meninges by direct inoculation during the procedure or postoperatively through the wound.

(Choice D) *Haemophilus influenzae* is a Gram-negative coccobacillus. *H influenzae* infection is becoming less common now that vaccination with the Hib capsule vaccine, a protein-capsule polysaccharide conjugate vaccine, has become widespread.

(Choice E) *Listeria monocytogenes* is a facultatively intracellular, motile, Gram-positive rod. It is the third most common cause of meningitis in neonates, after group B *Streptococci* and *Escherichia coli*. *Listeria* also causes meningitis in immunosuppressed patients and the elderly.

Educational objective:

Bacterial meningitis causes an increase in cerebrospinal fluid (CSF) neutrophil count and protein concentration as well as a decrease in CSF glucose. *Streptococcus pneumoniae* is a leading cause of community-acquired pneumonia, otitis media, and meningitis in adults. *S pneumoniae* appears on Gram stain as lancet-shaped, Gram-positive cocci in pairs.

References

- Bacterial meningitis in the United States, 1998-2007.

Microbiology	Nervous System	Meningitis
Subject	System	Topic

Copyright © UWorld. All rights reserved.

A 21-year-old man is brought to the emergency department by his roommate due to worsening fever, headache, and confusion. The patient recently moved to a dormitory, and his prior medical problems and immunizations are unknown. Temperature is 39.2 C (102.6 F), blood pressure is 98/54 mm Hg, pulse is 112/min, and respirations are 24/min. The patient appears acutely ill. He is obtunded and has nuchal rigidity. Leukocyte count is 19,000/mm^3 with 20% band neutrophils. Blood cultures are obtained and lumbar puncture is performed. Gram stain of cerebrospinal fluid reveals gram-negative cocci in pairs. Which of the following is the most likely way that this organism reached the meninges?

- A. Middle ear → contiguous tissues → meninges
- B. Pharynx → blood → choroid plexus → meninges
- C. Pharynx → lymphatic system → meninges
- D. Primary lung focus → blood → meninges
- E. Traumatic wound → leaking cerebral spinal fluid → meninges

Submit

A 21-year-old man is brought to the emergency department by his roommate due to worsening fever, headache, and confusion. The patient recently moved to a dormitory, and his prior medical problems and immunizations are unknown. Temperature is 39.2 C (102.6 F), blood pressure is 98/54 mm Hg, pulse is 112/min, and respirations are 24/min. The patient appears acutely ill. He is obtunded and has nuchal rigidity. Leukocyte count is 19,000/mm^3 with 20% band neutrophils. Blood cultures are obtained and lumbar puncture is performed. Gram stain of cerebrospinal fluid reveals gram-negative cocci in pairs. Which of the following is the most likely way that this organism reached the meninges?

- A. Middle ear → contiguous tissues → meninges (3%)
- ✓ B. Pharynx → blood → choroid plexus → meninges (76%)
- C. Pharynx → lymphatic system → meninges (12%)
- D. Primary lung focus → blood → meninges (6%)
- E. Traumatic wound → leaking cerebral spinal fluid → meninges (0%)

Omitted
Correct answer
B

76%
Answered correctly

02 secs
Time Spent

04/18/2020
Last Updated

Explanation

Pathogenesis of *Neisseria meningitidis*

1. **Nasopharyngeal colonization**

Pathogenesis of *Neisseria meningitidis*

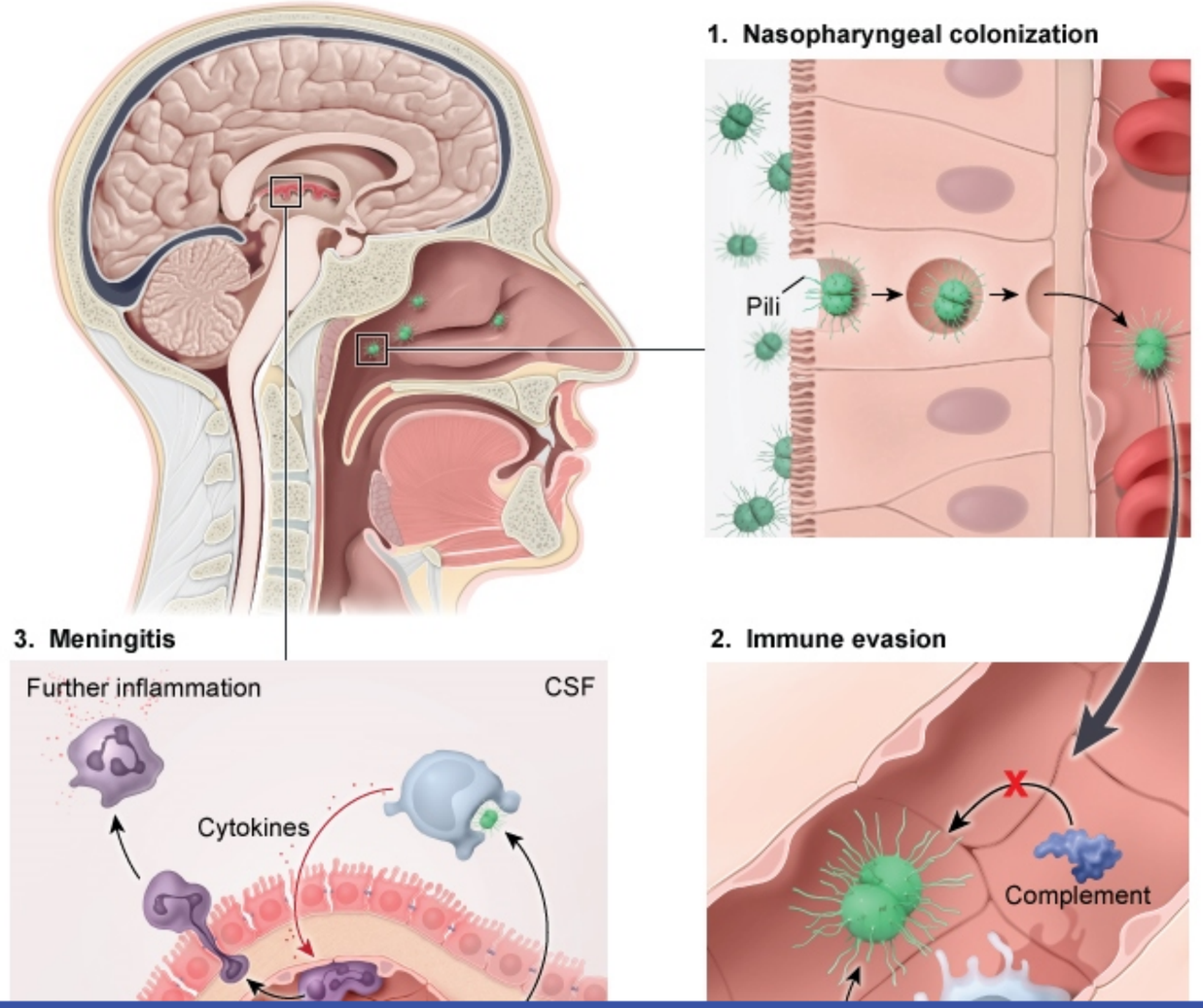

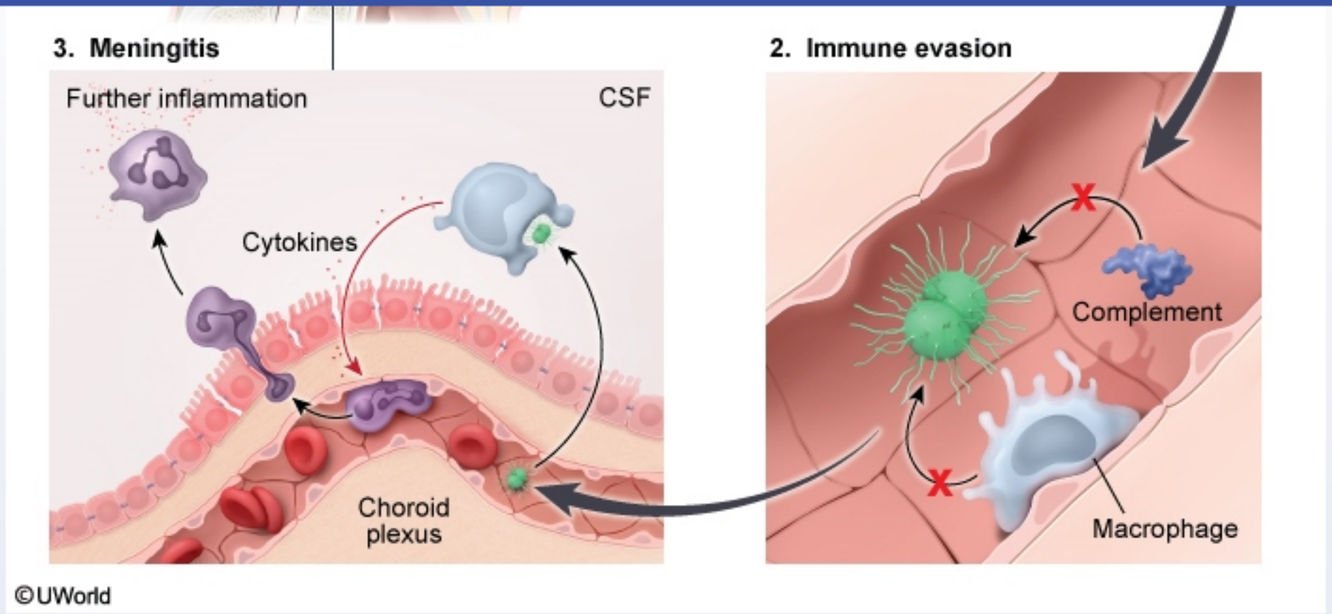

Acute bacterial meningitis is a life-threatening infection that classically presents with the triad of fever, nuchal rigidity, and altered mental state. Most cases are caused by *Streptococcus pneumoniae* (gram-positive coccus) and ***Neisseria meningitidis*** (gram-negative diplococcus). These pathogens are transmitted via aerosolized droplets and are able to **colonize the nasopharynx** due to the presence of specialized surface components (eg, fimbriae, pili). Colonization usually leads to an asymptomatic carrier state, but in a minority of patients (~0.2%), the bacteria penetrate the epithelium and enter the **bloodstream**. Intravascular survival is dependent on capsular polysaccharides, which allow the bacteria to evade destruction by the alternative complement system. Meningitis occurs when the bacteria penetrate the cerebral capillary endothelium or the **choroid plexus**, the location of blood-CSF barrier.

(Choice A) *Haemophilus influenzae* and *S pneumoniae* can rarely spread into the meninges from a middle ear infection. However, an ear infection is very uncommon cause of meningitis.

(Choice C) Spread from the pharynx through the nasal lymphatics to the subarachnoid space may contribute to some cases of bacterial meningitis. However, this route is thought to be far less common than bloodstream invasion with subsequent hematogenous spread.

Acute bacterial meningitis is a life-threatening infection that classically presents with the triad of fever, nuchal rigidity, and altered mental state. Most cases are caused by *Streptococcus pneumoniae* (gram-positive coccus) and ***Neisseria meningitidis*** (gram-negative diplococcus). These pathogens are transmitted via aerosolized droplets and are able to **colonize the nasopharynx** due to the presence of specialized surface components (eg, fimbriae, pili). Colonization usually leads to an asymptomatic carrier state, but in a minority of patients (~0.2%), the bacteria penetrate the epithelium and enter the **bloodstream**. Intravascular survival is dependent on capsular polysaccharides, which allow the bacteria to evade destruction by the alternative complement system. Meningitis occurs when the bacteria penetrate the cerebral capillary endothelium or the **choroid plexus**, the location of blood-CSF barrier.

(Choice A) *Haemophilus influenzae* and *S pneumoniae* can rarely spread into the meninges from a middle ear infection. However, an ear infection is very uncommon cause of meningitis.

(Choice C) Spread from the pharynx through the nasal lymphatics to the subarachnoid space may contribute to some cases of bacterial meningitis. However, this route is thought to be far less common than bloodstream invasion with subsequent hematogenous spread.

(Choice D) Infections of the lung (eg, *Mycobacterium tuberculosis*, *S pneumoniae*) can lead to bacteremia and meningitis. However, *N meningitidis* does not usually colonize or infect the lung.

(Choice E) Traumatic brain injury can lead to CSF leaks, with subsequent infection of the central nervous system. This is particularly common in the setting of basilar skull fracture. *S pneumoniae* (gram-positive cocci in pairs) is the most common organism.

Educational objective:
Neisseria meningitidis is transmitted primarily by aerosolized droplets and subsequently colonizes the nasopharyngeal epithelium. Penetration of the epithelium can lead to bloodstream infection. Spread to the meninges occurs via transcellular penetration of the cerebral capillary endothelium or entry at the choroid plexus.

Microbiology	Nervous System	Meningitis
Subject	System	Topic

Copyright © UWorld. All rights reserved.

A 34-year-old man comes to the hospital due to several hours of difficulty swallowing, dry mouth, and blurred vision. The patient has a history of major depression. Examination shows mydriasis and poorly reactive pupils. Electrodiagnostic studies reveal normal nerve conduction velocity but decreased compound muscle action potential (CMAP). Rapid, repetitive nerve stimulation leads to facilitation of CMAP. Further review of this patient's medical history would most likely reveal which of the following?

- A. Consumption of home-canned food
- B. Diarrheal disease after eating undercooked poultry
- C. Episodic diplopia and ptosis
- D. Occupational exposure to insecticides
- E. Recent consumption of puffer fish
- F. Tricyclic antidepressant overdose

Submit

A 34-year-old man comes to the hospital due to several hours of difficulty swallowing, dry mouth, and blurred vision. The patient has a history of major depression. Examination shows mydriasis and poorly reactive pupils. Electrodiagnostic studies reveal normal nerve conduction velocity but decreased compound muscle action potential (CMAP). Rapid, repetitive nerve stimulation leads to facilitation of CMAP. Further review of this patient's medical history would most likely reveal which of the following?

- ✓ A. Consumption of home-canned food (33%)
- B. Diarrheal disease after eating undercooked poultry (2%)
- C. Episodic diplopia and ptosis (6%)
- D. Occupational exposure to insecticides (11%)
- E. Recent consumption of puffer fish (8%)
- F. Tricyclic antidepressant overdose (37%)

Omitted
Correct answer
A

33%
Answered correctly

02 secs
Time Spent

04/15/2020
Last Updated

Explanation

The combination of **nicotinic** (eg, diplopia, dysphagia) and **muscarinic blockade** (eg, dry mouth) is strongly suggestive of food poisoning with ***Clostridium botulinum* toxin**, a highly potent preformed neurotoxin. The toxin **inhibits acetylcholine release** from presynaptic nerve terminals at the neuromuscular junction (NMJ), thereby preventing muscular contraction. This effect can be seen on electromyography as a decrease in the compound muscle action potential (CMAP, or electrical response of the muscle) following stimulation of a motor nerve. High-rate, repetitive nerve

The combination of **nicotinic** (eg, diplopia, dysphagia) and **muscarinic blockade** (eg, dry mouth) is strongly suggestive of food poisoning with ***Clostridium botulinum* toxin**, a highly potent preformed neurotoxin. The toxin **inhibits acetylcholine release** from presynaptic nerve terminals at the neuromuscular junction (NMJ), thereby preventing muscular contraction. This effect can be seen on electromyography as a decrease in the compound muscle action potential (CMAP, or electrical response of the muscle) following stimulation of a motor nerve. High-rate, repetitive nerve stimulation improves the deficit as the rapid depolarization rate increases calcium concentration in the presynaptic nerve terminal, helping mobilize additional acetylcholine vesicles.

The anaerobic environment within **canned foods** contaminated by *C botulinum* spores allows for germination and growth of the organism. The toxin (produced by vegetative bacteria) is **not** actively secreted, remaining intracellular until autolysis causes its release into food. The toxin is readily destroyed by heat; however, if food containing the toxin is not cooked properly, the classic **diplopia, dysphagia, and dysphonia ("3 Ds")** can develop within 12-36 hours of consumption.

(Choice B) Guillain-Barré syndrome can develop following *Campylobacter jejuni* infection and is characterized by absent reflexes and progressive symmetric weakness, typically starting from the lower extremities (unlike botulism, which commonly causes descending paralysis starting from the cranial nerves).

(Choice C) Myasthenia gravis (autoimmune attack against postsynaptic nicotinic receptors) is characterized by episodic diplopia and ptosis. However, muscarinic symptoms (eg, dry mouth, mydriasis) are not characteristic, and CMAP does not improve with rapid, repetitive nerve stimulation. In contrast, Lambert-Eaton syndrome (autoantibodies against presynaptic voltage-gated calcium channels) can present with muscarinic symptoms and improved CMAP with rapid nerve stimulation, but the initial weakness typically involves the proximal extremities (particularly legs).

(Choice D) Poisoning due to organophosphates (acetylcholinesterase inhibitors) used in insecticides reflects depolarizing blockade (muscle weakness, fasciculations, paralysis), central nervous system effects (lethargy, seizures), and muscarinic overstimulation (miosis, bradycardia, increased lacrimation and salivation).

(Choice E) Tetrodotoxin poisoning (due to contaminated puffer fish ingestion) leads to inhibition of sodium influx into nerve cells. Manifestations include weakness, paresthesias (face, extremities), loss of reflexes, and sometimes severe hypotension. Patients commonly remain conscious, although paralyzed.

progressive symmetric weakness, typically starting from the lower extremities (unlike botulism, which commonly causes descending paralysis starting from the cranial nerves).

(Choice C) Myasthenia gravis (autoimmune attack against postsynaptic nicotinic receptors) is characterized by episodic diplopia and ptosis. However, muscarinic symptoms (eg, dry mouth, mydriasis) are not characteristic, and CMAP does not improve with rapid, repetitive nerve stimulation. In contrast, Lambert-Eaton syndrome (autoantibodies against presynaptic voltage-gated calcium channels) can present with muscarinic symptoms and improved CMAP with rapid nerve stimulation, but the initial weakness typically involves the proximal extremities (particularly legs).

(Choice D) Poisoning due to organophosphates (acetylcholinesterase inhibitors) used in insecticides reflects depolarizing blockade (muscle weakness, fasciculations, paralysis), central nervous system effects (lethargy, seizures), and muscarinic overstimulation (miosis, bradycardia, increased lacrimation and salivation).

(Choice E) Tetrodotoxin poisoning (due to contaminated puffer fish ingestion) leads to inhibition of sodium influx into nerve cells. Manifestations include weakness, paresthesias (face, extremities), loss of reflexes, and sometimes severe hypotension. Patients commonly remain conscious, although paralyzed.

(Choice F) Anticholinergic toxicity is one of the manifestations of tricyclic antidepressant overdose. However, this produces muscarinic (not nicotinic) blockade with no effect on the NMJ (ie, no alterations in CMAP).

Educational objective:
Botulinum neurotoxin produced by *Clostridium botulinum* prevents the release of acetylcholine from presynaptic nerve terminals. The toxin impairs peripheral muscarinic and nicotinic neurotransmission, causing both autonomic symptoms (eg, fixed pupillary dilation, dry mouth) and skeletal muscle weakness (eg, diplopia, dysphagia, respiratory depression). Its effects at the neuromuscular junction can be seen on electromyography as a decrease in muscle response following stimulation of a motor nerve.

Microbiology	Nervous System	Botulism
Subject	System	Topic

Copyright © UWorld. All rights reserved.

A 16-year-old girl is brought to the emergency department after she became unresponsive. Temperature is 39.7 C (103.5 F), blood pressure is 70/40 mm Hg, and pulse is 130/min and thready. There is a diffuse petechial and ecchymotic skin rash. Laboratory testing reveals leukocytosis with left shift and evidence of disseminated intravascular coagulation and multiorgan failure. Despite aggressive interventions, the patient dies several hours after admission. Autopsy reveals hemorrhagic necrosis of many internal organs, including the bilateral adrenal glands. Which of the following microbial components is directly responsible for the severity of disease in this patient?

A. Capsular polysaccharide

B. Immunoglobulin protease

C. Lipo-oligosaccharide

D. Lipoteichoic acid

E. Superantigen exotoxin

Submit

A 16-year-old girl is brought to the emergency department after she became unresponsive. Temperature is 39.7 C (103.5 F), blood pressure is 70/40 mm Hg, and pulse is 130/min and thready. There is a diffuse petechial and ecchymotic skin rash. Laboratory testing reveals leukocytosis with left shift and evidence of disseminated intravascular coagulation and multiorgan failure. Despite aggressive interventions, the patient dies several hours after admission. Autopsy reveals hemorrhagic necrosis of many internal organs, including the bilateral adrenal glands. Which of the following microbial components is directly responsible for the severity of disease in this patient?

- A. Capsular polysaccharide (26%)
- B. Immunoglobulin protease (2%)
- ✓ C. Lipo-oligosaccharide (47%)
- D. Lipoteichoic acid (4%)
- E. Superantigen exotoxin (18%)

Omitted
Correct answer
C

47%
Answered correctly

03 secs
Time Spent

02/14/2020
Last Updated

Explanation

Neisseria meningitidis is a common cause of rapid-onset sepsis and circulatory collapse in otherwise healthy young individuals. Infections usually start suddenly with myalgias, high fever, headache, and altered level of consciousness and quickly progress to hypotension, organ failure, and death. Many patients also develop a **petechial/ecchymotic rash** due to underlying disseminated intravascular coagulation.

N meningitidis has an outer cell membrane virulence factor called **lipo-oligosaccharide** (LOS), which is primarily responsible for the severity of

Neisseria meningitidis is a common cause of rapid-onset sepsis and circulatory collapse in otherwise healthy young individuals. Infections usually start suddenly with myalgias, high fever, headache, and altered level of consciousness and quickly progress to hypotension, organ failure, and death. Many patients also develop a **petechial/ecchymotic rash** due to underlying disseminated intravascular coagulation.

N meningitidis has an outer cell membrane virulence factor called **lipo-oligosaccharide** (LOS), which is primarily responsible for the severity of meningococcal disease. LOS, and its close analogue lipopolysaccharide (found in gram-negative enteric rods), are **endotoxins** that cause toxicity when released into the plasma via shedding of the outer membrane ("blebbing") or bacterial lysis. Endotoxins bind to Toll-like receptor 4 on monocytic and dendritic cells and trigger the release of inflammatory cytokines (eg, IL-1, IL-6, TNF-alpha), which leads to endothelial damage, capillary leakage, and hemorrhagic necrosis.

(Choices A and B) The capsular polysaccharide of *N meningitidis* is an important virulence factor that helps the bacteria resist phagocytosis and complement activation. *N meningitidis* also releases IgA protease, which aids in nasopharyngeal epithelial colonization. However, these virulence factors are not the direct cause of meningococcal septic shock.

(Choice D) Lipoteichoic acid is a major component of the cell wall of most gram-positive bacteria and acts as a regulator of autolytic cell wall enzymes. Although lipoteichoic acid can stimulate the complement cascade, it is not a major cause of septic shock and hemorrhagic inflammation in patients with meningococcemia (a gram-negative organism).

(Choice E) Toxic shock syndrome is due to *Staphylococcus aureus* exotoxins, which act as superantigens and result in the wide-spread activation of T-cells (with massive inflammatory cytokine release). Patients usually present with circulatory collapse, organ failure, and erythroderma (a diffuse macular rash that looks like a sunburn). Petechiae and ecchymosis would be atypical.

Educational objective:
Neisseria meningitidis can cause sepsis and circulatory collapse in previously healthy young individuals. Lipooligosaccharide, a virulence factor in the pathogens outer membrane, is the major underlying cause of disease severity.

References

- Neisseria meningitidis: biology, microbiology, and epidemiology.

Microbiology Nervous System Meningitis

N meningitidis has an outer cell membrane virulence factor called **lipo-oligosaccharide** (LOS), which is primarily responsible for the severity of meningococcal disease. LOS, and its close analogue lipopolysaccharide (found in gram-negative enteric rods), are **endotoxins** that cause toxicity when released into the plasma via shedding of the outer membrane ("blebbing") or bacterial lysis. Endotoxins bind to Toll-like receptor 4 on monocytic and dendritic cells and trigger the release of inflammatory cytokines (eg, IL-1, IL-6, TNF-alpha), which leads to endothelial damage, capillary leakage, and hemorrhagic necrosis.

(Choices A and B) The capsular polysaccharide of *N meningitidis* is an important virulence factor that helps the bacteria resist phagocytosis and complement activation. *N meningitidis* also releases IgA protease, which aids in nasopharyngeal epithelial colonization. However, these virulence factors are not the direct cause of meningococcal septic shock.

(Choice D) Lipoteichoic acid is a major component of the cell wall of most gram-positive bacteria and acts as a regulator of autolytic cell wall enzymes. Although lipoteichoic acid can stimulate the complement cascade, it is not a major cause of septic shock and hemorrhagic inflammation in patients with meningococcemia (a gram-negative organism).

(Choice E) Toxic shock syndrome is due to *Staphylococcus aureus* exotoxins, which act as superantigens and result in the wide-spread activation of T-cells (with massive inflammatory cytokine release). Patients usually present with circulatory collapse, organ failure, and erythroderma (a diffuse macular rash that looks like a sunburn). Petechiae and ecchymosis would be atypical.

Educational objective:
Neisseria meningitidis can cause sepsis and circulatory collapse in previously healthy young individuals. Lipooligosaccharide, a virulence factor in the pathogens outer membrane, is the major underlying cause of disease severity.

References

- Neisseria meningitidis: biology, microbiology, and epidemiology.

Microbiology	Nervous System	Meningitis
Subject	System	Topic

Copyright © UWorld. All rights reserved.

A pharmaceutical researcher is developing a novel agent to prevent meningococcal disease in people exposed to the bacteria. Pili antigens from *Neisseria meningitidis* are extracted and used to generate monoclonal antibodies that impair normal pili function. The antibodies are administered to experimental animals with no prior exposure to *N meningitidis*. These animals, along with control animals that had not received the antibodies, are subsequently exposed to the bacteria. Compared to the control animals, a significantly greater proportion of the animals that received the antibodies remain healthy and develop no symptoms. The efficacy of these antibodies in preventing meningococcal disease is most likely due to direct interference with which of the following microbial processes?

A. Adhesion to vascular endothelial cells

B. Attachment to nasopharyngeal epithelial cells

C. Hematogenous dissemination

D. Invasion of the meninges

E. Survival inside phagocytes

Submit

A pharmaceutical researcher is developing a novel agent to prevent meningococcal disease in people exposed to the bacteria. Pili antigens from *Neisseria meningitidis* are extracted and used to generate monoclonal antibodies that impair normal pili function. The antibodies are administered to experimental animals with no prior exposure to *N meningitidis*. These animals, along with control animals that had not received the antibodies, are subsequently exposed to the bacteria. Compared to the control animals, a significantly greater proportion of the animals that received the antibodies remain healthy and develop no symptoms. The efficacy of these antibodies in preventing meningococcal disease is most likely due to direct interference with which of the following microbial processes?

- A. Adhesion to vascular endothelial cells (20%)
- ✓ B. Attachment to nasopharyngeal epithelial cells (64%)
- C. Hematogenous dissemination (4%)
- D. Invasion of the meninges (6%)
- E. Survival inside phagocytes (3%)

Omitted
Correct answer
B

64%
Answered correctly

01 sec
Time Spent

03/28/2020
Last Updated

Explanation

Neisseria meningitidis is commonly isolated from the oropharynx and nasopharynx of asymptomatic carriers. Colonization rates are variable but highest in close contact populations (eg, military recruits, university students). Transmission of meningococci usually occurs through exposure to respiratory droplets or direct contact with respiratory secretions. The **pili** on the capsular surface of *N meningitidis* are primarily responsible for attachment to and **colonization of the nasopharyngeal epithelium**. Pili also play a role in bacterial movement and epithelial penetration during

Neisseria meningitidis is commonly isolated from the oropharynx and nasopharynx of asymptomatic carriers. Colonization rates are variable but highest in close contact populations (eg, military recruits, university students). Transmission of meningococci usually occurs through exposure to respiratory droplets or direct contact with respiratory secretions. The **pili** on the capsular surface of *N meningitidis* are primarily responsible for attachment to and **colonization of the nasopharyngeal epithelium**. Pili also play a role in bacterial movement and epithelial penetration during invasion.

Pili undergo high rates of **antigenic variation** (due to on-off gene switching and horizontal gene transfer), which limits the effectiveness of vaccines against this target. Other prominent *N meningitidis* virulence factors include IgA protease (destroys mucosal antibodies that would otherwise inhibit epithelial colonization), capsular polysaccharides (prevent phagocytosis and phagolysosome destruction), lipo-oligosaccharide (an endotoxin that is the major source of toxicity), and Opa-proteins (aid in endothelial attachment and invasion).

(Choices A and D) *N meningitidis* penetration into the central nervous system is thought to occur at the cerebral capillary endothelial surface and, potentially, at the choroid plexus (the site of the blood–cerebrospinal fluid barrier). Vaccines that target endothelial or meningeal invasion would act too late in the disease process to prevent significant illness; once *N meningitidis* enters the circulatory system, increased levels of endotoxin put patients at high risk for sepsis, circulatory collapse, and death.

(Choices C and E) Most existing meningococcal vaccines target capsular polysaccharides. Capsular polysaccharides prevent phagocytosis and allow the pathogen to replicate and disseminate within the bloodstream. They also promote bacterial survival within phagocytes by inhibiting phagolysosome destruction.

Educational objective:
Pili are the primary virulence factor that allow *Neisseria meningitidis* to initially attach to and colonize the nasopharyngeal epithelial surface. Pili undergo significant antigenic variation, which makes them a difficult vaccination target.

References

- Neisseria meningitidis: biology, microbiology, and epidemiology.

Microbiology	Nervous System	Meningitis
Subject	System	Topic

highest in close contact populations (eg, military recruits, university students). Transmission of meningococci usually occurs through exposure to respiratory droplets or direct contact with respiratory secretions. The **pili** on the capsular surface of *N meningitidis* are primarily responsible for attachment to and **colonization of the nasopharyngeal epithelium**. Pili also play a role in bacterial movement and epithelial penetration during invasion.

Pili undergo high rates of **antigenic variation** (due to on-off gene switching and horizontal gene transfer), which limits the effectiveness of vaccines against this target. Other prominent *N meningitidis* virulence factors include IgA protease (destroys mucosal antibodies that would otherwise inhibit epithelial colonization), capsular polysaccharides (prevent phagocytosis and phagolysosome destruction), lipo-oligosaccharide (an endotoxin that is the major source of toxicity), and Opa-proteins (aid in endothelial attachment and invasion).

(Choices A and D) *N meningitidis* penetration into the central nervous system is thought to occur at the cerebral capillary endothelial surface and, potentially, at the choroid plexus (the site of the blood–cerebrospinal fluid barrier). Vaccines that target endothelial or meningeal invasion would act too late in the disease process to prevent significant illness; once *N meningitidis* enters the circulatory system, increased levels of endotoxin put patients at high risk for sepsis, circulatory collapse, and death.

(Choices C and E) Most existing meningococcal vaccines target capsular polysaccharides. Capsular polysaccharides prevent phagocytosis and allow the pathogen to replicate and disseminate within the bloodstream. They also promote bacterial survival within phagocytes by inhibiting phagolysosome destruction.

Educational objective:
Pili are the primary virulence factor that allow *Neisseria meningitidis* to initially attach to and colonize the nasopharyngeal epithelial surface. Pili undergo significant antigenic variation, which makes them a difficult vaccination target.

References

- Neisseria meningitidis: biology, microbiology, and epidemiology.

Microbiology	Nervous System	Meningitis
Subject	System	Topic

Copyright © UWorld. All rights reserved.